

Optimizing PAD Treatment With the Phoenix Atherectomy System

A look at the next generation of peripheral atherectomy, including case reports courtesy of Prof. Thomas Zeller, MD.

BY STEPHEN B. WILLIAMS, MD, MPH

More than 19 million Americans now suffer from peripheral artery disease (PAD),^{1,2} and, correspondingly, the economic cost of this disease is becoming increasingly overwhelming. It is now estimated that the annual economic burden from PAD is between \$160 and \$290 billion.^{3,4}

Multiple studies have reported data suggesting that endovascular treatment of PAD is comparable or even superior to surgical bypass in terms of cost, safety, durability, and patient satisfaction, and physicians can now choose from an ever-expanding selection of technologies when treating these patients.^{5,6} These technologies range from traditional gold standards, such as angioplasty balloons and nitinol stents, to newer devices, including atherectomy catheters and drug-delivery tools.⁷

For physicians concerned about the potential for flow-limiting dissections with balloon angioplasty or hesitant to leave a permanent stent implanted, atherectomy has long been a top choice.⁸ The recent release of data from DEFINITIVE-LE and other trials has provided additional support for atherectomy as a first-line therapy.^{9,10}

Volcano Corporation recently introduced the Phoenix Atherectomy System as another commercially available atherectomy solution. I had firsthand experience with the catheter during the EASE (Endovascular Atherectomy Safety and Effectiveness) pivotal trial, which demonstrated the safety and effectiveness of the Phoenix System. During that initial experience, this device proved to offer several key advantages, which are outlined below, over other currently available atherectomy systems.

DEVICE OVERVIEW

The Phoenix is an over-the-wire device with a rotating front-cutting element located on the distal tip of the catheter (Figure 1). After using a diagnostic angiogram to visually assess the desired treatment area, the Phoenix catheter is advanced over a 0.014-inch guidewire to the diseased vessel segment. The system is compatible with a variety of commercially available guidewires that are suitable for atherectomy.



Figure 1. The Phoenix Atherectomy System catheter traveling over the guidewire with front-cutting element located on the distal tip of the catheter.

Once the device is positioned proximally to the lesion, an on-off switch located on the device's handle activates the rotation of the Phoenix's distal cutting element. Other atherectomy devices may require capital equipment or tableside accessories, whereas the Phoenix Atherectomy System does not require these items, which simplifies its set up and use (Figure 2). The front-cutting design obviates the need for predilatation before catheter delivery.

As the distal tip of the system rotates at 10,000 to 12,000 rpm, the design of its cutting blades (Figure 3) shaves material directly into the catheter where it is captured and continuously removed by an internal Archimedes screw into an external collection bag. This continuous debris removal makes the Phoenix a single-insertion device that does not need to be removed during the procedure to purge collected material. Furthermore, this debris clearance is a completely passive, mechanical conveyance, which eliminates complications (eg, excessive blood removal or vessel suck-down) previously seen with devices that actively aspirate.

By capturing and removing the debulked material, the Phoenix's mechanism of action is designed to minimize the chance of distal embolization, one of the primary historic concerns with atherectomy. In the EASE study, symptomatic distal embolization requiring intervention

Sponsored by Volcano Corporation

Catheter Size (mm)	Introducer Size (F)	Working Length (cm)	Guidewire Diameter (inches)
1.8 tracking	5	130	0.014
2.2 tracking	6	130	0.014
2.4 deflecting tip	7	130	0.014

Indication for Use: *The Phoenix Atherectomy System is intended for use in atherectomy of the peripheral vasculature. The system is not intended for use in the coronary, carotid, iliac, or renal vasculature.*




Figure 2. The Phoenix Atherectomy System, shown with the catheter inserted into the handle drive unit. No external, off-table components are required.

was reported in 0.8% (1/123) of lesions treated with the Phoenix. Additionally, embolic protection devices were not used to treat any of the target lesions during the EASE study. In other studies, Covidien reported a 1.6% intervention rate due to distal embolization with its SilverHawk or TurboHawk devices in DEFINITIVE-LE,⁹ with 22% of cases using an embolic protection device. In the DEFINITIVE-Ca++ trial, the same catheters showed a 2.3% intervention rate due to distal embolization even when filters were used on 97.2% of patients.¹¹

For treating disease located below the knee, the Phoenix is available in 1.8- and 2.2-mm diameters. The 5-F profile of the 1.8-mm catheter, when combined with its front-cutting ability, is designed to enhance the device's ability to debulk the small, highly stenosed vessels that are often seen below the knee. This 5-F device is also extremely trackable, which has allowed treatment into the plantar arch when these vessels are sized appropriately.

For larger vessels located above the knee, the 2.4-mm Phoenix catheter incorporates a deflecting tip that can debulk to larger diameters. By combining a front-cutting, rotational technology with directional capabilities, the Phoenix becomes an extremely versatile treatment option.¹²

CONCLUSION

Each patient with PAD presents with his or her own set of unique characteristics and challenges. In order to tailor treatment to each individual patient, it is important for peripheral interventionists to understand all of the treatment options available to them.

With the recent introduction of the Phoenix Atherectomy System, a new tool is now available that offers an intriguing



Figure 3. Magnified view of the front-cutting blade located on the distal tip of the Phoenix Atherectomy System.

combination of features for the treatment of PAD, particularly for vessels below the knee. With its front-cutting design, cut-capture-and-clear mechanism of action, and profile down to 5 F, the Phoenix has the potential to treat a broad range of vessel diameters and lesion types while also minimizing the chance of distal embolization.

Moving forward, it is important to study the Phoenix System more closely in a real-world setting to understand its place in this evolving market segment.

Stephen B. Williams, MD, MPH, is Director of the Vascular Medicine Center within the Division of Cardiology at Johns Hopkins University in Baltimore, Maryland. Dr. Williams has received no financial compensation for participation in this article. He has disclosed that he is a consultant to Volcano Corporation. Dr. Williams may be reached at sbwilliams@jhmi.edu.

1. Yost ML. Critical limb ischemia. United States epidemiology. Prevalence, market opportunities and analysis of the two most common comorbidities: diabetes and chronic kidney disease. Atlanta (GA): The Sage Group; 2007.
2. Yost ML. Critical limb ischemia. Volume II. Western Europe. Prevalence, market opportunities and analysis of the most common comorbidity: diabetes. Atlanta (GA): The Sage Group; 2007.
3. Mahoney EM, Wang K, Cohen DJ, et al; REACH Registry Investigators. One-year costs in patients with a history of or at risk for atherothrombosis in the United States. *Circ Cardiovasc Qual Outcomes*. 2008;1:38-45.
4. Margolis J, Barron JJ, Grochulski WD. Health care resources and costs for treating peripheral artery disease in a managed care population: results from analysis of administrative claims data. *J Manag Care Pharm*. 2005;11:727-734.
5. Jones WS, Dolor RJ, Hasselblad V, et al. Comparative effectiveness of endovascular and surgical revascularization for patients with peripheral artery disease and critical limb ischemia: systematic review of revascularization in critical limb ischemia. *Am Heart J*. 2014;167:489-498.e7.
6. Moriarty JP, Murad MH, Shah ND, et al. Society for Vascular Surgery Committee on Comparative Effectiveness. A systematic review of lower extremity arterial revascularization economic analyses. *J Vasc Surg*. 2011;54:1131-1144.
7. Mahmod E, Cavendish JJ, Salami A. Current treatment of peripheral arterial disease: a role of percutaneous interventional therapies. *J Am Coll Cardiol*. 2007;50:473-490.
8. Franzone A, Ferrone M, Carotenuto G, et al. The role of atherectomy in the treatment of lower extremity peripheral artery disease. *BMC Surg*. 2012;12 (suppl 1):S13.
9. McKinsey JF, Zeller T, Rocha-Singh KJ, et al. Lower extremity revascularization using directional atherectomy: 12-month prospective results of the DEFINITIVE LE study. *JACC Cardiovasc Interv*. 2014;7:923-933.
10. Mayeda G, Pliagas G, LeSar C, et al. Procedural outcomes of orbital atherectomy treatment of peripheral arterial disease in an outpatient office-based vs hospital setting. *Vascular Disease Management*. 2014;11:E37-E43.
11. Roberts et al. Catheterization and Cardiovascular Interventions. 2014;84:236-244.
12. Phoenix Atherectomy System Instructions for Use.

CASE 1: OCCLUDED POSTERIOR TIBIAL ARTERY

An 84-year-old man presented with a Rutherford class 5, nonhealing wound on his left great toe. Antegrade access was achieved in the left femoral artery, and a 6-F, 10-cm Avanti sheath (Cordis Corporation) was inserted. The baseline runoff angiogram showed only a patent anterior tibial artery below the knee (Figure 1A).

The posterior tibial (PT) artery was considered more important to wound healing because of its connection to the plantar arch, but it was not possible to cross the PT occlusion because the origin of the artery was jailed by a previously placed self-expanding stent.

The chronic total occlusion of the PT artery was traversed in a retrograde fashion through contralateral flow in the foot using an 0.014-inch Glidewire Advantage (Terumo

Interventional Systems), but this wire was unable to pass through the struts of the nitinol stent (Figures 1B and 1C).

An Outback LTD re-entry catheter (Cordis Corporation) was then used to gain access through the struts of the stent and to snare the guidewire from below (Figure 1D). Once guidewire access was achieved, the guidewire was exchanged for a Hi-Torque Extra S'Port wire (Abbott Vascular), which is one of the commercially available wires that is compatible with the Phoenix Atherectomy System (Volcano Corporation) (Figure 1E). A 3- X 40-mm Maverick angioplasty balloon (Boston Scientific Corporation) was then used to prop open the struts of the nitinol stent to facilitate delivery of interventional tools into the PT artery (Figure 1F).

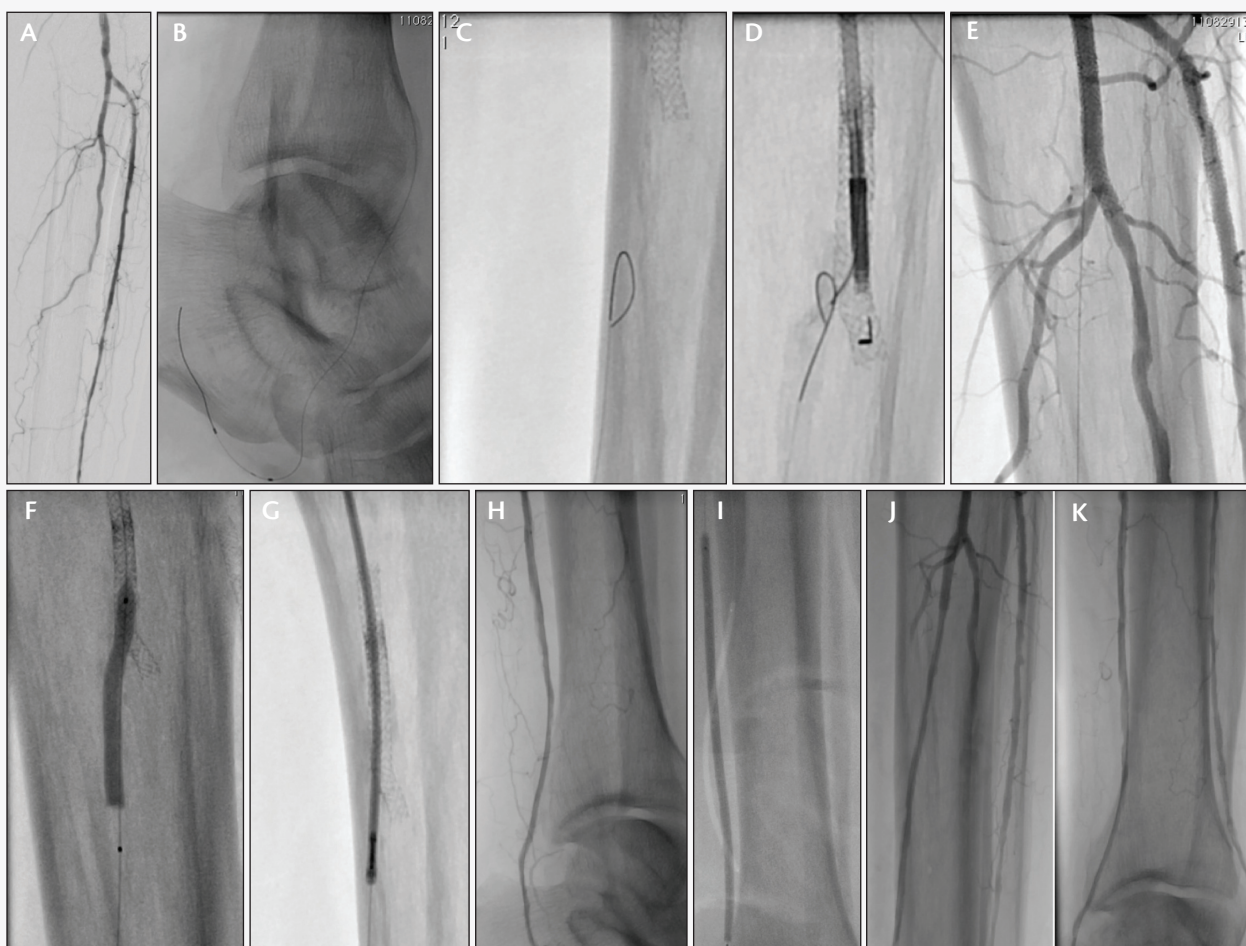


Figure 1. Initial selective angiogram below the knee, showing the occluded PT artery (A). Retrograde wiring of the anterior tibial artery through collateral flow from the PT artery (B). Retrograde wire approaching the self-expanding stent that was jailing off the ostium (C). An Outback catheter was used to position the wire through the stent struts (D). Hi-Torque Xtra S'Port guidewire in place for PT intervention (E). A 3-mm balloon was used to prop open the stent struts (F). A 1.8-mm Phoenix catheter was used to treat the full 40-cm length of anterior tibial occlusion after traveling through the stent struts. No debulking was performed within the stent (G). Distal angiogram after atherectomy was performed with the Phoenix System (H). Postdilatation was performed with a Lutonix DCB (I). Final angiograms showing restored flow in the PT artery (J and K).

Sponsored by Volcano Corporation

Atherectomy of the entire length of the 360-mm occluded segment was then performed using the 1.8-mm Phoenix Atherectomy System (Figure 1G). The system was operated for approximately 5 minutes and 30 seconds and did not have to be removed as the debulked material was continuously cleared from the patient by the device's internal Archimedes screw. After atherectomy, the vessel demonstrated brisk runoff to the foot with residual stenosis estimated to be approximately 30% (Figure 1H).

A 3- X 20-mm Promus Element stent (Boston Scientific Corporation) was placed at the ostium of the PT artery to recreate that bifurcation and ensure

that flow could pass through the existing nitinol stent. The entire length of the PT artery was then postdilated with four Lutonix drug-coated balloons (DCBs) (Bard Peripheral Vascular). The following balloon sizes were inflated for approximately 3 minutes each to maximize drug delivery: 3 X 120 mm, 3 X 80 mm, 3 X 80 mm, 2 X 80 mm (Figure 1I). After 12 minutes of DCB inflation, the formation of thrombus was blocking distal flow to the foot. A QuickCat Extraction catheter (Spectranetics) was used to remove the thrombus, and a final angiogram showed a posterior tibial artery with 0% estimated residual stenosis (Figure 1J and 1K).

CASE 2: TORTUOUS DISTAL PT ARTERY DISEASE

A 78-year-old man presented with a Rutherford class 5, nonhealing wound on his right great toe. Antegrade access was achieved in the right femoral artery, and a 6-F, 10-cm Avanti sheath was inserted. The baseline runoff angiogram showed two patent vessels located below the knee. Within the PT artery, multiple abrupt tortuous segments were observed, and, in the distal-most tortuous segment, a focal, severely calcified, 95% stenosis was present (Figure 2A).

An 0.014-inch Glidewire Advantage was used to cross the lesion before being exchanged for an 0.014-inch Nitrex guidewire (Covidien). Once the guidewire was in place, the 1.8-mm Phoenix Atherectomy System was used to debulk the 30-mm diseased segment; on the angiogram, calcium clearly outlined the vessel in the area that was debulked (Figure 2B and 2C). The system was operated for approximately 6 minutes and 15 seconds. After atherectomy, the vessel demonstrated brisk flow, and residual stenosis was estimated to be approximately 0% (Figure 2D).

Postdilatation was performed with a 3- X 40-mm Lutonix DCB to deliver the benefits of drug delivery (Figure 2E), and no dissection was seen (Figure 2F). ■

Prof. Thomas Zeller, MD, is Director of the Department of Angiology at Universitaets-Herzzentrum, Freiburg-Bad Krozingen in Bad Krozingen, Germany. His financial disclosures may be found on www.evtoday.com.

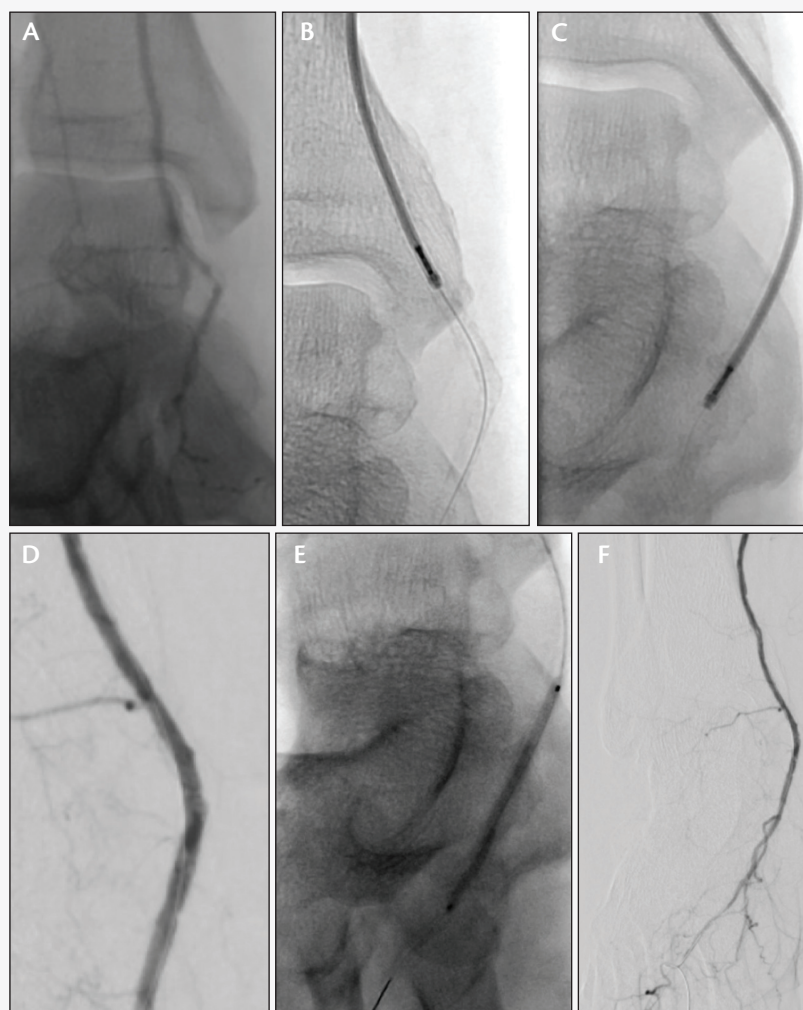


Figure 2. Initial selective angiogram at the ankle, showing a lesion in the extreme distal portion of the PT artery (A). The 1.8-mm Phoenix Atherectomy System was used to treat the calcified vessel into the heel and did not have to be removed because the debulked material was continuously cleared by the device's internal Archimedes screw (B, C). Angiogram after atherectomy was performed (D). Postdilatation was performed with a Lutonix DCB (E). Final angiogram, showing no dissection (F).