

The background of the cover is a photograph of a woman in a blue t-shirt sitting on an MRI table, talking to a female technician in white scrubs. They are in a modern MRI suite with a large circular gantry in the background. The Philips logo is visible on the gantry. The overall color palette is cool, with blues and greys.

**PHILIPS**

MRI Magazine

Publication for the Philips MRI Community **Issue 56 – 2019**

# FieldStrength

## Speed, Comfort, Confidence

**More patients** and confidence  
with Compressed SENSE

Ingenia portfolio expanded with  
**Ambition 1.5T and Elition 3.0T**

Visualizing **spinal nerve** abnormalities

**Prostate** cancer radiotherapy workflow  
with MRI only



# Dear Friends,

We know that healthcare organizations are striving to deliver on the Quadruple Aim of enhancing productivity, improving the patient and staff experience, and delivering better value-based care, boosting patient outcomes and driving down costs. To support you in addressing these challenges, we focus on providing Speed, Comfort and Confidence.

When it comes to speed, our MRI acceleration method, Compressed SENSE, is a very meaningful innovation. Read in this FieldStrength issue how KOYASU Neurosurgical Clinic used Compressed SENSE to allow scanning of three additional patients per day. Faster scanning also benefits patient comfort by reducing the time that patients need to lie still or hold their breath. This was, together with the desire for high image quality, the motivation for Kurashiki Central Hospital to implement Compressed SENSE.

For high diagnostic confidence in spinal nerve imaging, Northern Fukushima Medical Center benefits from 3D NerveVIEW. And Turku University Hospital can now rely on the high soft tissue contrast of MR images in MRI-only planning of radiation therapy for their prostate cancer patients.

Other articles in this issue focus on different ways for driving down cost while maintaining top-quality MRI: read what Mahajan Imaging saved by buying Ingenia Prodiva, and see how Hospital NS Rosario keeps its MRI systems up-to-date at predictable, overall lower cost than before by choosing Technology Maximizer.

And last but not least, don't miss the cover article on Ingenia Ambition, the latest addition to our MRI portfolio. The Ambition scanner with BlueSeal magnet operates with only seven liters of liquid helium and is fully sealed – protecting the MRI service from potential cryogen-related issues and helping to reduce siting costs.

Success in meeting the needs represented by the Quadruple Aim means a shift in perspective. Technology will continue to improve, but emphasis will shift to solutions that drive outcomes in your setting. We are determined to be your partner under our Speed, Comfort, Confidence promise.

Enjoy reading!

**Arjen Radder**  
Global Business Leader MRI, Philips

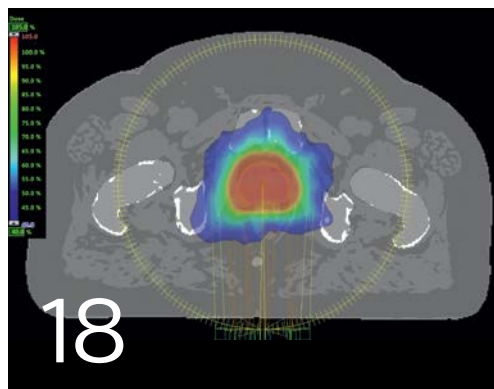
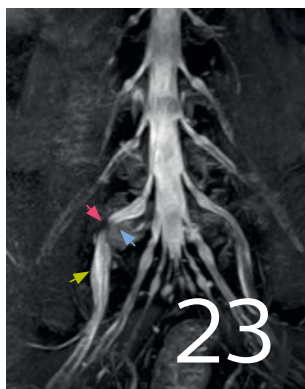
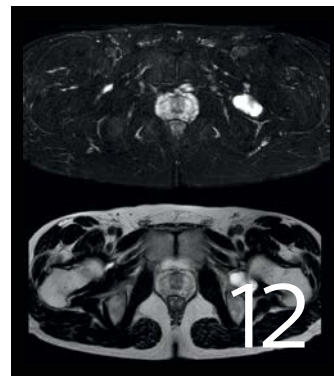
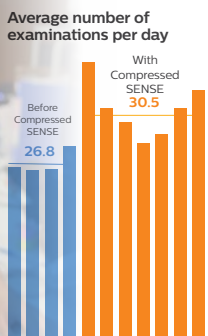


## NetForum

[www.philips.com/netforum](http://www.philips.com/netforum)

Visit the NetForum online community to download ExamCards and view application tips, case studies, online training and more. Scan the QR code with your smartphone or use [www.philips.com/netforum](http://www.philips.com/netforum).

Speed  
Comfort  
Confidence



News

**4 A new portfolio of MR solutions**  
Delivering Speed, Comfort and Confidence

Business perspective in MRI

**6 KNC can scan three more patients per day with Compressed SENSE**  
An average of 14% higher patient throughput  
*Koyasu Neurosurgical Clinic, Japan*

**30 Always up-to-date MRI systems at predictable, reduced cost**  
Keeping MRI systems updated with flat 4-year budget  
*Hospital Nuestra Señora del Rosario, Spain*

MRI with confidence

**12 High quality and fast scanning with Compressed SENSE at KCH**  
Faster MRI is welcomed by patients and staff.  
*Kurashiki Central Hospital, Japan*

**18 Using MRI only in prostate cancer radiotherapy workflow**  
Planning radiation therapy without CT for prostate cancer  
*Turku University Hospital, Finland*

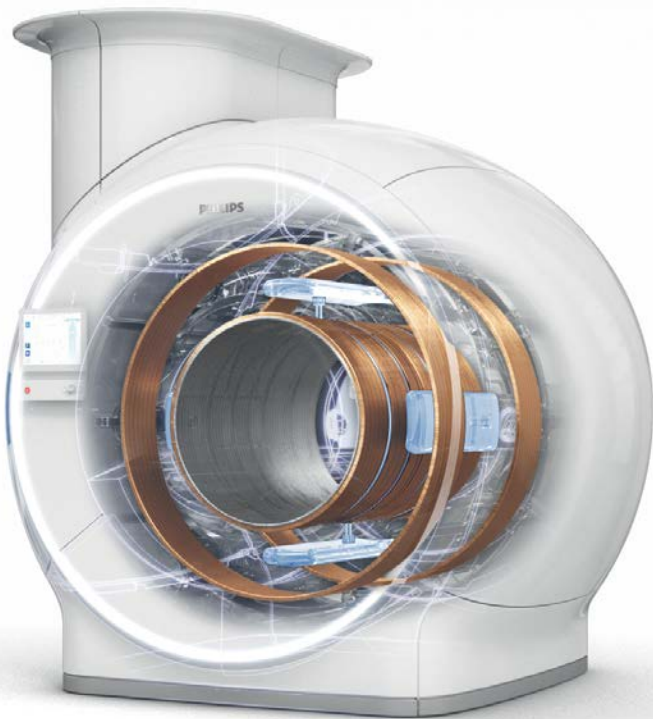**23 Direct visualization of nerves can influence surgery decisions**  
3D NerveVIEW in patients with lower extremity symptoms  
*Northern Fukushima Medical Center, Japan*

Results from case studies are not predictive of results in other cases. Results in other cases may vary. Results obtained by facilities described in this issue may not be typical for all facilities.

# A new portfolio of MR solutions delivering **Speed, Comfort and Confidence**

At Philips MR, we want to push the boundaries of healthcare and deliver seamless care while putting the patient first. We are committed to partnering with you to deliver a confident diagnosis the first time, while also helping to future-proof your radiology department.

Over the past year we have introduced three new cutting edge MRI systems. Our holistic approach to improving the MRI experience for patients has resulted in a wide range of features aiming to do just that. We have already seen many users experience significant improvements by using Compressed SENSE acceleration.

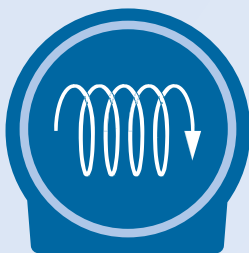


## **Ingenia Ambition 1.5T** Excel in your daily MR services, helium-free

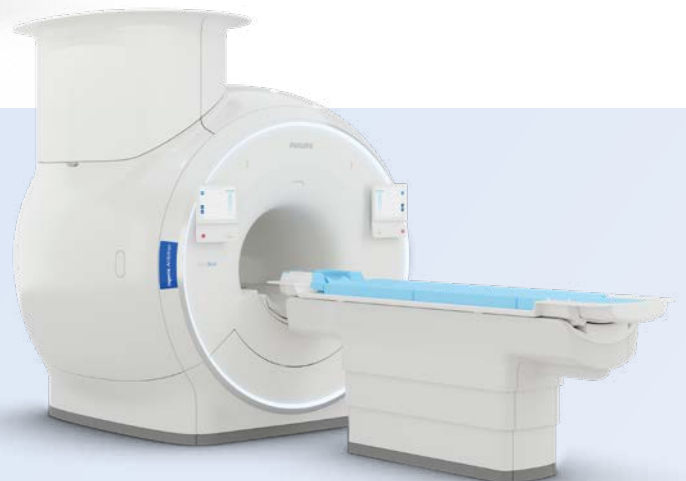Two game-changing MR innovations are combined in the new Ingenia Ambition 1.5T: the BlueSeal magnet and Compressed SENSE. The revolutionary BlueSeal magnet contains only 7 liters of liquid helium (compared to about 1500 liters in Ingenia 1.5T). The BlueSeal magnet is fully sealed, so that no helium can escape<sup>1</sup> and no vent-pipe is needed. The BlueSeal solution lets you experience more productive, helium-free MR operations<sup>2</sup>.

The Ingenia Ambition delivers superb image quality, even for challenging patients, and performs MRI exams up to 50% faster with Compressed SENSE acceleration for all anatomies in both 2D- and 3D scanning<sup>4</sup>. Patient handling at the bore is simplified with the touchless guided patient setup. Without any technologist interaction, VitalEye provides a respiratory trace that is more robust compared to traditional respiratory triggering methods<sup>3</sup>. Furthermore, an immersive audio-visual experience is available to calm patients and guide them through MR exams.

BlueSeal magnet

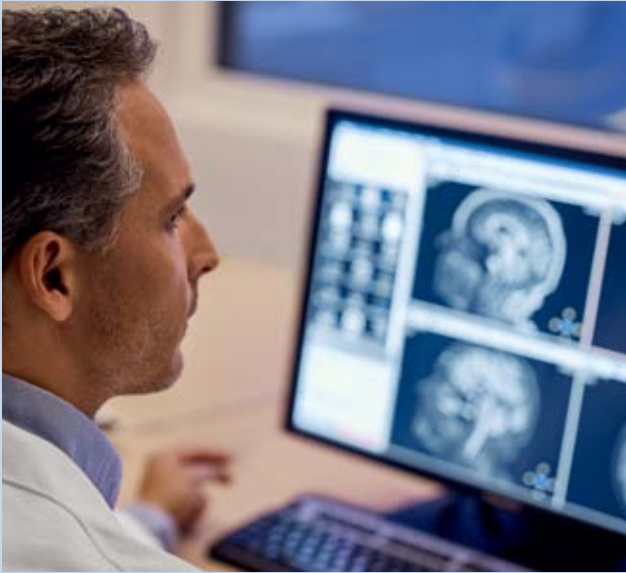

From ~1,500 liters to  
~7 liters of liquid helium



## Compressed SENSE

Enables up to 50% faster 2D and 3D scans with virtually equal image quality



Compressed SENSE is a unique Philips technique, intelligently combining the compressed sensing principle and our sophisticated dSENSE technology.

Some users scan more patients per day (see page 6) after implementing Compressed SENSE. Others use it to fit an additional sequence in the exam, increase spatial resolution or reduce breath hold time to make it easier for patients to comply (see page 12)

### How can Compressed SENSE benefit you?

- Enables 2D and 3D scans to be up to 50% faster with virtually equivalent image quality<sup>4</sup>
- Can be used in all anatomical contrasts and all anatomies
- Can accelerate not only sequences but your entire exam
- Speed may be traded in for increased spatial resolution

<sup>1</sup> Even in the rare case of the magnet becoming unsealed, the negligible amount of helium escaping would not materially affect the oxygen level within the room

<sup>2</sup> Compared to Ingenia 1.5T ZBO magnet

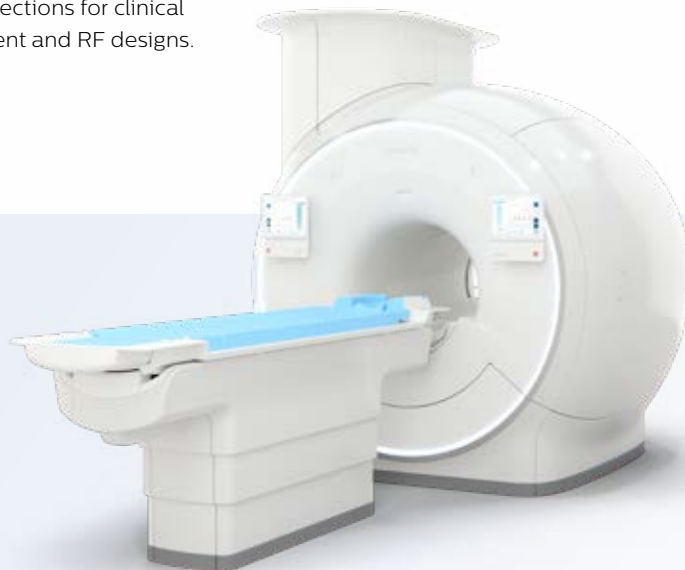<sup>3</sup> Compared to Philips belt-based signal. Requires an unobstructed line of sight

<sup>4</sup> With Compressed SENSE. Compared to Philips exams without Compressed SENSE

## Ingenia Elition 3.0T

**A revolutionary breakthrough in diagnostic quality and speed**

The Philips Ingenia Elition 3.0T solution offers cutting-edge MR imaging techniques, while setting new directions for clinical research in 3.0T imaging based on new gradient and RF designs.





## KNC can scan **three more patients per day** with Compressed SENSE

**KOYASU Neurosurgical Clinic sees an average of 14% higher patient throughput after implementing Compressed SENSE for fast MRI**

In the months after they integrated Compressed SENSE in their MRI ExamCards, KOYASU Neurosurgical Clinic (KNC) in Kanagawa, Japan, has been able to scan over three additional MRI patients per day on average. Compressed SENSE made it possible to decrease time slot length from 20 to 15 minutes per patient without sacrificing image quality. This resulted in several observable benefits for the KNC team.

## Full MRI schedule and overtime

KOYASU Neurosurgical Clinic serves patients within its neurosurgery, neurology, cardiovascular and radiology departments. It houses two Philips MRI systems, Ingenia 3.0T CX and Ingenia 3.0T. MRI operation time typically lasts 9-10 hours per day during weekdays, and 5 hours per day on Saturdays. The radiologists work remotely and receive the cases via a network.


Early in 2017, the MRI scanners were usually fully booked, and scanning often continued past the regular opening hours, leading to staff overtime. Also, the full schedule barely allowed for the accommodation of urgent patients that were referred the same day, and for whom MRI results were needed quickly. Yet, the facility prefers to have such flexibility, allowing for efficient outpatient visits that include physician consultations as well as diagnostic imaging on the same day.

This is why Dr. Hideki Koyasu, President of KOYASU Neurosurgical Clinic, was immediately interested in being among the first sites to implement Compressed SENSE, a Philips technology for up to 50% faster 2D and 3D MRI scans\*.

## Choosing Compressed SENSE to reduce scanning time

KNC decided to add the Compressed SENSE functionality on their Ingenia 3.0T CX. On average, about 27 patients per day were scanned on this MRI scanner prior to implementation of Compressed SENSE. Brain examinations were by far the largest fraction of examinations, though lumbar spine, cervical spine and a few other exams were also done.

Time slots of 20 minutes were allotted for patient positioning and scanning. The actual examination time slot was between 15 and 20 minutes for brain and lumbar spine MRI exams; cervical spine exams lasted slightly longer. >>



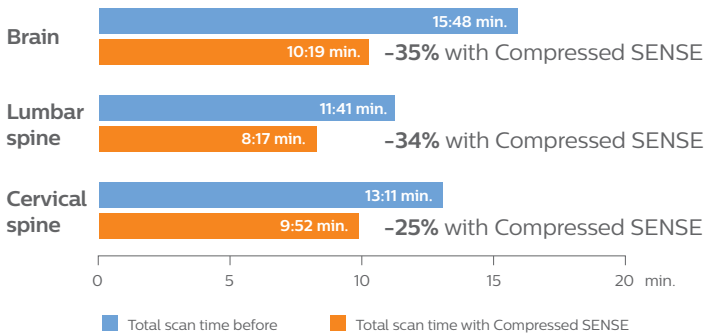
**Hideki Koyasu, PhD**  
Neurosurgeon and Director of KOYASU Neurosurgical Clinic in Kanagawa, Japan.



**Katsuhiko Shiba, RT**  
Radiological technologist and Chief of Radiological Technology at KOYASU Neurosurgical Clinic in Kanagawa, Japan.

*“We still perform as many sequences as before we had Compressed SENSE – it’s just much faster now”*

## Reduction of scanning time with Compressed SENSE in ExamCards of KOYASU Neurosurgical Clinic



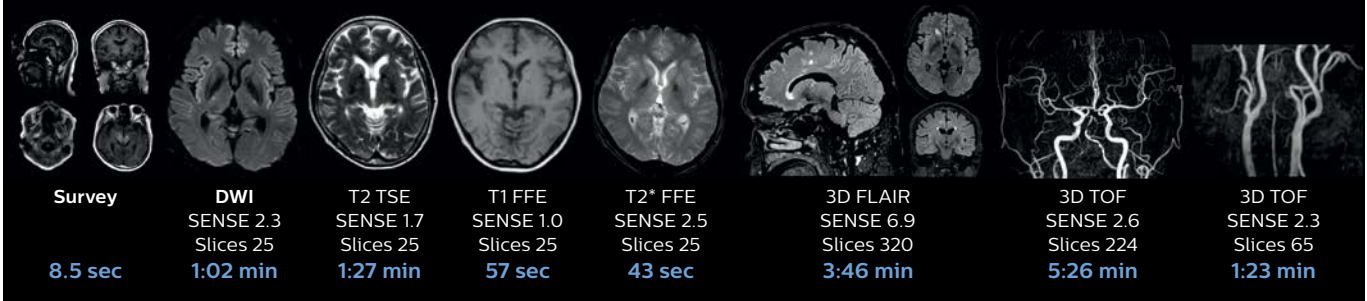
*“The shorter exams alleviate the pressure on our full daily schedule of MRI patients”*

### Fast MRI of brain

With Compressed SENSE, the scan time for the routine brain examination at KNC was reduced from 15:48 to 10:19 minutes, which corresponds to 35% reduction. Ingenia 3.0T CX

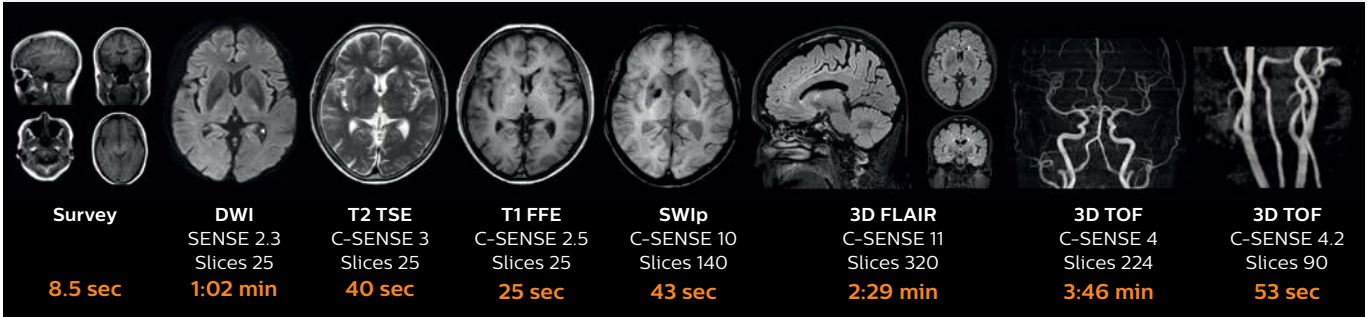
#### Brain without Compressed SENSE

Scan time **15:48 min.**

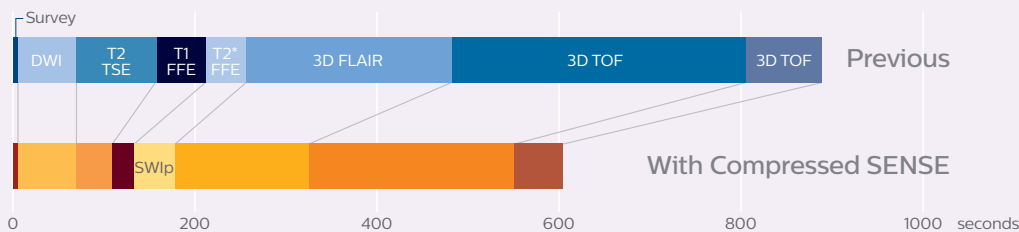


#### Brain with Compressed SENSE

Scan time **10:19 min.**



### Scanning time reduction in brain MRI with Compressed SENSE



*“We now can scan four brain exams per hour instead of only three before using Compressed SENSE”*

### Average time per patient drops from 20 to 15 minutes

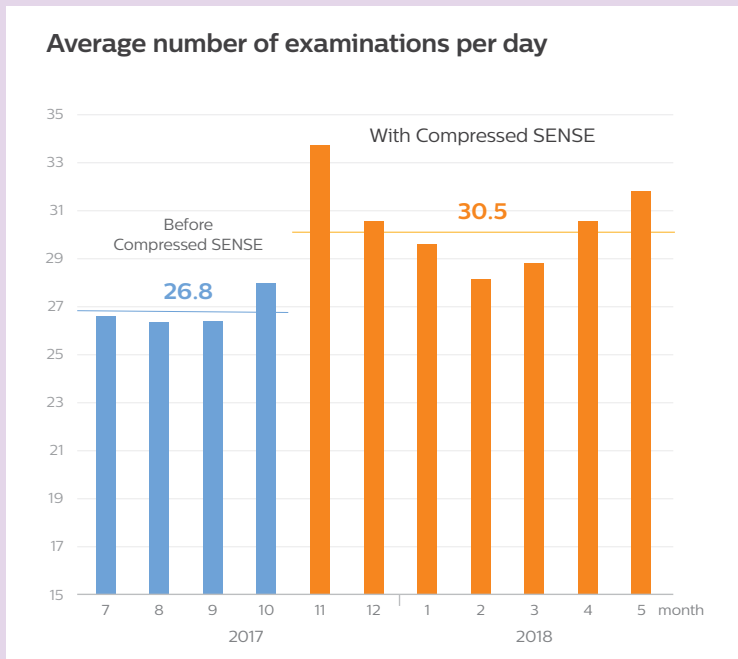
In November 2017, the Philips team in Japan installed the Compressed SENSE functionality on the Ingenia 3.0T CX, including a set of ExamCards.

“We started scanning with a new set of ExamCards in which several sequences were replaced by sequences with Compressed SENSE,” says Dr. Koyasu. “We performed only a little further tailoring of ExamCards to meet our preferences. And as a result, we now can scan four brain exams per hour instead of only three before using Compressed SENSE.”

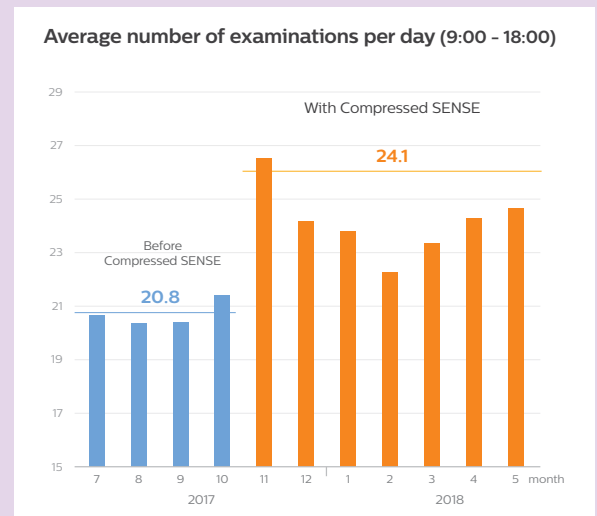
The KNC team significantly reduced the scanning time of their most used ExamCards, see table and diagram.



## A higher average number of patients scanned per day in each month after KNC started using Compressed SENSE



This 11-month diagram shows that the average number of patient examinations per day on the Ingenia 3.0T CX has increased since Compressed SENSE is used. Although the highest throughput was achieved in the first month of using Compressed SENSE, the graphs demonstrate the realization of higher throughput of 14% on average over a longer term.



In order to exclude the effect of overtime, the daily average number of patients scanned between 9:00 and 18:00 h was also calculated. It confirms that on average three additional patients per day were scanned since implementation of Compressed SENSE.

### Six additional patients per day in the first month

“We still perform as many sequences as before we had Compressed SENSE – it’s just much faster now,” says MRI technologist Katsuhiko Shiba.

“In September and October our average number of patients per day was about 27 on Ingenia 3.0T CX. We started using Compressed SENSE in November and we completed that month with scanning an average of more than 33 patients per day. That is 6 more patients per day than in September and October!”

### Faster MRI helps KNC in working efficiently

Dr. Koyasu points out the key strength of Compressed SENSE. “It significantly speeds up our scanning, and in my perception, we obtain the same image quality as before without Compressed SENSE.”

MRI technologist Shiba is working daily with Compressed SENSE.

“We manage to perform most of our MRI examinations within 15 minutes now, which includes the time needed to exchange patients,” he says.

“In MRI we are working with two staff members – one for operating the scanner from behind the console and one for screening and positioning patient. Thanks to the faster scanning with Compressed SENSE, we are currently operating MRI quite efficiently. I think that our MRI operation is gradually becoming similar to our way of working in CT scanning,” says Shiba. >>

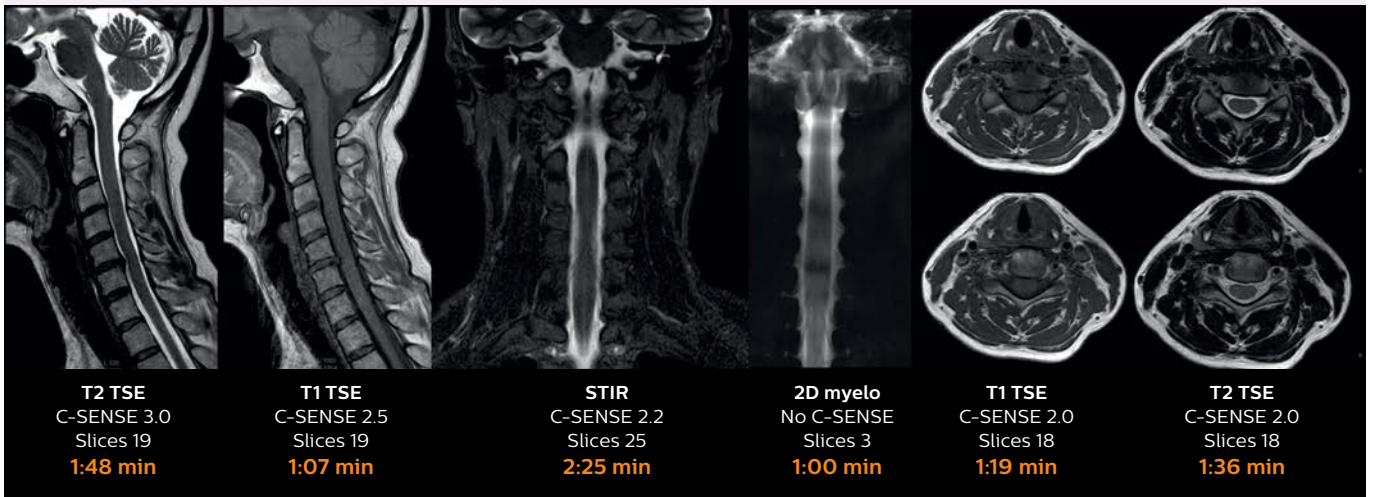
**“We can now provide a more flexible and faster MRI service to our patients and referring physicians”**



### Fast MRI of cervical spine with Compressed SENSE

With Compressed SENSE, the scan time for the routine cervical spine examination at KNC was reduced from 13:11 to 9:52 minutes, which corresponds to 25% reduction. Ingenia 3.0T CX

Scan time **9:52 min.** (was 13:11 min. without Compressed SENSE)

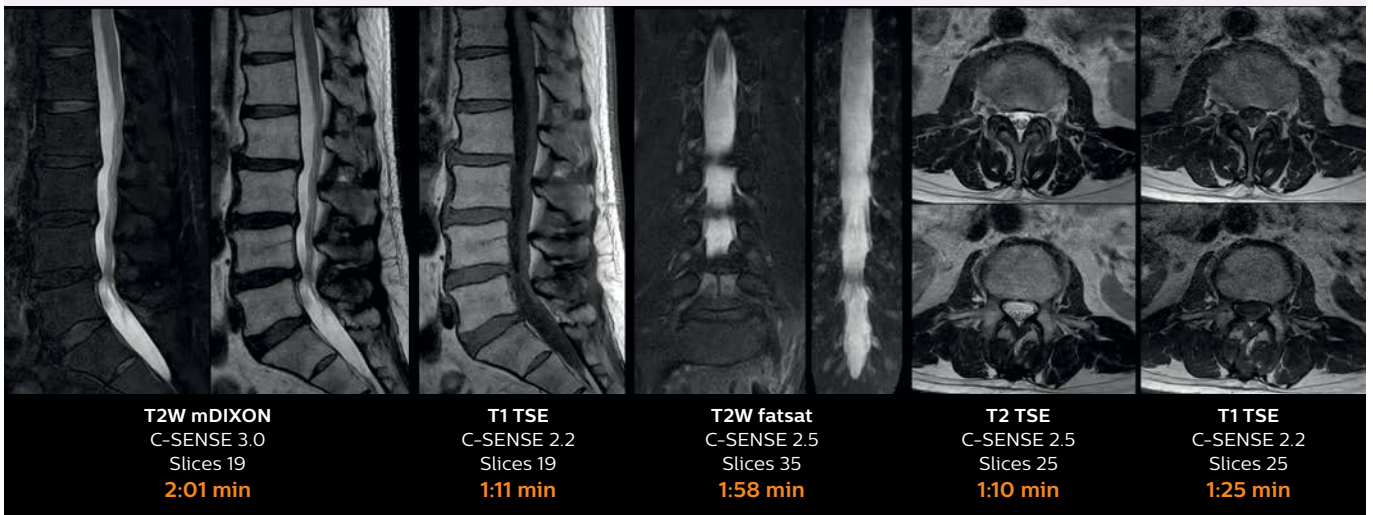


### Fast MRI of lumbar spine with Compressed SENSE

With Compressed SENSE, the scan time for the routine lumbar spine examination at KNC was reduced from 11:41 to 8:17 minutes, which corresponds to 34% reduction. Ingenia 3.0T CX

Scan time **8:17 min.** (was 11:41 min. without Compressed SENSE)

Ingenia 3.0T CX



*“We now only need about 10 minutes scan time for a brain exam and we still get the same amount of images and equal quality”*



### **Patients need to lie still for a shorter time**

According to Dr. Koyasu, the acceleration provided by Compressed SENSE is accompanied by some additional benefits. “Compressed SENSE helps us to reduce the time that a patient needs to lie still in the magnet bore. This is nice for patients and can also benefit image quality, as in general the occurrence of motion artifacts tends to be worse in longer scans,” he says.

“When motion artifacts occur, we usually repeat a sequence within the same examination. Before we used Compressed SENSE, it was quite common to perform rescans because of motion artifacts,” Shiba says. “We see motion quite rarely now. We believe that patients are moving less when our scans are faster. So Compressed SENSE can help us there as well.”

### **More flexibility, less stress**

“The shorter exams alleviate the pressure on our full daily schedule of MRI patients,” says Shiba. “Thanks to Compressed SENSE, we have increased the number of MRI examinations that we perform and on top of that we also manage to reduce overtime. We are happy to finish our work days earlier than before.”

“We can now provide a more flexible and faster MRI service to our patients and referring physicians,” says Dr. Koyasu. “For instance, when a referring physician is requesting it, we can now quite smoothly insert an additional MRI examination without previous appointment on the same day. Referring physicians as well as MRI staff indicate that their stress level is reduced when this workflow works well.”

### **Brain MRI scan time reduced from 15 to 10 minutes**

The most frequently used brain MRI examination at KNC included approximately 15 minutes of scanning time, and was quite comprehensive with fairly short scan times. When Compressed SENSE became available, its great impact on the brain exam quickly became clear.

“We now only need about 10 minutes of scan time for a brain exam – and we still get the same amount of images and equal quality. We even managed to make a very useful improvement: we replaced the 43-second T2\* FFE by a 43-second SWIp, which is more powerful for us in making confident diagnoses in certain patients.”

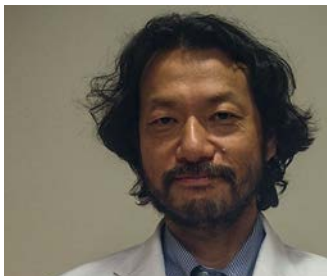“SWIp was not previously included in our standard protocol, because of its slightly longer scan time. SWIp provides high resolution 3D susceptibility weighted imaging in the brain, which helps to visualize small deoxygenated blood or calcium deposits. Now, with Compressed SENSE, we can perform 3D SWIp in only 43 seconds, so we have included SWIp instead of the 2D T2\* FFE that we used previously. Without adding scan time, we now get SWIp images in every routine brain scan and it helps us increase our diagnostic confidence in certain cases.” <<

*“Compressed SENSE helps us to reduce the time that a patient needs to lie still in the magnet”*

# High quality and fast scanning with Compressed SENSE at KCH

**At Kurashiki Central Hospital, use of Compressed SENSE resulted in faster and higher quality MRI scans\*, which is welcomed by patients and staff**

The MRI staff at Kurashiki Central Hospital incorporated Compressed SENSE into most of the brain, spine, abdominal, and cardiac examination protocols on their Ingenia 1.5T. Compressed SENSE accelerates sequences\* without sacrificing image quality. The team realized significant decreases in scanning times, as well as shortened breath hold times that are easier for patients to achieve. In other cases, the acceleration is used for higher spatial resolution or adding an extra sequence. The staff is experiencing increased flexibility thanks to the shorter scanning times, and decreases in workload pressure. After seeing its capabilities on Ingenia 1.5T, KCH decided to acquire Compressed SENSE for two additional MRI scanners.




**Takashi Koyama, MD, PhD**  
Diagnostic radiologist and Director of the Department of Radiology Center and Diagnostic Radiology at Kurashiki Central Hospital.



**Masayuki Kumashiro, PhD**  
Radiological technologist and Director of Radiological Technology Kurashiki Central Hospital. He is Vice President of Japan Association of Radiological Technologists.



**Koshi Miyake, MD**  
Cardiologist and Chief Physician in Department of Cardiology at Kurashiki Central Hospital. He is a Board certified member of the Japanese Circulation Society.



**Sachi Fukushima, RT**  
Radiological technologist and member of the MR technical staff at Kurashiki Central Hospital. She is a certified technologist, and an authorized magnetic resonance technological specialist.

***“After seeing the improvements that Compressed SENSE brought for Ingenia 1.5T, we decided to also acquire Compressed SENSE for two additional MRI scanners”***

## **Improvements in scanning without sacrificing image quality**

At Kurashiki Central Hospital (KCH) in Japan, the MRI staff is always looking for ways to improve image quality and to scan faster. As one of the goals of faster scanning, they mention improving the MRI examination for patients, for instance by reducing breath hold duration and overall scanning time. This can make it easier for patients to comply, which in turn benefits the imaging results. An additional aim is to gain time for the MRI technologists, to relieve the pressure of their high workload and to give them more time to attend to their patients.

\*Compared to examinations without Compressed SENSE.

**“Because the faster scanning with Compressed SENSE saves us time, we can add a sequence to obtain high quality spine images for confident diagnoses”**

When the staff at Kurashiki heard about Compressed SENSE, they were eager to learn about its capabilities, and what these could mean for their staff workload and patient comfort. KCH is a general hospital that scans approximately 110 patients a day using seven MRI systems. Compressed SENSE was first installed on their Ingenia 1.5T scanner. The staff quickly appreciated substantial decreases in scan times and decreases in breath hold requirements, without having to compromise on image quality.

**Convincing results driving quick adoption**

The Compressed SENSE technology allows users to accelerate their 2D and 3D sequences by up to 50%.\* The staff at KCH has noticed reduced noise in many Compressed SENSE images in different anatomies, allowing them to increase the spatial resolution. “We are now using Compressed SENSE for almost all of our sequences in brain, spine and abdominal examinations,” says technologist Masayuki Kumashiro, PhD.

According to KCH diagnostic radiologist Dr. Takashi Koyama, Compressed SENSE is extensively used in brain and spine examinations. Both of which require high quality images, and it is possible to obtain excellent quality images even when using higher Compressed SENSE factors (C-SENSE factors) for decreasing scan times.

Brain protocols were the first to be converted to Compressed SENSE, according to MRI technologist Sachi Fukushima.

“We started with comparing the image quality of Compressed SENSE with our original SENSE images in five cases of brain imaging. For 2D images for instance, we looked for possible changes in contrast and structural details when changing from a SENSE factor of 2.0 to a C-SENSE factor of 2.4. We also examined image quality obtained with different denoising parameters.” This convinced the Kurashiki team that image quality would not suffer by switching from SENSE to Compressed SENSE.

**Fast brain scanning allows to include more high resolution 3D sequences**

According to Fukushima, the high spatial resolution desired in brain and spine, used to typically require quite long scan times, but now the speed provided by Compressed SENSE may be traded for increased spatial resolution when necessary.

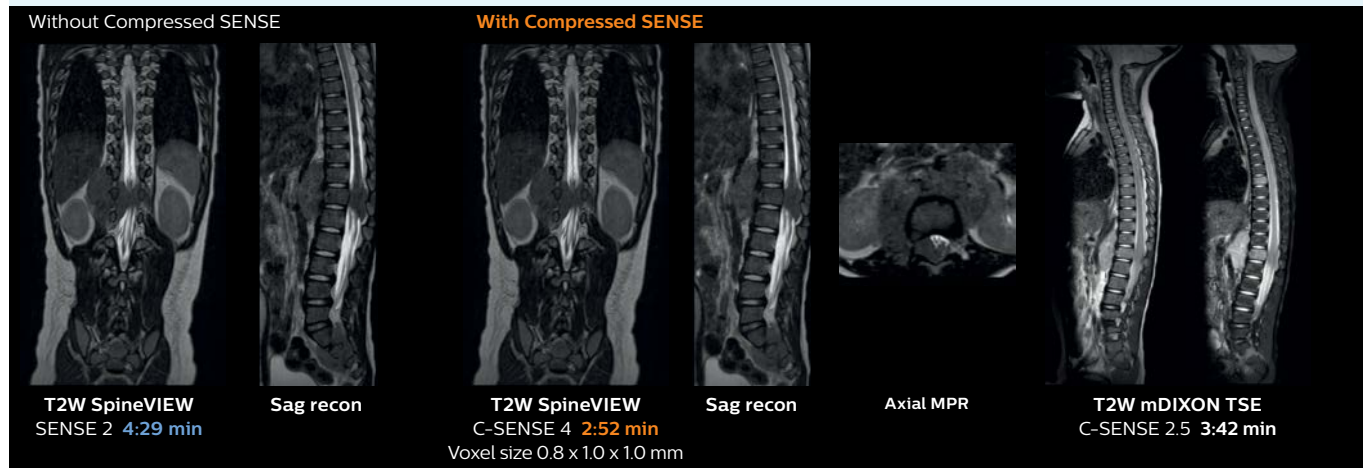
“For several brain examinations we use Compressed SENSE for faster\* 2D and 3D scanning. High resolution sequences such as TOF and 3D usually take the longest, but with Compressed SENSE we obtain really good quality, even when using a higher C-SENSE factor for decreasing scan time as compared to images with SENSE.”

“In the 3D TOF MR angiography sequence, we decided to use a C-SENSE factor of 3.5, after carefully examining the quality of the inflow signal and the detailed structure of the cerebral blood vessels using this higher factor.” >>

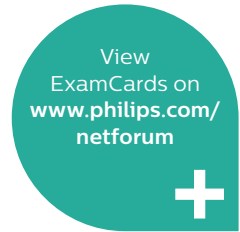**Pediatric spine with neuroblastoma**

This child with neuroblastoma underwent MRI on the Ingenia 1.5T. Compressed SENSE was used to reduce scan time while maintaining the high resolution for 2D mDIXON and 3D SpineVIEW in this case. The highly detailed images allowed the radiologist to make a quick and confident assessment of the position of the nerve and the tumor. Especially important for a pediatric patient, is that a shorter scan time also allows us to keep the sedation time as short as possible.

As this was one of the first patients scanned with Compressed SENSE, 3D SpineVIEW was acquired with and without Compressed SENSE to allow comparison. Although the Compressed SENSE sequence was significantly faster, the acquired and reconstructed 3D SpineVIEW images show virtually the same image quality.



**“Compressed SENSE has allowed us to increase spatial resolution in breast MRI, which benefits our diagnostic confidence”**



**Boosting diagnostic confidence with multiple contrasts, multiple orientations in spine MRI**

The KCH team has already changed most of their Ingenia 1.5T spine ExamCards by incorporating Compressed SENSE into their 2D TSE, mDIXON TSE, FFE, and 3D sequences.

“Previously with SENSE, our 2D mDIXON TSE scans required relatively long scan times. But now, with Compressed SENSE, we have reduced these scan times while maintaining a high SNR, because the Compressed SENSE technology helps reduce noise,” says Dr. Koyama.

“Because the faster scanning with Compressed SENSE saves us time, we can sometimes add a sequence to obtain high quality spine images in the same time slot for confident diagnoses.

And in cervical spine exams, a 2D sequence is sometimes replaced by a 3D protocol, which provides us more information as it can be reformatted in different orientations. Compressed SENSE allows us to easily add this 3D sequence in the timeslot,” says Fukushima.

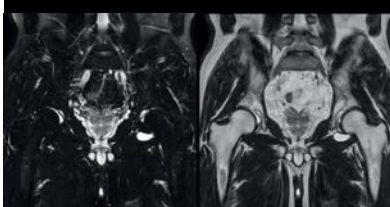
“Incorporating Compressed SENSE in common spine sequences, such as mDIXON, 3D SpineVIEW and eTHRIVE, can substantially reduce the scanning time of these sequences, while maintaining adequate spatial resolution, resulting in high quality, multiple contrasts, multiple orientations,” says Dr. Koyama.

“In addition, fast sequences generally make it easier for patients to stay motionless throughout the scans, so it also helps us in that way.”

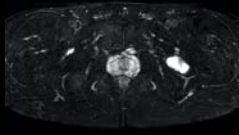
**Hip with synovial cyst w/wo Compressed SENSE**

Ingenia 1.5T MRI scans with and without Compressed SENSE are compared for this case of a hip with a synovial cyst. In the mDIXON sequence, the Compressed SENSE factor used is higher than the SENSE factor on the previous scan, so scan times are reduced without sacrificing image quality. The high resolution images are useful for diagnosing of a detailed dissection. The diffusion TSE with Compressed SENSE shows reduced noise compared to the Diffusion TSE with SENSE and the artifact has disappeared. So in this case, Compressed SENSE helped in reducing scan times of the examination. The Compressed SENSE images allowed the radiologist to confidently diagnose the lesion and see the anatomic relationships of the abnormal signal to the surrounding structures.

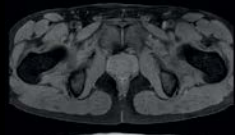
**Without Compressed SENSE**



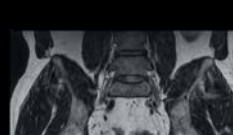**T2W mDIXON TSE**  
SENSE 1.2 **4:09 min**



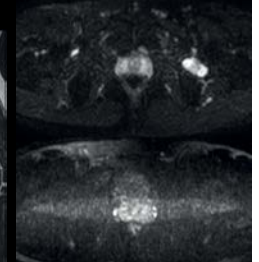
**T2W mDIXON TSE**  
SENSE 1.2 **4:10 min**



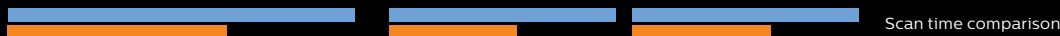**T1W mDIXON TSE**  
SENSE 1.2 **3:50 min**



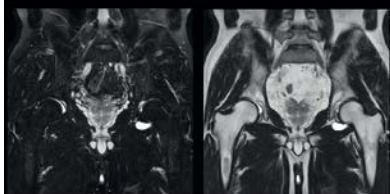
**3D PelvisVIEW**  
SENSE 6 **4:12 min**  
1 x 1 x 2 mm



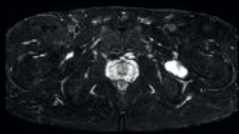
**DWI TSE b0, b1000**  
SENSE 3



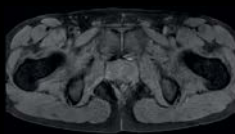
**With Compressed SENSE**



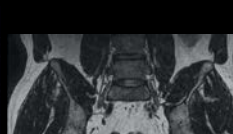**T2W mDIXON TSE**  
C-SENSE 2 **2:39 min**



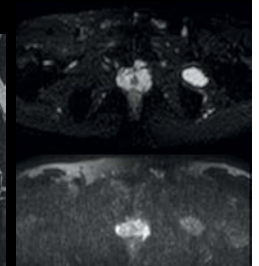
**T2W mDIXON TSE**  
C-SENSE 2 **2:20 min**



**T1W mDIXON TSE**  
C-SENSE 2 **2:20 min**



**3D PelvisVIEW**  
C-SENSE 6 **4:16 min**  
1 x 1 x 1 mm

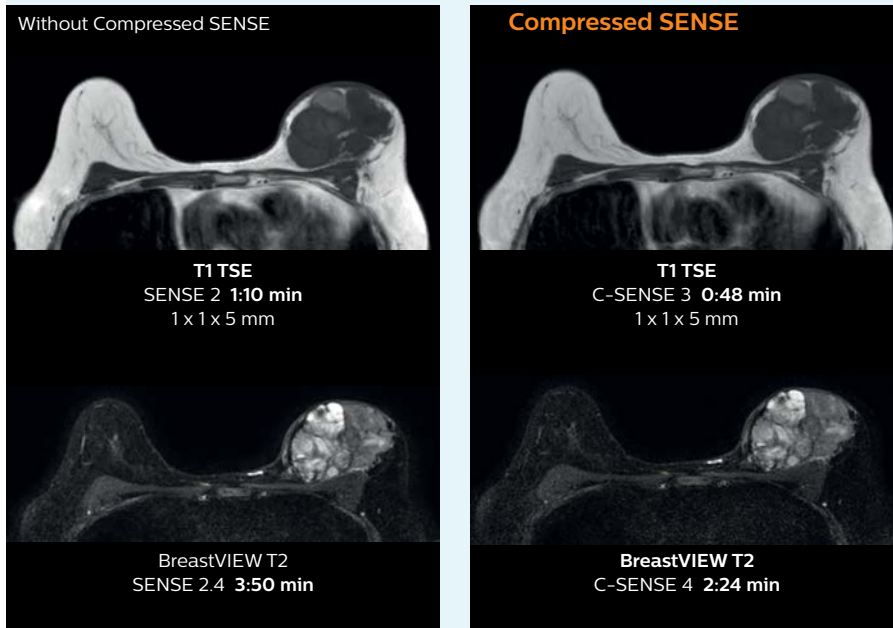


**DWI TSE b0, b1000**  
C-SENSE 2.5 **3:14 min**  
2.68 x 2.65 x 5 mm

## 3D MRI with Compressed SENSE of patient with breast cancer

This patient underwent MRI on Ingenia 1.5T with Compressed SENSE. Compressed SENSE was used to reduce the scan time in order to decrease the time that the patient may experience discomfort and pain, both of which may lead to patient motion. The 3D BreastVIEW and 3D high resolution mDIXON images – both mDIXON contrasts are acquired in the same exam – show high quality images even with the shorter scan time.

For breast imaging, a fast, high resolution scan can be important for a female patient having to lie in an uncomfortable, face-down position in the scanner. Compressed SENSE also helps us to obtain high quality images using 3D BreastVIEW and 3D high resolution mDIXON sequences in the same examination time as in our previous exam protocol.



***“Since short breath hold times make it easier for our patients to comply, the failure of breath holding largely disappeared”***

### Identification of small breast lesions requires high resolution

Dr. Koyama says that he used to believe that high resolution MRI at 1.5T required long scan times, and SNR was low. “With Compressed SENSE, however, it is possible to acquire high quality images, even with higher Compressed SENSE factors, so in a quite short time. In breast scanning, high resolution is important to help me identify very small mammary lesions, so, we need high spatial resolution in 2D T1- and T2-weighted images, as well as a short scan time. Compressed SENSE has allowed us to increase spatial resolution, which benefits our diagnostic confidence.”

“In 3D dynamic breast scanning we need, in addition to a high temporal resolution, also a high spatial resolution, which helps us to see details of the internal structure of the lesion and to see lesions separately from normal anatomic structures. We can also see if a lesion extends into adjacent organs and anatomic structures.”

### Shortening scan times to reduce breath hold failures in abdominal MRI

While breath holds are vital for image quality in many abdominal MRI scans, commonly used breath hold times of around 25 seconds or more can be challenging, for instance when a patient is sick, in pain or stressed. Failed breath holds can decrease image quality and add to scan time.

KCH technologist Fukushima recognizes the impact of Compressed SENSE on breath hold times. “Before we started using Compressed SENSE, some high resolution 3D examinations used to require long breath holds, because when scan times were shortened, images would often become noisy in the center of the body. But now, Compressed SENSE allows us to further decrease scan times without that increased noise.”

Dr. Koyama particularly focused on reducing breath hold times in abdominal MRI, as these patients often need to perform many breath holds in one examination. “In liver scans we were able to shorten our scanning time – and thus reduce breath hold time – from 22 to 13 seconds by using a higher C-SENSE factor. Since shorter breath hold times make it easier for patients to comply, we saw breath holding failures largely disappeared, allowing the exam to be finished smoothly.” >>

### Pelvis with myoma, comparison w/wo Compressed SENSE

In this MRI exam of pelvis in a patient with myoma, Compressed SENSE is used to accelerate individual sequences and thus the entire examination on Ingenuia 1.5T.

Compressed SENSE allowed for a decrease in scan time for the T2 TSE from 3:38 to 1:46 minutes. The Compressed SENSE images in this case show fewer motion artifacts than the images from the previous protocol with SENSE.

In 3D PelvisVIEW, the Compressed SENSE images have a higher and isotropic spatial resolution with a scan time similar to the SENSE sequence. The improved spatial resolution and better contrast in the myometrium of the uterus allowed radiologist Dr. Koyama to confidently diagnose the cancerous lesion in the uterus.

The use of Compressed SENSE accelerates scanning times and increases spatial resolution in 3D PelvisVIEW.

Without Compressed SENSE

**bTFE**  
SENSE 3 x 11:55 min

**T2 TSE**  
SENSE no 3:38 min

**PelvisVIEW**  
SENSE 2 x 1.5 3:47 min  
1 x 1 x 2 mm

Scan time comparison

With Compressed SENSE

**bTFE**  
C-SENSE 5.5 1:11 min

**T2 TSE**  
C-SENSE 2 1:46 min

**PelvisVIEW**  
C-SENSE 6 3:50 min  
1 x 1 x 1 mm  
Same time, higher resolution

*“We first compared image quality before switching from SENSE to Compressed SENSE”*

*“In cardiac MR we can now increase from two to four slices per breath hold”*



### Acute myocardial infarction w/wo Compressed SENSE

These images of a patient with acute myocardial infarction images were acquired on Ingenuia 1.5T with and without Compressed SENSE.

Without Compressed SENSE

**bTFE cine**  
SENSE 2 x 1.4 5.5 sec

**T1 BB**  
no SENSE 2 x 1.4 12 sec

**T2 STIR BB**  
SENSE 2 14 sec

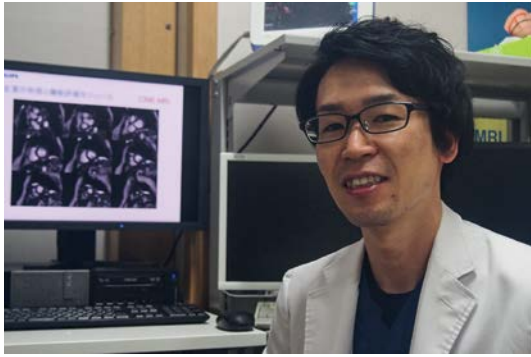
With Compressed SENSE

**bTFE cine**  
C-SENSE 6 3.6 sec

**T1 BB**  
C-SENSE 2 7.4 sec

**T2 STIR BB**  
C-SENSE 3 12 sec





## Making Cardiac MR faster and easier for patients



*“In cardiac MR fewer breath holds are now needed, or breath hold times are shortened”*

“In our abdominal EOB examination, we previously used a SENSE factor of 2 in T2w TSE with a scan time of 24 seconds in one breath hold. But now, C-SENSE factor 2 helped us reduce this to only 16 seconds. And the 3D eTHRIVE changed from SENSE factor 3 with 20 seconds breath hold to C-SENSE factor 5 with only 16 seconds breath hold time.

### Faster\* cardiac imaging with fewer or shorter breath holds

Dr. Koshi Miyake, cardiologist, explains that scanning of patients with cardiac arrhythmia can be challenging, as scanning times can become very long due to the varying heart rate. So his most important motive to implement Compressed SENSE in cardiac MRI exams was to reduce the burden of breath holds for the patient, while maintaining high image quality. He hopes this can also help to reduce motion caused by the difficulty for patients to hold their breath.

“Compressed SENSE has now been implemented in all cardiac exams. Thanks to the acceleration, fewer breath holds are now needed, or breath hold times are shortened. This reduces the burden of the exam for cardiac patients, without affecting the quality of information required for cardiac function analyses,” he says. “Because it’s easier for patients to comply with the breath hold times”

“In our previous cardiac cine sequence, we were acquiring two slices during one breath hold. With Compressed SENSE, we increased this to four slices per breath hold. It is also possible to shorten scanning time using a C-SENSE factor of 6 without sacrificing image quality.”

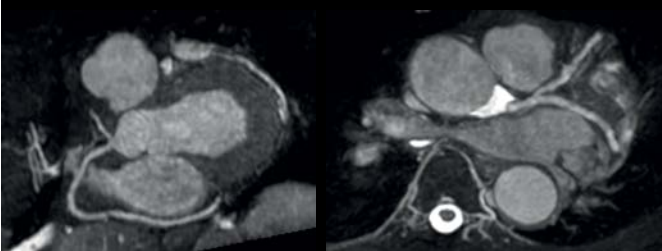
“Typically, in scans with high contrast, such as 2D balanced TFE cine, a quite high C-SENSE factor may be used. When we tried a higher C-SENSE factor, we saw still no significant influence on cardiac ejection fraction, but 2D image quality started to decline. For coronary imaging, we use a C-SENSE factor of 3 in 3D balanced TFE, or even up to 4 when contrast is high.”

### 3D whole heart and coronary arteries w/wo Compressed SENSE

These images with and without Compressed SENSE were acquired on Ingenia 1.5T.

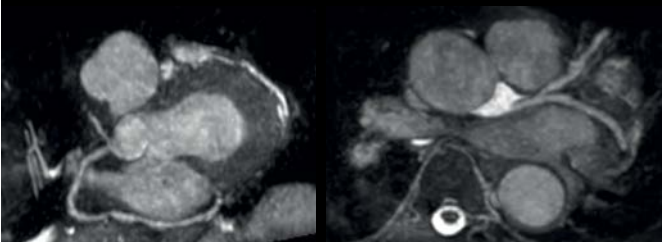
Without Compressed SENSE

SENSE 2 x 1.4, scan time **3:47 min**, voxels 1.29 x 1.26 x 1.8 mm



With Compressed SENSE

C-SENSE 5.6, scan time **2:02 min**, voxels 1.29 x 1.26 x 1.8 mm



Scan time comparison

### KCH to soon extend Compressed SENSE to more scanners

The KCH staff would definitely recommend Compressed SENSE to peers at other institutions. They advise new users to start using it in brain and spine imaging first, as these are the easiest protocols to switch.

According to Dr. Kumashiro, “The most important reason for us to acquire Compressed SENSE has been to achieve higher image quality and make examinations easier for patients by reducing breath hold scan time and examination time. The shorter scan times achieved with Compressed SENSE relieve the stress of a tight work schedule for the MR staff. Technologists can spend the gained time on increasing the image quality, or to take more time for patient preparation and dealing with safety aspects.”

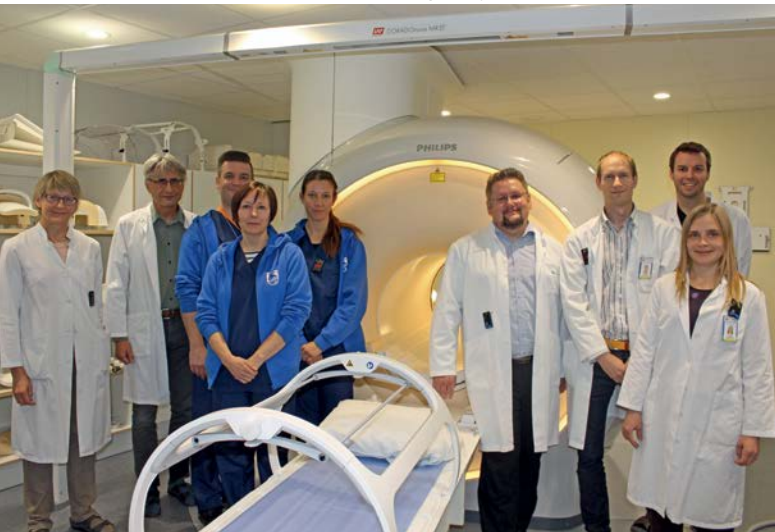“After seeing the improvements that Compressed SENSE brought to the scanning on Ingenia 1.5T, we decided to also acquire Compressed SENSE for two additional MRI scanners,” he concludes. <<

\*Compared to examinations without Compressed SENSE.

# Using MRI only in **prostate cancer radiotherapy** workflow

## MR-only simulation streamlines workflow for prostate cancer radiotherapy

The MR-RT team at Turku University Hospital



**Heikki Minn, MD, PhD** is Professor and Head of TYKS's Department of Oncology and Radiotherapy, where he started in 1985. He has previously held research positions at the Academy of Finland, the University of Michigan and Turku PET Centre in Finland. His current interests are head-and-neck and prostate cancer, CNS neoplasms and neuroendocrine tumors.



**Jani Keyriläinen, PhD** is Medical physicist at TYKS's Departments of Medical Physics and of Oncology and Radiotherapy. Previous positions at the Helsinki University Central Hospital, and the European Synchrotron Radiation Facility, Grenoble. His current interests are MRI in radiotherapy, small-field dosimetry and dose calculation, quality assurance, and stereotactic and adaptive treatments.

Since March 2017, clinicians in the Department of Oncology and Radiation Therapy at Turku University Hospital (Turku, Finland) have been using Philips MR-only simulation for simulating and planning radiation therapy for their patients with prostate cancer. Featuring the solution's MRCAT approach, physicists can obtain the needed electron density information for radiotherapy dose calculations, rendering CT unnecessary in the workflow. Moreover, because co-registration of MRI and CT images is not performed in the MR-only workflow, clinicians can avoid registration errors that force margin increases, while exploiting MRI's exceptional soft tissue visualization to delineate the prostate and organs-at-risk.

### Exceptional soft tissue imaging with MRI

The radiation therapy department at Turku University Hospital (TYKS) has been home to a Philips Ingenia MR-RT 1.5T since January 2016. This Ingenia is a workhorse for the department, as about 60% of the MRI scans performed are to aid in planning the hospital's 1,600 radiotherapy patients per year, with cardiac and emergency diagnostic scans making up the balance. Approximately one in five of the radiotherapy cases are prostate cancer patients and for those, MRI simulation is part of the standard clinical care.

In its traditional CT-MRI simulation and planning workflow, Ingenia has been invaluable for its superb, tunable soft-tissue contrast, particularly for planning prostate cancer cases, according to Prof. Heikki Minn, MD, Radiation Oncologist at TYKS.

***“For prostate visualization, the high soft tissue contrast that MRI provides is very important”***

## Three-phase commissioning process for MR-only simulation at TYKS

	Phase 1	Phase 2	Phase 3
	Testing and preliminary dose calculation comparisons	Validate dosimetric agreement between MRCAT and CT based plans	MR-only clinical workflow, eliminate CT
<b>Simulation imaging</b>	CT and MRI	CT and MRI	MRI
<b>MR-CT image registration</b>	Yes	Yes	No
<b>Delineation</b>	MRI	MRI	MRI
<b>Dose calculation</b>	CT and MRI	CT and MRI	MRI
<b>Treatment</b>	CT plan	MRI plan	MRI plan
<b>Patient cohort</b>	74 prostate cancer patients	62 prostate cancer patients	91 prostate cancer patients (by the end of October 2017)
<b>Duration</b>	8 months	5 months	Ongoing

“For prostate visualization, the high soft tissue contrast that MRI provides is very important,” he says. “Without it, we wouldn’t be able to distinguish the gland from the pelvic muscles and fat surrounding it. That would make it difficult to delineate the prostate and other nearby tissues. We see that our clinical target volume (CTV) for prostate is typically smaller for MRI-based planning, which can help decrease toxicity to the rectum and bladder.

The value of MRI for radiotherapy planning drove the acquisition of the Ingenia for the radiotherapy department. “We wanted to have an MRI in our own department instead of having to use the radiology department’s system, so we can assure our patients get MRI access when it’s feasible for our workflow,” Dr. Minn says.

“Using MR-only simulation and planning would give us a ‘one-stop-shop’ workflow for imaging, contouring and planning of radical radiotherapy for patients with prostate cancer,” he says. “Therefore, we began the commissioning process for MR-only simulation immediately in the same month that we began using our Ingenia.”

### MRCAT dose virtually identical to that of CT-based radiotherapy plans

TYKS’s assistant chief physicist Jani Keyriläinen, PhD and medical physicists Sami Suilamo, Lic.Phil., and Pauliina Wright, PhD, led a three-phase commissioning process for MR-only simulation use in prostate radiotherapy, that began in January 2016 and concluded in March 2017. The first phase lasted eight months and consisted of CT-MRI simulation of a control group involving 74 prostate cancer patients.

“These first patients were planned based on CT simulation, but we also did preliminary dose calculation comparisons with both CT and MRI data sets,” Dr. Keyriläinen says. “In the second

phase, October 2016 to February 2017, we imaged 62 patients with both CT and MRI, but these patients were planned with the MR images only. We felt comfortable doing that because we were using thresholds in the dose calculation comparisons – for the planning treatment volumes PTV mean and PTV median – that were set to 2%. We very rarely went over 1% and the average difference in PTV mean values was 0.8% for all 62 patients in the dose comparison.

In short, the dose differences between MRCAT- and CT- based radiotherapy plans were minimal. That was a really good sign for us to trust MR-only simulation in the third phase.”

“Since March 2017 we have been using MR-only simulation for our prostate patients routinely,” he says. “So all of the plans are based on MR imaging and calculations. Overall, the commissioning phase went smoothly. Because MR-only simulation is a commercial solution, the learning curve was short, which made commissioning much easier and faster. We didn’t have to start from scratch and find all of the tools ourselves.”

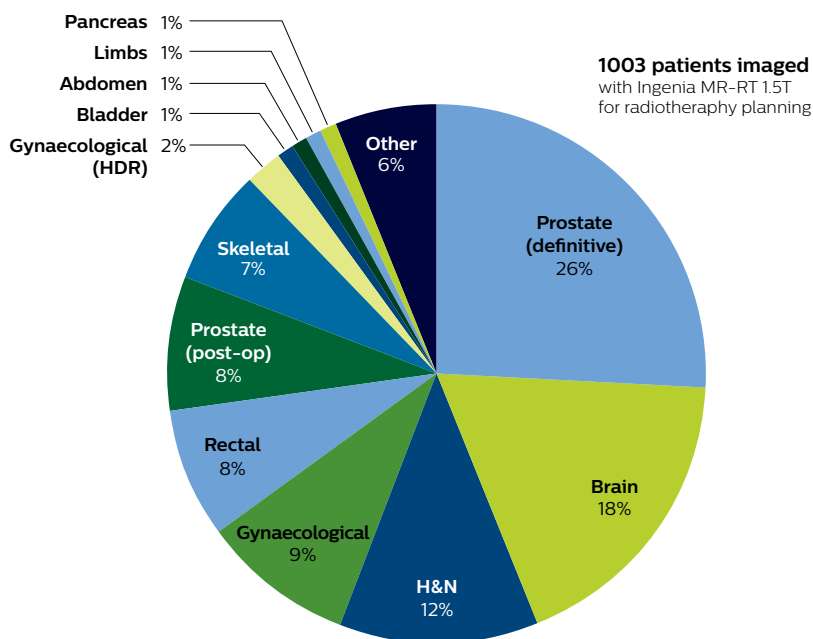
### High geometric accuracy of MRI for radiotherapy

In addition to confirming negligible dose differences between CT- and MRI-based simulation, Drs. Minn and Keyriläinen have established that the geometric accuracy of their Ingenia MR-RT is high and sufficient for radiotherapy planning. Historically, adoption of MRI in radiotherapy had been hindered by geometric distortions, an issue that has been largely addressed by solutions to correct for gradient distortion and by the use of optimized sequences dedicated for use in radiotherapy.

“We have studied this quite carefully, and found that the system-induced geometrical distortion was less than 1 mm for PTV and organs-at-risk (OAR) volumes in the patient group we studied for this,” Dr. Keyriläinen explains.[1] >>

### Distribution of patients undergoing MRI for treatment planning at TYKS

January 2016 - October 2017



*“Since March 2017 we have been using MR-only simulation for our prostate patients routinely”*

### Omitting CT in workflow helps save time and eliminates registration errors

With the omission of a CT scan and CT-MR image registration, MR-only simulation has simplified and shortened TYKS's prostate radiotherapy workflow.

In the TYKS workflow, the initial diagnosis is made with ultrasound-guided biopsy and urological examination. Typically, the MR simulation scan is the first clinical MRI scan the patient receives. There is a strong collaboration with radiologist Terhi Tuokkola, MD, who spends half of her time in the radiotherapy department.

“Her expertise was critical in setting up MR-only simulation. In the beginning, she was instrumental in working with our team of oncologists and MRI physicist on sequence optimization and MR image interpretation. However, her time is limited and our protocol is now a routine process, so getting her diagnostic MRI report for the prostate patients is no longer mandatory,” Dr. Minn observes. “For other clinical areas, such as head-and-neck cancers, that is clearly very different.”

The TYKS MRI examination for generating the images for prostate MR-only simulation includes the standard sequences for MRCAT (Magnetic Resonance for Calculating Attenuation) generation, contouring and fiducial marker visualization. The total scan time for the RT planning sequences is 13 minutes. The ExamCard is customized with additional T2-weighted and DWI sequences for diagnostic purposes which makes total scanning time 26 minutes. The patients are imaged on a flat RT tabletop, using an Anterior MRI coil that is placed on a coil holder to avoid deforming body contours.

The MR images needed for RT planning are exported to the treatment planning system (TPS), where the MRCAT images are handled as a CT image set by the TPS, with no manual postprocessing required. Target and OAR delineation is performed using the T2-weighted images.

### MRI's excellent soft tissue visualization facilitates easier delineation

“Delineation is certainly much easier, if not faster, with MR images than with CT images,” Dr. Minn says. “I definitely think the physicians feel more confident because they can see the prostate more clearly and can delineate more consistently. Undoubtedly, this is difficult to measure or assign value, but it is important; inter-physician variability in contouring is decreasing because it is easier to do.”

Using the mDIXON and 3D bFFE images, the RT planner marks the position of the nickel-titanium fiducial markers, and contours are transferred to the digitally reconstructed radiographs (DRRs). Reference image matching is based on these markers. “In the rare cases, where visualization of the fiducial markers fails, we do a CT to confirm their location,” Dr. Keyriläinen notes.

“We think the robustness is getting along quite well. We have less than 5% of prostate cases that are not working with MRCAT and reasons for the failure normally are patient motion, obesity and implants.” >>

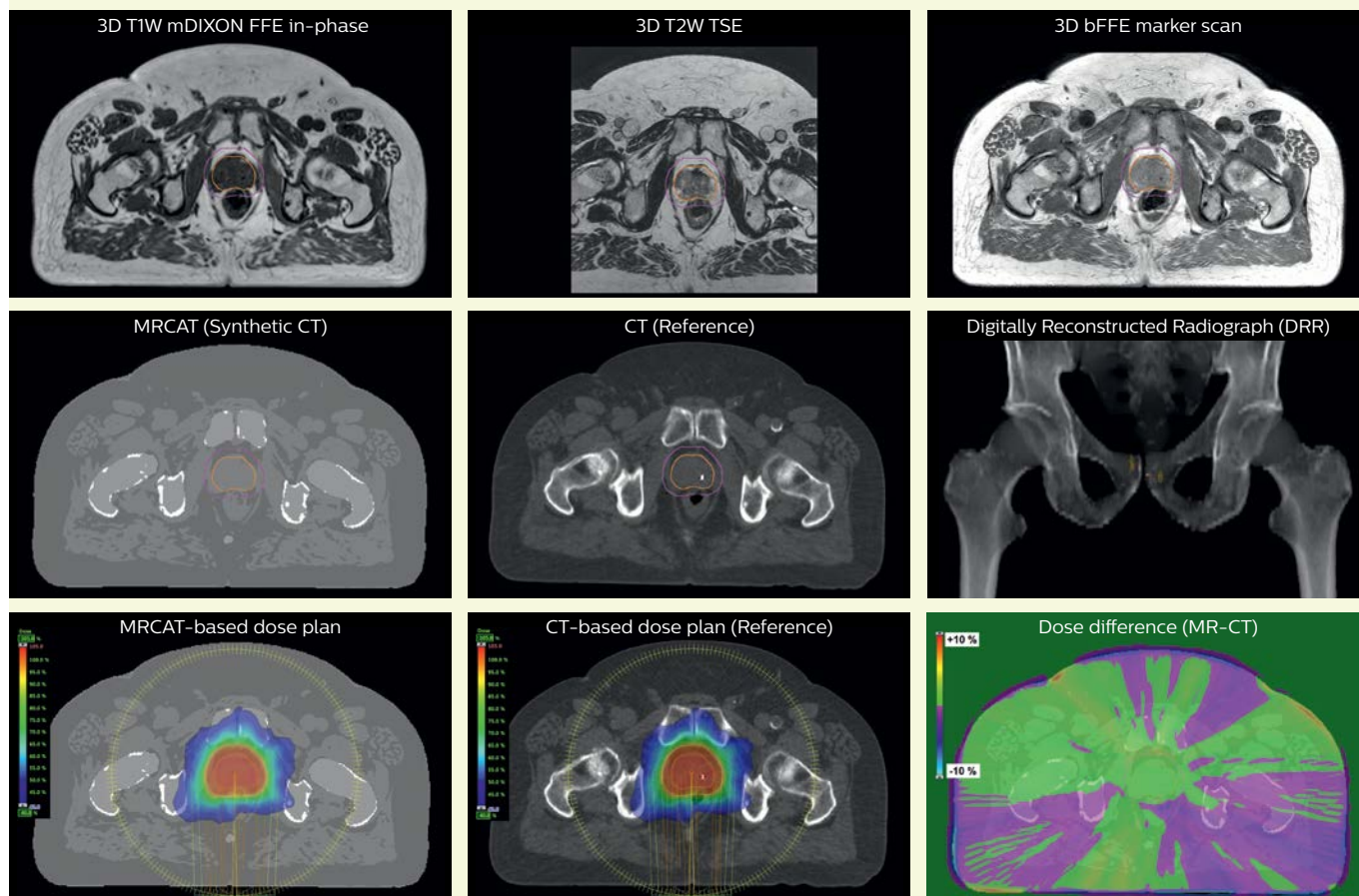
*“Delineation is certainly much easier, if not faster, with MR images than with CT-MR images”*

## TYKS MR-only examination

	Purpose	Sequence	Scan time min.	Total time min.
For <b>TPS</b>	Source for MRCAT generation, to obtain synthetic CT images for dose calculations	T1W mDIXON 3D	3:58	13:07
	Target and OAR contouring	T2W TSE 3D sag	4:20	
	Marker visualization	bFFE 3D	1:02	
	Anatomy delineation	T2W TSE 2D ax	3:47	
For <b>diagnostic purposes.</b> Not routinely transferred to TPS	Anatomy delineation/ lymph nodes visualization	T2W TSE 2D sag*	2:55	12:53
	Anatomy delineation/ lymph nodes visualization	T2W TSE 2D cor*	3:16	
	Apparent diffusion/ lymph nodes visualization	DWI 3 b-values 50/400/800*	6:43	

### MR-only based planning for prostate cancer radiation therapy treatment

A patient with prostate cancer cT3aNOM0, Gleason 8 and PSA 52 µg/L referred to androgen deprivation and radiation therapy with a prescribed dose of 50 Gy to the pelvic lymph node regions and 76 Gy to the prostate.



#### MR-only simulation workflow

The 3D T1W FFE mDIXON sequence provides in-phase, water and fat images in one acquisition. Target and organs-at-risk are delineated on the 3D T2W TSE images. Prostate GTV is shown in orange, PTV in purple. The 3D bFFE sequence is used by the planner to mark the position of the fiducial markers (gold anchors) and contours are transferred to the digitally reconstructed radiographs (DRRs).

Based on the 3D T1W mDIXON images, MR-based density maps (MRCAT) are automatically generated. The VMAT (Volumetric Modulated Arc Therapy) plan is generated in TPS, based on MRCAT as primary image set. During the commissioning phase, dosimetric agreement between MRCAT-based and CT-based dose plans was studied and differences in the PTV dose were found to be minimal (<1% for most patients). Average difference in PTV mean values was 0.8% over the study group (n=62).

Philips Ingenua MR-RT 1.5T using the Anterior coil and the integrated Posterior coil.

## How does MRCAT generation work?

The Philips MRCAT approach for an MR-only based dose planning provides CT-like density information calculated from MR images for dose calculations, as well as high contrast anatomical T2W images for target delineation. [2-3]

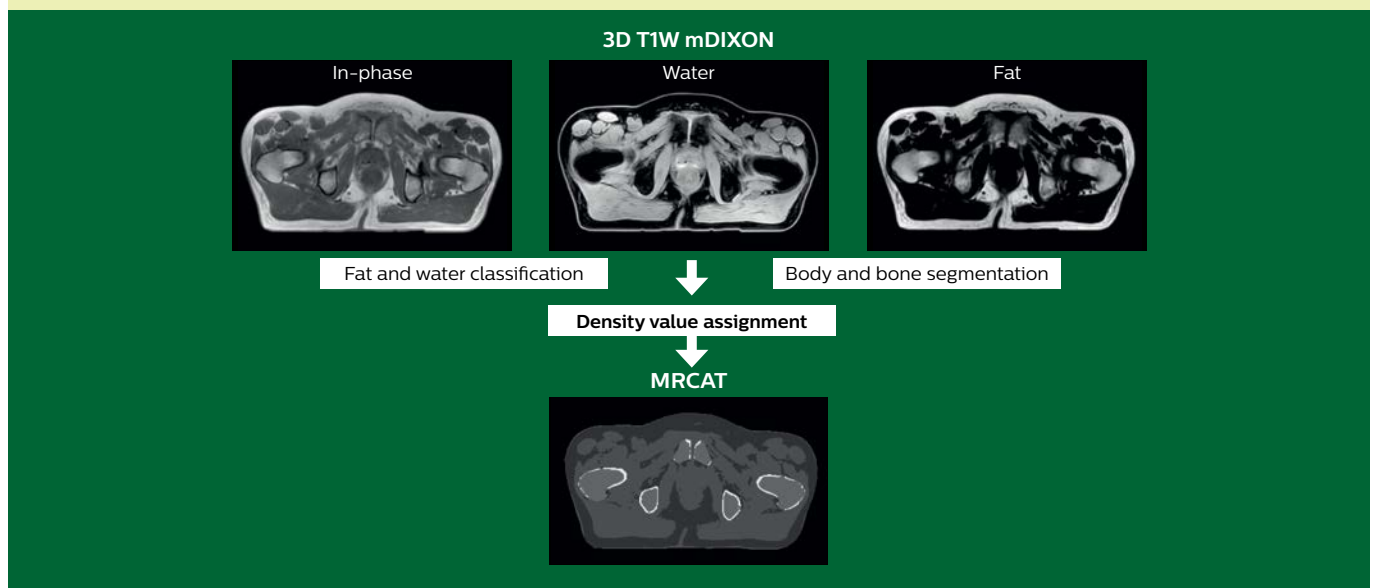
Electron density information is automatically generated on the MR console from a single T1W mDIXON MRI sequence in two steps:

1. MR image contents are categorized into air, fat, water-rich tissue, spongy bone and compact bone using a hybrid approach of image and model-based segmentation.

2. Each voxel is assigned a density value (pseudo-HU value, where HU stands for Hounsfield Unit), based on a combination of average population values and literature values.

The MRCAT images with density information are DICOM conform and can be automatically exported to treatment planning systems (TPS) as primary image dataset for dose calculations and to generate MR-based digitally reconstructed radiographs (DRRs).

Several Philips users have described their experiences with MRCAT in peer-reviewed publications. [1,4-5]



### High staff confidence replaces initial reluctance to use MR-only prostate workflow

TYKS radiation oncologists and physicists adapted quickly to the MR-only simulation for prostate radiotherapy, according to Dr. Minn and Paula Lindholm, MD, PhD, chief radiation oncologist.

“There was some initial reluctance based on limited knowledge about the method, the acquisition technique and different sequences, but now they seem to love the technique, and I think that relates to physician confidence in the soft tissue visualization with MRI,” Dr. Minn says.

“In addition, patients like the fact that they don’t have to spend the time and undergo a scan in a second imaging system, and they don’t receive the dose of ionizing radiation that comes with CT. Truly, we don’t see any downsides to MR-only simulation at the moment.”

### Clinicians look forward to more MR-only simulation applications

“We didn’t intend to implement MR-only simulation just for prostate cases,” Dr. Minn says. “We really need this also for brain and soft tissue tumors such as other pelvic cancer,

head-and-neck cases, sarcomas. Clearly, our use of MR-only simulation at TYKS is only going to increase in the future. And I see that this vision also lives in the greater community, as we receive many requests from other Nordic sites to consult with us on how to start MR-only simulation.” <<

### References


1. Kemppainen R, Suilamo S, Tuokkola T, et al. *Magnetic resonance-only simulation and dose calculation in external beam radiation therapy: a feasibility study for pelvic cancers.* Acta Oncologica, 56(6), 2017.
2. Köhler M, Vaara T, van Grootel M, et al. *MR-only simulation for radiotherapy planning – White paper: Philips MRCAT for prostate dose calculations using only MRI data.* 2015.
3. Schubert G, Vaara T, et al. *Commissioning of MR-only simulation for radiotherapy planning – White paper.* www.philips.com/mrcat. 2017.
4. Christiansen RL, Jensen HR, Brink C. *Magnetic resonance only workflow and validation of dose calculations for radiotherapy of prostate cancer.* Acta Oncologica, 56(6), 787-791, 2017.
5. Tyagi N, Fontenla S, Zhang J, et al. *Dosimetric and workflow evaluation of first commercial synthetic CT software for clinical use in pelvis.* Phys Med Biol., 62(8), 2961-2975, 2017.

# Direct visualization of nerves can influence surgery decisions

## Northern Fukushima MRI team adds 3D NerveVIEW sequence to visualize spinal nerve abnormalities

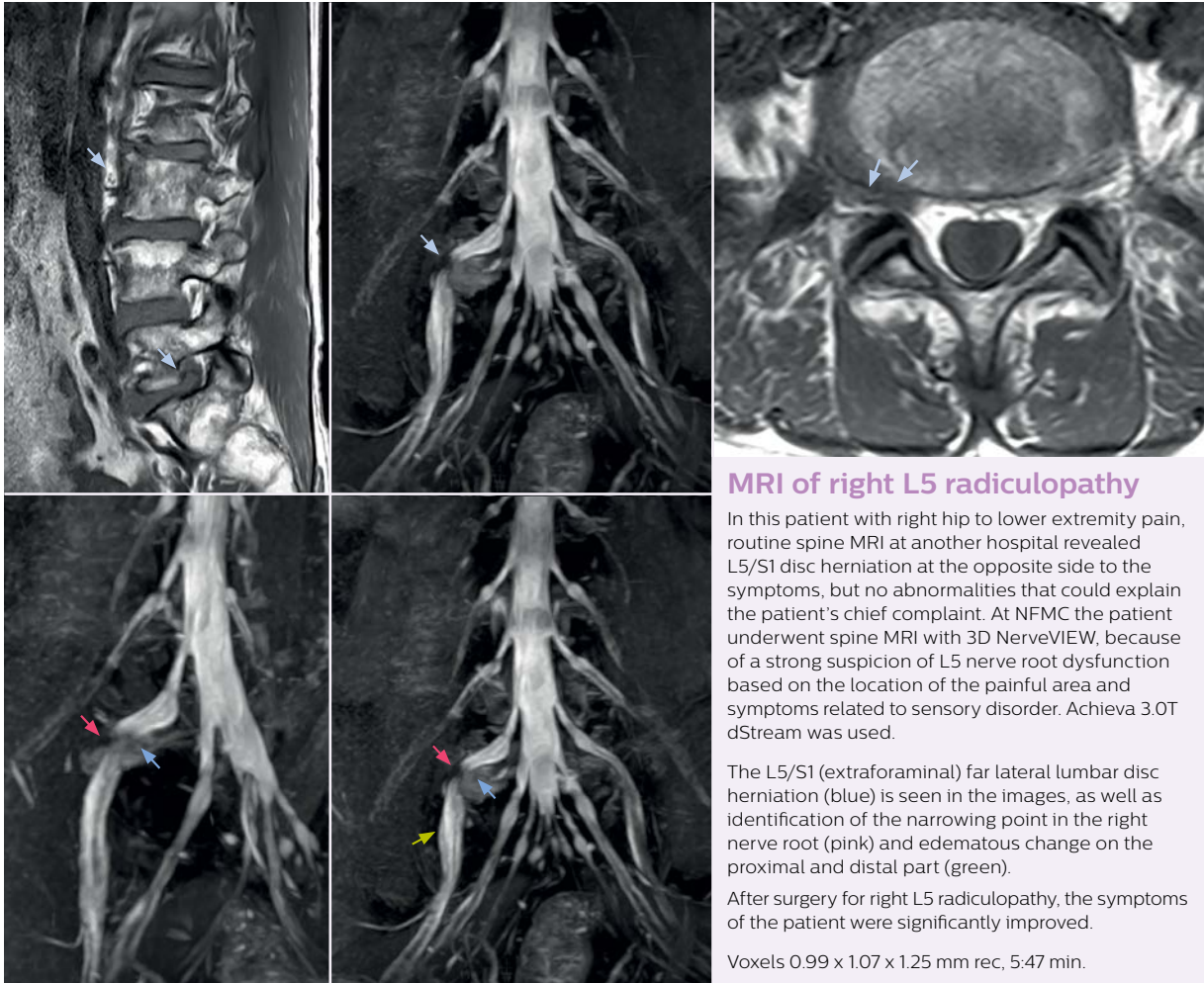
At Northern Fukushima Medical Center in Japan, excellent MRI visualization of nerves helps support confident diagnoses and informs surgical treatment decisions for patients with lower limb symptoms. MRI technologist Tanji and orthopedic surgeon Dr. Yabuki share how direct nerve visualization with the 3D NerveVIEW method adds information when diagnosing atypical herniations. The additional insights changed their way of working and benefit their patient care, as illustrated by some clinical examples. »

*“NerveVIEW helps us to determine the disease matching the symptoms by directly visualizing nerves”*



**Hajime Tanji, RT** is MRI technologist at Department of Radiological Technology, Imaging Center, Northern Fukushima Medical Center.

**Shoji Yabuki, MD, DMSc** is Professor at Department of Orthopaedic Surgery and Department of Pain Medicine, Fukushima Medical University School of Medicine.



### MRI of right L5 radiculopathy

In this patient with right hip to lower extremity pain, routine spine MRI at another hospital revealed L5/S1 disc herniation at the opposite side to the symptoms, but no abnormalities that could explain the patient's chief complaint. At NFMC the patient underwent spine MRI with 3D NerveVIEW, because of a strong suspicion of L5 nerve root dysfunction based on the location of the painful area and symptoms related to sensory disorder. Achieva 3.0T dStream was used.

The L5/S1 (extraforaminal) far lateral lumbar disc herniation (blue) is seen in the images, as well as identification of the narrowing point in the right nerve root (pink) and edematous change on the proximal and distal part (green).

After surgery for right L5 radiculopathy, the symptoms of the patient were significantly improved.

Voxels 0.99 x 1.07 x 1.25 mm rec, 5:47 min.

### NerveVIEW may help when other sequences are inconclusive

Northern Fukushima Medical Center (NFMC) Imaging Center uses the 3D NerveVIEW sequence for performing MR neurography, particularly in patients with pain and weakness in the lower limb. "It is included in about 20% of the approximately 150 lumbar spine MRI exams each month at NFMC, and can help us to determine if structures are impinging on the nerves," says Hajime Tanji, RT, MRI technologist at NFMC.

"In patients with lower extremity neurological symptoms, NerveVIEW helps us to determine the disease matching the patient's symptoms by directly visualizing the nerves. We use the sequence mainly, when there is suspicion of intraforaminal stenosis, extraforaminal stenosis or lateral disc herniation, which is often based on routine T2- and T1-weighted images. Additionally, the excellent depiction of the course of nerves makes NerveVIEW a good navigator when applying treatment such as block therapy or surgery."

***"NerveVIEW can clearly show nerve courses and nerve compression"***

### A useful addition from surgeon's perspective

"Before NerveVIEW, diagnosis by MRI alone was sometimes difficult, unless there was a strong suspicion based on clinical symptoms," says Shoji Yabuki, MD, DMSc, Orthopedic surgeon at Fukushima Medical University School of Medicine. "This is why we routinely perform selective lumbosacral radiculography (nerve root block) and x-ray in such cases. However, radiculography can only depict nerves as far as the contrast agent reaches. When a nerve is distorted by compression, the contrast agent will not pass through this compressed area, preventing us from evaluating the full nerve compression."

"In such case, we would then browse through axial T2-weighted MR images slice by slice and mentally reconstruct the actual situation based on both radiculography and MRI. Fortunately, NerveVIEW can now very well show nerve courses and presence of nerve compression or edema in one single image series."

"We have often seen NerveVIEW directly depict details of the nerve compression that were not observed by radiculography. Therefore, we think that with NerveVIEW we can reduce the number of invasive examinations, especially for some patients with lumbar plexus symptoms." >>



*“Because NerveVIEW helps us identify the actual hernia site, it can inform selection of the surgical approach”*

### NerveVIEW shows right L5 radiculopathy and informs surgery

Low-grade glioma in a child with neurofibromatosis 1. This low-grade lesion does not enhance on the post-contrast images, but does show an intermediate APT signal. The lesion stability over time confirms that it is a low-grade pathology.

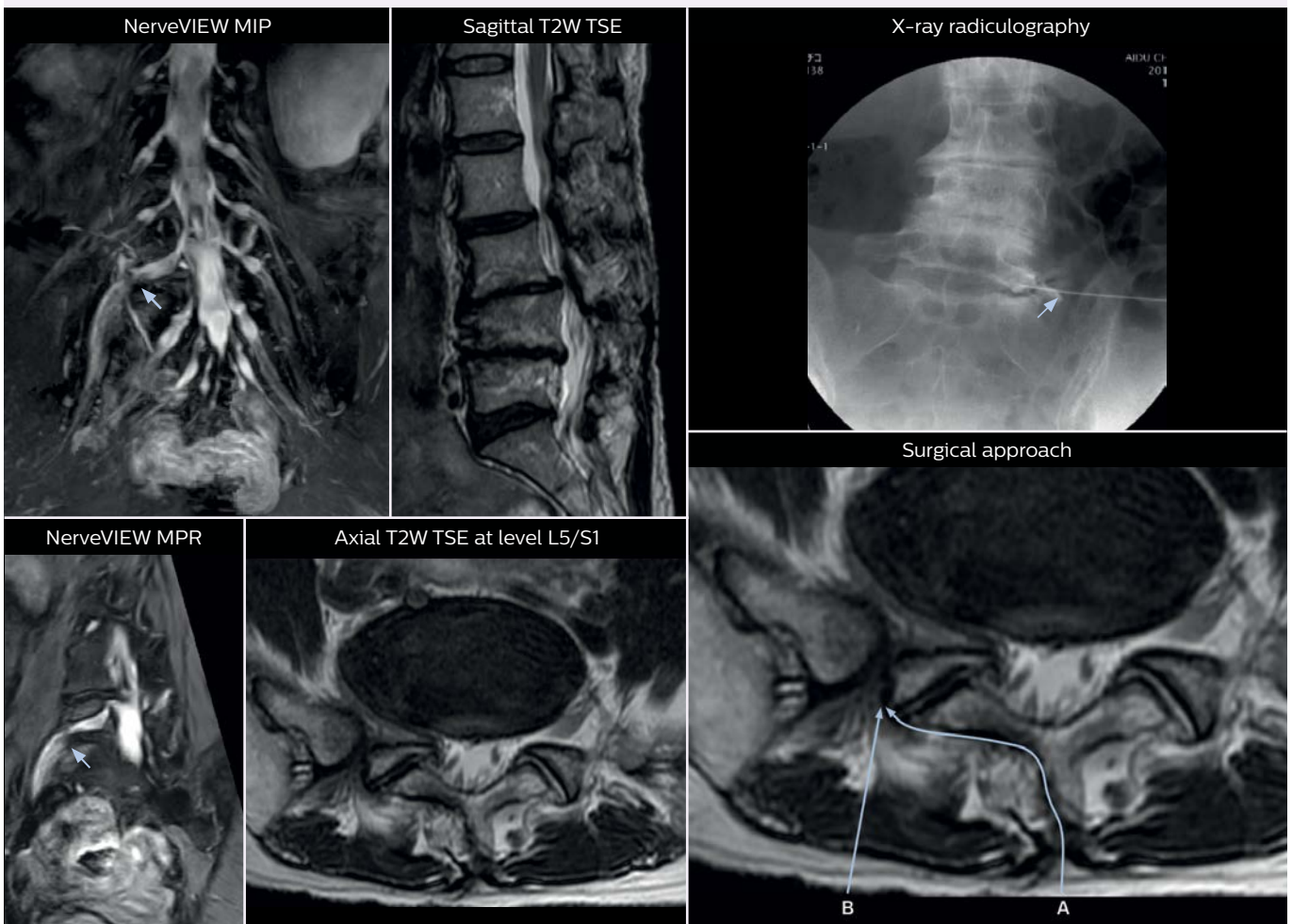
No abnormal findings were seen on routine MRI. Then x-ray radiculography was performed, but the contrast agent became trapped in transit and the nerve could not be fully observed. The peripheral nerve root is not contrasted in the nerve root block (x-ray radiculography) at the suspected location.

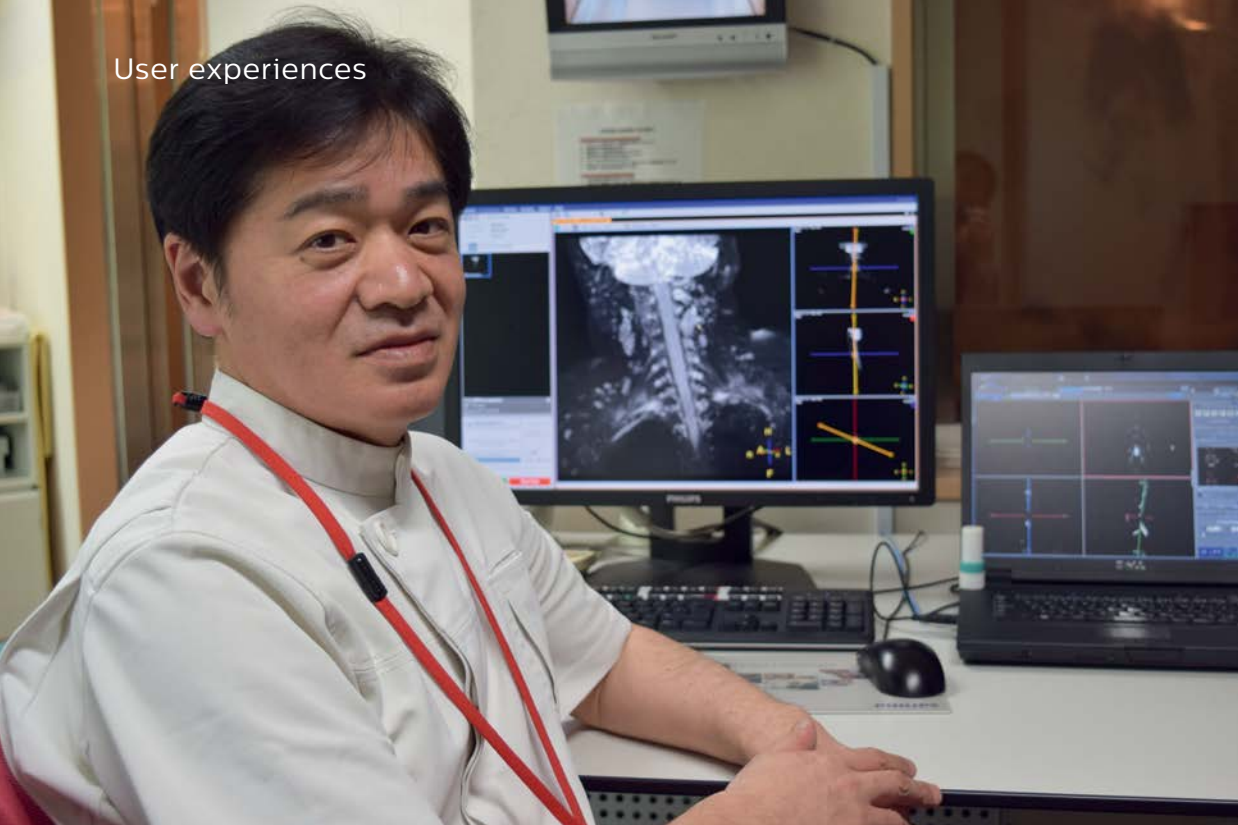
NerveVIEW images show that the spinal nerve is discontinued at the periphery of the dorsal root ganglion of the right L5 nerve root, suggesting nerve compression there. No other findings could explain the symptoms. With a diagnosis of extraforaminal herniation, surgery was performed.

Based on the findings using NerveVIEW, the surgeon decided to perform a hernia resection with a different, less invasive surgical approach from the outside of the multifidus muscle (B) instead of the usual approach (A). During surgery, disc herniation outside the intervertebral foramina was confirmed. Hernia resection released pressure on the nerve root and the right lower limb pain disappeared.

#### Impact of 3D NerveVIEW in this case

MRI on Achieva 3.0T dStream with NerveVIEW shows compression of nerve root outside the right L5/S1. Because NerveVIEW helped to accurately identify the location of the causative disease, a surgical approach could be chosen that prevented the need to peel off the muscle unnecessarily.



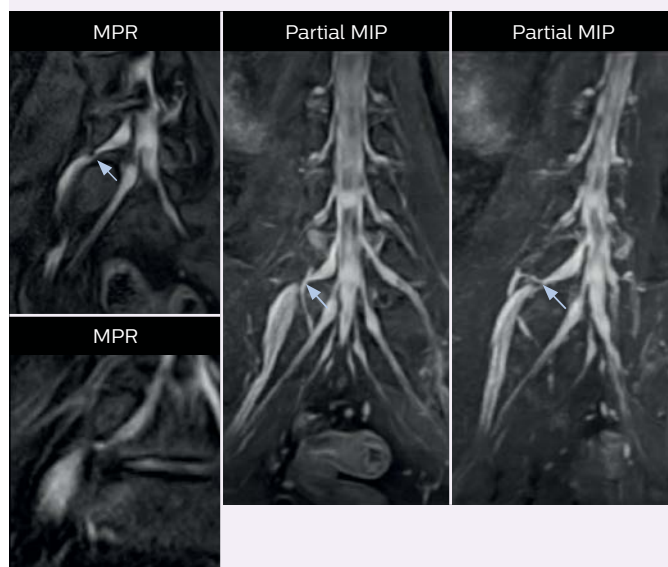


*“The sequence facilitates diagnosis of lower extremity pain and informs our decision-making regarding therapy and surgery”*

### NerveVIEW imaging of right L5 radiculopathy

After a previous successful surgical operation to treat a lumbar disk hernia, this patient still had strong numbness from right hip to the lower extremity. The patient then underwent MRI with 3D NerveVIEW on Achieva 3.0T dStream. NerveVIEW voxels 0.99 x 1.07 x 1.25 mm rec, 5:47 min.

These NerveVIEW images helped to identify the cause of pain, being L5/S1 (extraforaminal) far lateral lumbar disc herniation. Based on these findings, the patient underwent a second surgery, after which symptoms significantly improved.



### Direct imaging of nerves aid diagnosis

The key concept in MR neurography, Dr. Yabuki stresses, is the ability to directly visualize spinal nerves, versus inferring the presence of pathology indirectly. “Before NerveVIEW, we estimated compression of the nerve by looking for the presence or absence of fat signal on other MR images,” he says.

“For example, in sagittal images, when the presence of fat is observed in the intervertebral foramen, it suggests that there is a margin around the nerve. Similarly, the absence of fat indicates that the nerve is being compressed. So, we used to deduce nerve compression indirectly. With NerveVIEW, however, we can observe the condition of the nerves directly, regardless of the presence or absence of fat. We always prefer such direct observation of anatomy over having to make an inference about it.”

### Distinguishing typical from atypical herniation informs the surgeon

“NerveVIEW is really useful for those cases where a nerve disorder is strongly suspected based on the clinical examination but our regular MRI images do not show any findings. These atypical herniations and spinal canal stenosis, occurring in 5% to 15% of the total lumbar herniation/stenosis cases are our main target when using NerveVIEW,” says Dr. Yabuki.

“Although symptoms of typical disc herniation and atypical hernia are very similar, the actual site of herniation is different. It is therefore important to characterize the nerve’s condition both inside and outside of the intervertebral foramina.

“Conversely, if we see no abnormality in NerveVIEW, we can assume at least that there is no severe condition that requires surgery. Like this, it can help us avoid unnecessary surgery. NerveVIEW can have a tremendous impact in this way.”

### Why 3D NerveVIEW is highly appreciated at NFMC

According to Tanji, methods such as ProSet FFE, STIR or 3D VISTA are anatomically nonselective because background signals, for instance from blood vessels, often interfere with nerves, which hampers evaluation of details, especially at the peripheral side of the nerves.

“The intra-luminal signal of veins, especially around the intervertebral space, can be suppressed well with NerveVIEW. As a result, we can easily observe the detailed nerve structure around the posterior ganglion,” he says. “This is why we use 3D NerveVIEW for intraforaminal stenosis and extraforaminal stenosis/herniation (lateral disc herniation). On the other hand, if herniation is suspected to exist inside the dorsal root ganglion (DRG), balanced TFE or ProSet-FFE is applied. NerveVIEW is not suitable for evaluating the median type of herniation.”

The SE-EPI DWI-based method for MR neurography works well for large FOV exams like whole-body MRI, but focal examination of nerves is often limited by the attainable spatial resolution (both in-plane and slice direction) and geometric distortion. “3D NerveVIEW achieves higher in-plane resolution – close to our other routine spine sequences – and the source images can be used instead of adding a fat-suppressed T2-weighted sequence,” Tanji says. >>

### 3D NerveVIEW for lumbar spine Protocol of NFMC

FOV 230 mm  
 Voxels 0.99 x 1.07 x 2.5 (1.25) mm  
 50 (100) slices  
 dS SENSE factor 2.0  
 Scan time 5:17 min.

### Postprocessing:

Because the obtained NerveVIEW images often exhibit a high signal in the intervertebral discs, we use partial MIP images to eliminate such intervertebral disc high signals. MIP image generation is based on the center of the coronal stack, and RAO (right anterior oblique) and LAO (left anterior oblique) images rotated in the range of 45 degrees are used for diagnosis.

### Left sacroiliac arthritis

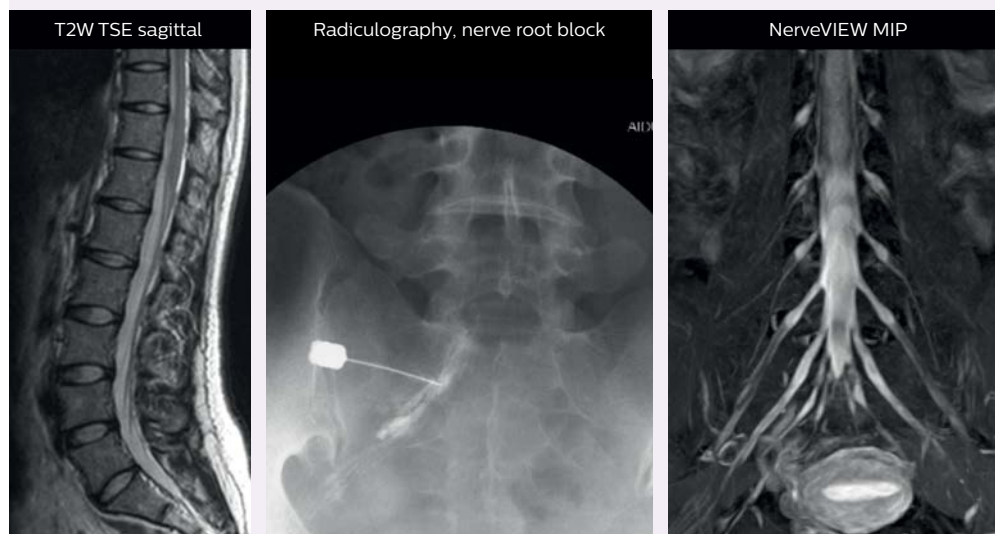
In this patient with left hip pain as main complaint, a combination of left sacroiliac arthritis and left S1 radiculopathy was considered. Pain temporarily improved by the left S1 nerve root block, so nerve root disease was suspected to be the cause.

There were no obvious findings in routine MRI on Achieva 3.0T dStream. With 3D NerveVIEW imaging, the left S1 nerve root is well visualized from proximal to distal. However, no abnormality seen in the nerve root, so pain is not due to radiculopathy. Diagnosis is sacroiliac arthritis.

### Impact of 3D NerveVIEW

Pain due to nerve injury and arthritis can show similar symptoms. Since part of this patient’s pain is in the sacroiliac joint, the pain ceased when a root block was done, but often recurred, so the patient underwent many block treatments. Finally, the entire nerve was well depicted with NerveVIEW, and no significant abnormalities were observed. In conclusion, the nerve root block relieved pain only by blocking the place to convey the pain, and the actual cause was not there. This case illustrates that NerveVIEW can be useful not only in identifying lesions but also for ruling out lesions.

*“3D NerveVIEW achieves high resolution and we use its source images instead of adding fat-suppressed T2W”*



### Good spatial resolution is required

“For both brachial and lumbar plexus, we are currently using a 230 mm FOV and voxels of about 1 x 1 x 2 mm acquired (1 x 1 x 1 mm reconstructed). This provides us a good representation of the nerves, even though this FOV is relatively small. Regarding the in-plane resolution, we hope to be able to bring that down to 0.7 mm, similar to our typical 2D multislice T2W images,” says Tanji.

“Recently, the two surgical methods extreme and oblique lateral interbody fusion (XLIF and OLIF) have become mainstream for minimally invasive treatment of lumbar spinal canal stenosis and intervertebral foramen stenosis. With these surgical techniques, the spine is approached from the flank, and prior knowledge of the exact anatomy of the lumbosacral plexus would be extremely helpful. To that end, high slice resolution (less than 1 mm acquisition) that enables sharper sagittal MPR images will be needed.”

### Implementing NerveVIEW without lengthening exam time

“The source images of NerveVIEW exhibit a contrast similar to STIR or fat-suppressed T2-weighted images. So, in our neurography exams we are replacing the 2D T2-weighted coronal sequence with 3D NerveVIEW. With this, we add a

lot of useful information without adding scan time. This is important for patients with severe lower extremity symptoms, as they often find it difficult to maintain still during the whole MRI examination, so the exam should be as short as possible.”

“We have currently implemented 3D NerveVIEW on our Achieva 3.0T dStream MRI system only. Because the 3D NerveVIEW method is based on a background signal suppression technique, we decided to use the high SNR of our 3.0T MRI system for obtaining the best possible visualization of peripheral nerves,” says Tanji.

#### Lumbar spine MRI examinations at NFMC

##### Lumbar spine with 3D NerveVIEW

T2W sagittal and axial  
T1W sagittal and axial  
3D NerveVIEW

##### Routine lumbar spine (without neurography)

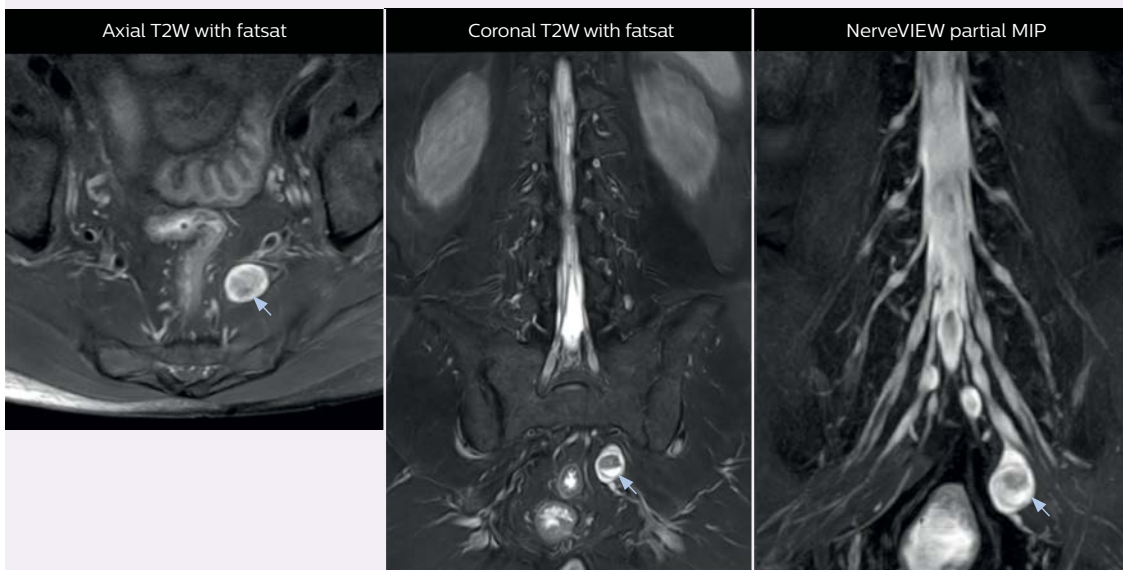
T2W sagittal and axial  
T1W sagittal and axial  
Fat suppressed T2W coronal

### Peripheral nerve sheath tumor (schwannoma)

This patient presented with right lower back pain. Both fat suppressed T2-weighted axial and coronal images show the tumor, but the relationship between nerves is unknown. NerveVIEW imaging shows the relationship between tumor spread and nerve.

Previously, a positional relationship with a tumor was assessed from axial images, but now the course can be assessed more continuously on a coronal NerveVIEW MIP. Achieva 3.0T dStream was used.

A nerve sheath tumor is usually removed by cutting only the tumor’s capsule without cutting the nerve itself. However, a tumor emerging from the nerve fiber itself cannot be removed unless the corresponding nerve is also excised. If a tumor-nerve connection can be successfully visualized, making a diagnosis and choosing the optimal surgical approach may be possible without performing a biopsy.



Voxels 1 x 1 x 2 mm, 5:47 min.



### ***“This is important for patients with severe lower extremity symptoms”***

“Where NerveVIEW of the lumbar plexus is currently used as a subroutine scan for patients with strong lower limb symptoms, its use for visualization of the brachial plexus, is currently limited to special cases such as schwannomas and neuritis, usually only 1 or 2 cases per month.”

#### **Building confidence with NerveVIEW**

“NerveVIEW can clearly show nerve courses and presence of nerve compression. However, when multiple abnormalities are seen, it can still be hard to determine which nerve is causing the symptoms,” says Dr. Yabuki. “In our experience so far, we see abnormal findings on NerveVIEW in about 70% of elderly patients. As the pain is usually caused by only one nerve, we thus need to find the exact corresponding nerve.”

“With a nerve root block, the patient’s pain is improved by infiltration of local anesthesia directly around the nerve root considered to be responsible. Knowing such nerve root block findings prior to image interpretation, helps to easily recognize

abnormal findings on NerveVIEW as well. In other words, without a priori knowledge, based on symptoms and/or nerve root block findings, we must be aware of the possibility of overdiagnosis.”

#### **MR neurography attracts referrals at NFMC**

The addition of the nerve-selective NerveVIEW sequence to its spine MRI protocol has given NFMC competitive advantages, according to Tanji. “Since we started including NerveVIEW routinely, the demand for lumbar spine MRI examinations has increased, especially for pre-surgical planning purposes and for patients with chronic lower extremity symptoms,” he says.

“Moreover, because no other hospitals in our region are doing nerve plexus imaging yet, we often receive referrals for MR neurography studies from other hospitals even if they have an MRI scanner. Some requests come from as far as 100 km away. NerveVIEW definitely provides us a competitive advantage.”

“Based on our experience, we can certainly recommend NerveVIEW to other centers,” Dr. Yabuki adds. “The sequence opens up many possibilities to facilitate the diagnosis of lower extremity pain and to inform our decision-making regarding therapy and surgery.” <<

# Always up-to-date MRI at predictable, reduced cost

**Eliseo Vaño Galván, MD**

Cardiovascular radiologist, Chairman of the CT & MR Department at Hospital Nuestra Señora del Rosario and collaborating professor of Complutense University of Madrid. Dr. Vaño is board member of the Spanish Society for Cardiothoracic imaging and member of a subcommittee for the 2020 Spanish National Radiology Congress.

*“It was consistently a challenge to plan for annual upgrades and predict their costs”*

**“Technology Maximizer  
makes our lives easier”**

## **Madrid hospital saves cost and keeps MRI systems updated with flat 4-year Technology Maximizer budget**

Clinicians at Madrid’s Hospital Nuestra Señora del Rosario (HSNR Madrid) take pride in their ability to offer patients the best possible MRI scans. Keeping their three Philips MRI systems up-to-date with the latest hardware and software upgrades has helped the department maintain its reputation as a leader in MRI service quality.

However, acquiring timely upgrades hasn’t always been easy due to HSNR Madrid’s annual budgeting progress. The required amount varies per year, which made it difficult to pass the budget through hospital administration. The situation has improved now that the department has taken advantage of Technology Maximizer, a Philips program for cost-effective upgrading of imaging systems through the operational budget over a four-year period.

### **Technology upgrades, on time and on budget**

Professor Eliseo Vañó Galván, MD, and his colleagues at HNSR Madrid have had a keen interest in keeping their Ingenia 3.0T, Ingenia 1.5T and Achieva 1.5T MRI systems at the cutting edge. Regularly upgrading their Philips MRI hardware and software allows them to continually offer the most current diagnostic and operational capabilities.

“When we make an important investment such as the acquisition of a new MRI system, we want to make sure that it will continuously be updated,” Dr. Vañó says. “For us, the most important thing is the quality of the service we provide to patients and referrers. Having the latest technology certainly helps us to do so, but it was consistently a challenge to plan for annual upgrades and predict their costs.”

This difficulty in forecasting costs of periodic upgrades and newly released innovations for MRI makes precise budgeting and investment planning immensely difficult for the department and for the hospital. “This issue caused a lot of distress in the past,” he adds.

With the service program Technology Maximizer, Philips offered HNSR Madrid a way to avoid yearly budget hassles by providing predictability in upgrade costs over multiple years. This allows

the department to maintain a leading position with a high level of performance capabilities, through timely upgrades of their MRI systems.

### **Convenient, hassle-free upgrade schedule**

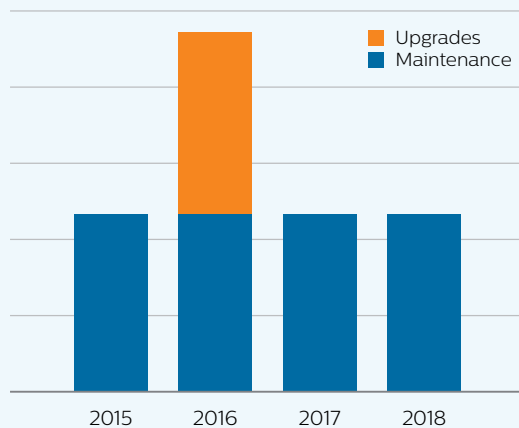
During the period 2015–2018, the yearly upgrade expenses for MRI systems fluctuated significantly in the CT & MR Department at HSNR Madrid, and upgrades could not be implemented every year.

Then in 2018, the department adopted Technology Maximizer for its three MRI systems as well as for its IntelliSpace clinical review and analysis portal. With Technology Maximizer, the budget for 2019–2022 calls for equal yearly expenditures (i.e., fee) for the contract period and more regular upgrades. The diagrams below compare total cost for all three MRI systems.

Note, also, that under the Technology Maximizer contract, the department will save more than 80,000 Euros compared to the previous four-year period.

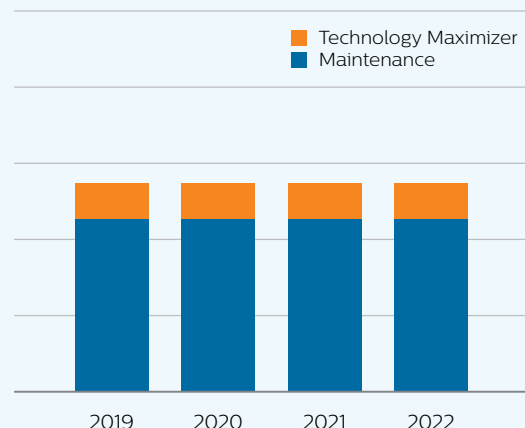
Since entering into the Technology Maximizer service program, Dr. Vañó’s concerns about planning and budgeting for MRI upgrades have virtually evaporated. >>

### Cost of maintenance and upgrades in previous years



- Large variation in annual cost
- Upgrading once in 4 years

### Cost of maintenance and upgrades with Technology Maximizer program



- ✓ Fixed annual cost
- ✓ Yearly updating

“Clearly, the biggest advantage that Technology Maximizer brings us is cost efficiency and better predictability,” he says. “It allows us to continually stay up-to-date while saving costs. Instead of having to constantly plan for it, the budget for technological updates is now well defined for the next four years. All of the MR systems’ updates are included, which means we can potentially save money that we can use later on for reinvesting in new technology.”

### Harmonized user interfaces ease operational processes

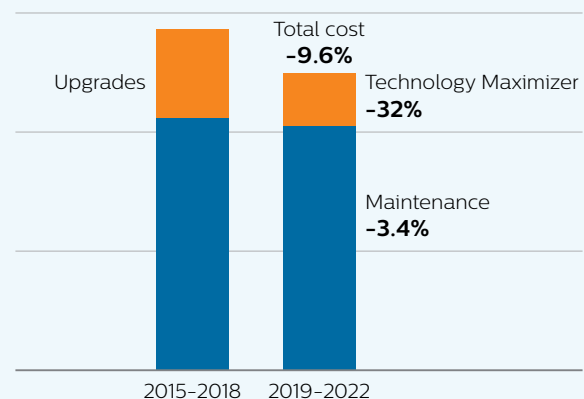
Having all three MRI systems updated to the latest release also benefits the department’s operational processes, according to Dr. Vaňó.

“When we acquired our newest MRI system, we updated all our MRI systems to the latest software release and this effectively standardized the user interfaces of all operator’s consoles,” he says. “We then saw an enormous impact on the learning curve; there was practically none – our technologists could begin operating immediately. Instead of going through a progressive learning curve of two or three weeks, we began operating at 90 to 100 percent the next day.”

**“Clearly, the biggest advantage that Technology Maximizer brings us is cost efficiency and better predictability”**

**“It gives us the confidence that we’re offering patients the best services we can at all times”**

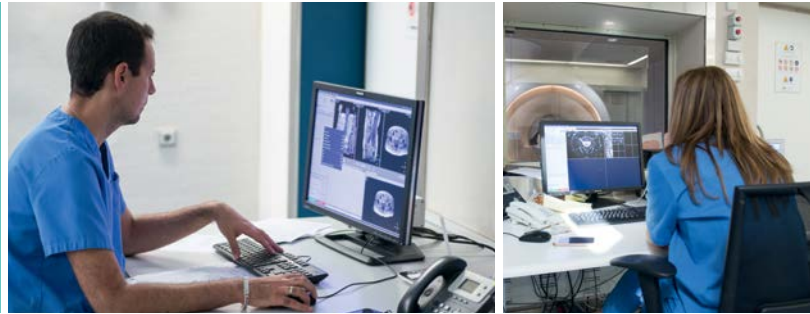### Reduction in accumulated cost of maintenance and upgrades over 4 years Before vs with Technology Maximizer



- ✓ Technology Maximizer saves cost and provides more frequent updates



*“All three MRI systems are easy to manage because we can cut-and-paste protocols in all of them”*



“Thanks to Technology Maximizer, we now know we can continue to have the latest versions of software for all of our MRI systems. As a result, our technologists will find a consistent user interface regardless of which system they’re operating. All three MRI systems are easy to manage because we can cut-and-paste protocols in all of them. And when technologists shift from one MRI to another, they can’t tell the difference – if a technologist can operate one system, he or she can use them all.”

prestige, but in the end, it also impacts patients and how they’re treated. We believe that having the latest innovations continuously at our disposal, most certainly brings more patients to the hospital.”

“By streamlining the upgrade planning and budgeting process and maintaining our systems at the highest technological level, as well as standardizing the systems for easy use, Technology Maximizer makes our lives easier.” <<

### Streamlined budget planning to keep systems up-to-date

Technology Maximizer also supports the imaging department’s goals and mission, as timely system updates relate to the quality of patient care and department performance, Dr. Vañó says.

“With the Technology Maximizer program, we benefit from improvements immediately with each successive update. This gives us the confidence that we always have state-of-the-art technology and that we can offer patients the best services we can at all times. We establish productivity goals in our department such as throughput and scan times. If there are no exceptional circumstances, those goals are met.”

“Within our reach are the most recently released advanced tools that allow us to deliver well-presented and clear information to referring specialists. It’s a source of pride and

### Benefits that HNSR Madrid notes for Technology Maximizer:

- Maintaining state-of-the-art technology
- Overall cost savings for upgrades
- Predictable cost up to four years ahead
- Staying current without annual budget hassle
- Continually able to improve workflow with latest features
- Able to offer state-of-the-art MRI to patients and referrers
- Staying up-to-date helps attract patients

## Technology Maximizer provides fixed fee-based upgrades

A program that runs in tandem with the Philips RightFit Customer Service Agreement\*, Technology Maximizer offers Philips equipment users the latest available software and hardware releases for a fraction of the cost of purchasing them individually. For an annual subscription fee over a four-year period, Technology Maximizer allows facilities to update all Philips imaging systems to the same release level\*\*, reducing operational complexity and simplifying lifecycle management.

### Technology Maximizer: Stay clinically advanced, maximize imaging investments



Stay clinically advanced to maximize the value of the investments and be first to market innovations.

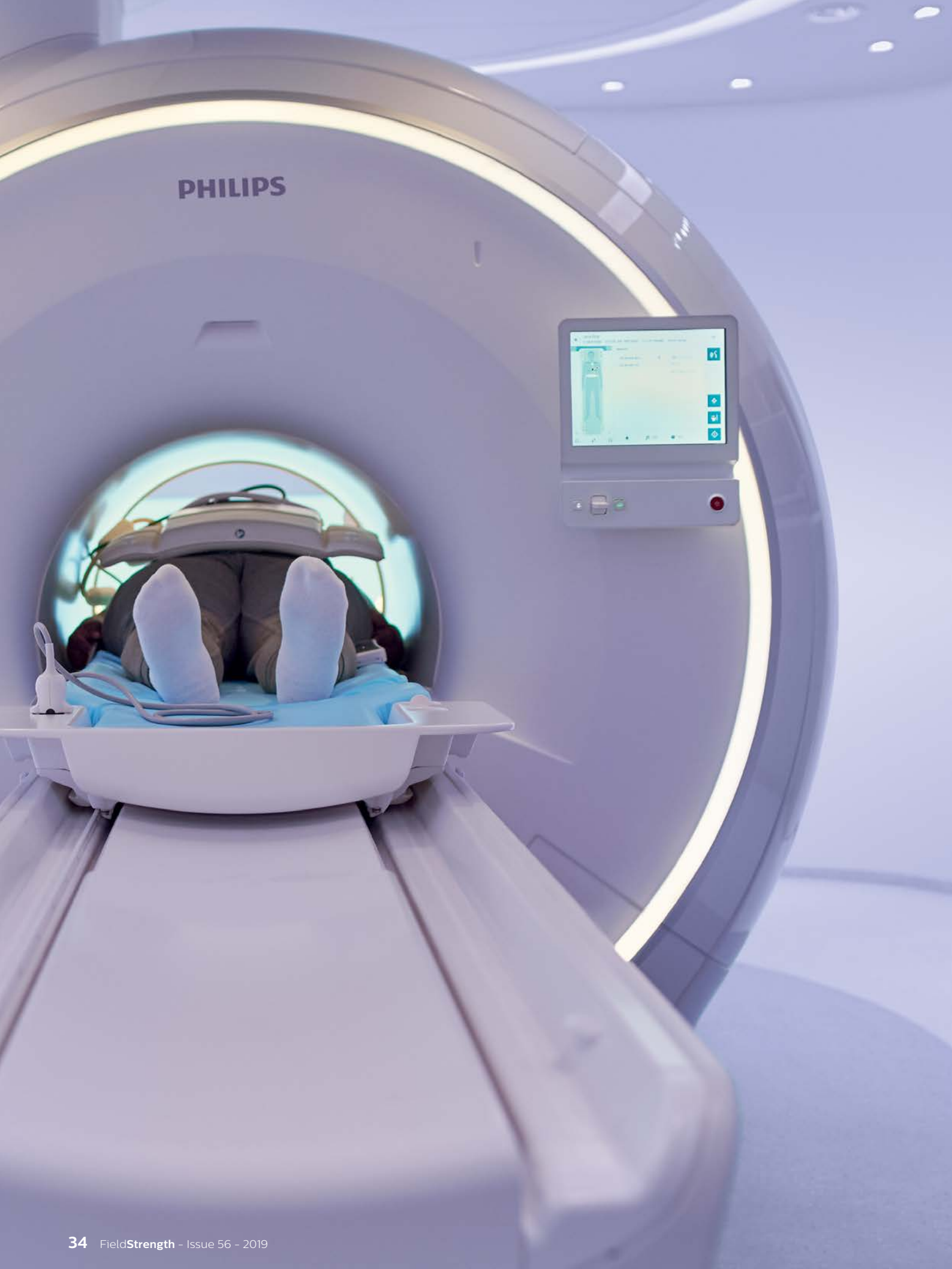

Be predictable in your costs while keeping your systems up to date.

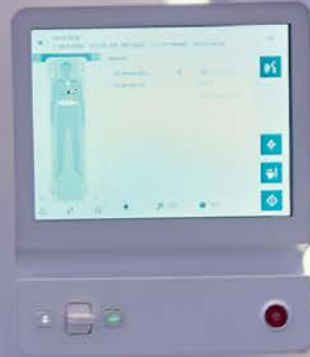

Keep your imaging systems secure and stay protected from obsolescence.

\* Eligible RightFit service agreements are available with Maximizer depending on the region.  
 \*\* Eligible release level depends on system configuration and region.



PHILIPS



# Stay in touch

## with Philips MRI

FieldStrength is a professional magazine for users of Philips MR systems. It provides results of MR studies performed by Philips users.

### Don't miss an issue

Read more articles or register for your personal email subscription at: [www.philips.com/fieldstrength](http://www.philips.com/fieldstrength)

#### You may also be interested in:

- NetForum to find or share case studies, ExamCards and best practices, see [www.philips.com/netforum](http://www.philips.com/netforum)
- MR body map to view clinical cases of nearly every anatomy, see [www.philips.com/mrbodymap](http://www.philips.com/mrbodymap)
- Philips MRI products, see [www.philips.com/mri](http://www.philips.com/mri)

#### © Royal Philips N.V. 2019

All rights are reserved. Reproduction in whole or in part is prohibited without the prior written consent of the copyright holder.

Philips Healthcare reserves the right to make changes in specifications and/or to discontinue any product at any time without notice or obligation and will not be liable for any consequences resulting from the use of this publication.

Printed in Belgium.  
4522 991 47381

FieldStrength is also available online:  
[www.philips.com/fieldstrength](http://www.philips.com/fieldstrength)  
[www.philips.com/mri](http://www.philips.com/mri)  
[www.philips.com/netforum](http://www.philips.com/netforum)

#### Editor-in-chief

Karen Janssen

#### Contributors

Megan Breuer (PhD), Paulo de Miranda, Jerry Duncan, Julia Dupuis, Catia Sofia Fernandes, Sachi Fukushima, Karen Janssen, Jani Keyriläinen (PhD), Takashi Koyama (MD, PhD), Hideki Koyasu (MD), Masayuki Kumashiro (PhD), Heikki Minn (MD, PhD), Koshi Miyake (MD), Arjen Radder, Katsuhiko Shiba, Atsushi Takemura, Hajime Tanji, Marieke van Grootel, Eliseo Vañó Galván (MD), Shoji Yabuki (MD, DMSc), Masami Yoneyama.

#### Subscriptions

Please subscribe on [www.philips.com/fieldstrength](http://www.philips.com/fieldstrength)

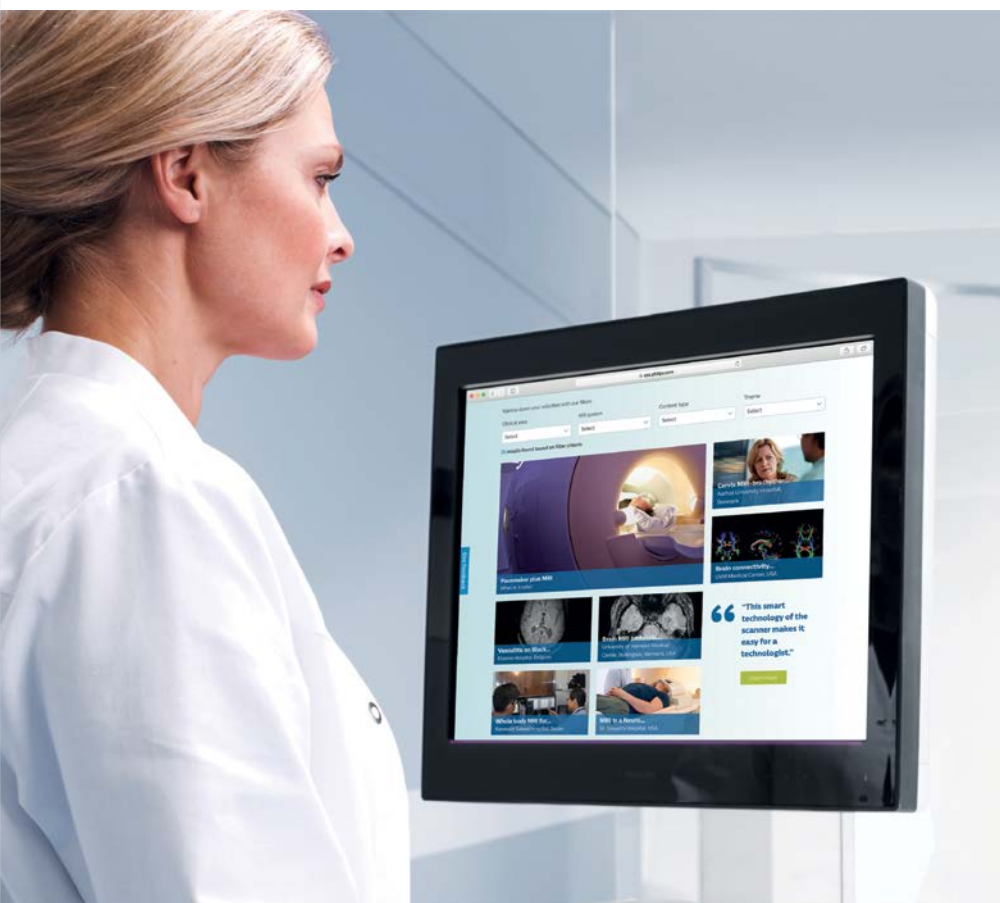
#### Correspondence

FieldStrength@philips.com or  
FieldStrength, Philips Healthcare, Building QR 0119  
P.O. Box 10 000, 5680 DA Best, The Netherlands

#### Notice

FieldStrength is created for users of Philips MRI systems. It is a professional magazine for users of Philips medical equipment. It provides the healthcare community with results of studies performed by colleagues. Some articles in this magazine may describe research conducted outside the USA on equipment not yet available for commercial distribution in the USA. Some products referenced may not be licensed for sale in Canada.

Results from case studies are not predictive of results in other cases. Results in other cases may vary. Results obtained by facilities described in this issue may not be typical for all facilities. Images that are not part of User experiences articles and that are not labeled otherwise are created by Philips.



# PHILIPS

Magnetic Resonance



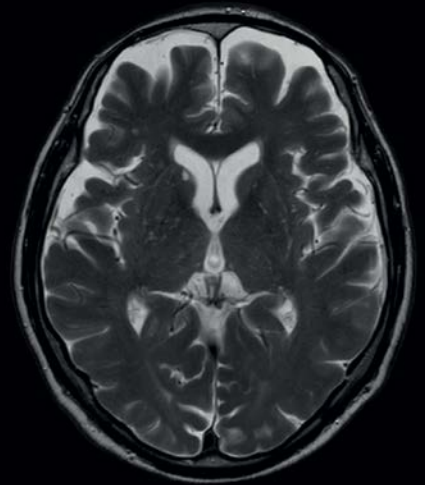
## Speed done right, **every time.**

In a society where reimbursements are declining and chronic conditions lead to increased MR procedures and longer waiting times, there is ever increasing pressure on the radiology department.

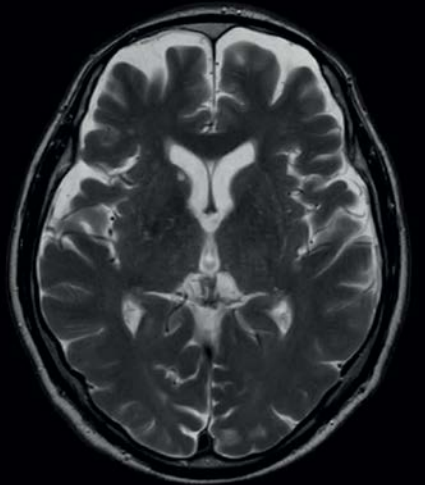
This is why Philips brings Compressed SENSE, a breakthrough in productivity. Compressed SENSE is not only about faster sequences, it is much more. It is about accelerating full patient examinations and thus guaranteeing the next level in productivity and image quality to empower your staff to focus where it matters the most, enhanced patient care.

innovation  you

Discover our latest innovations at  
[www.philips.com/thenextmrwave](http://www.philips.com/thenextmrwave)



T2w TSE without Compressed SENSE  
0.6 x 0.7 x 5.0 mm, 2:04 min



T2w TSE with Compressed SENSE  
0.6 x 0.7 x 5.0 mm, C-SENSE 3.2, 1:04 min