

**PHILIPS**

MRI Magazine

# FieldStrength

## The next MR wave

**Ingenia Elition X**, a breakthrough in diagnostic quality and speed

**Faster MRI** throughout the body with Compressed SENSE

Enhancing **brain tumor MRI** with APT weighted imaging



## Dear Friends,

*As we continue our journey to touch more lives with MR in 2018, we are at a defining moment for our industry. Healthcare reforms around the world drive towards a reduction of healthcare spend while at the same time a demand for better care. This imposes challenges for the work we do, but also offers great opportunities to make a bigger impact with MR.*

*Making a bigger impact will require a mind-shift to unlock the potential of MR. Starting with the patient in everything we do and focusing our solutions to provide a simpler, faster and smarter path to a confident diagnosis is what I believe will enable us to touch more lives. All of this in collaboration with you.*

*This is exactly why we are on a journey to bring a new, forward looking, patient centric MR portfolio to market which is introduced under the name #TheNextMRWave. In this edition of FieldStrength you can read how these new solutions help impact patient care.*

*If you are interested in productivity, I recommend you to read the experiences of Kantonsspital Winterthur with Philips Compressed SENSE. A revolution in MR throughput, throughout the whole body, making a direct impact on cost. And with a focus on the patient we have some great examples of impacting the patient experience with our in-bore experience. As well as how to address a growing patient population that is difficult to scan, patients with implants.*

*Enjoy reading and follow us on #TheNextMRWave, this is just the beginning and there is much more to come.*

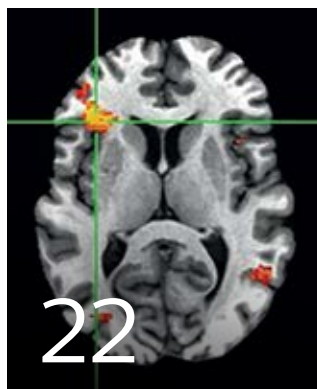
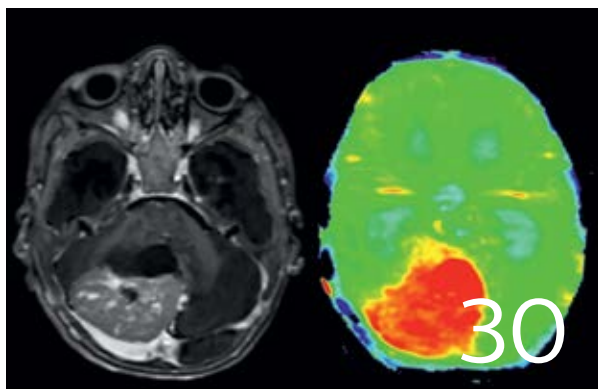
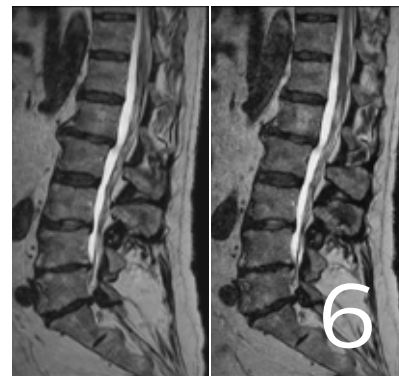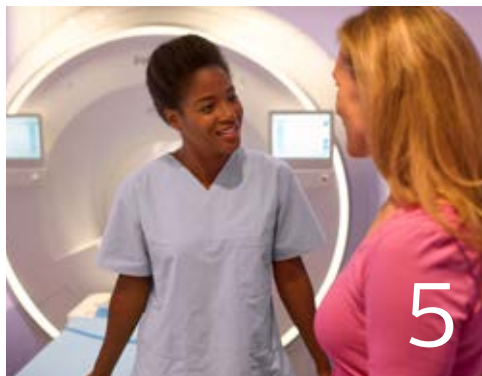**Martijn Hartjes**  
Senior Director & Head of Global Product Marketing MR, Philips Healthcare



**NetForum**  
[www.philips.com/netforum](http://www.philips.com/netforum)

Visit the NetForum online community to download ExamCards and view application tips, case studies, online training and more. Scan the QR code with your smartphone or use [www.philips.com/netforum](http://www.philips.com/netforum).

# The next MR wave



## News

**4 Philips introduces the next MR wave**

## User experiences

**6 Faster MRI throughout the whole body with Compressed SENSE**

Accelerating sequences one by one results in shorter exams.  
*Dr. Sartoretti, Kantonsspital Winterthur, Switzerland*

**10 MRI in-bore solutions: patients love it, departments thrive**

Centers see broad impact of enhancing the patient's experience in MRI.  
*MRI team Herlev Hospital, Denmark; Dr. Masuda, Chiba University Hospital, Japan; Dr. Kesseböhmer, Lübeck, Germany*

## Trends in MRI

**16 How to perform MRI of patients with MR Conditional cardiac devices**

MR Conditional pacemakers and ICDs should be no impediment for scanning patients.

*Dr. Sommer, German Red Cross Hospital; Dr. Shellock, University of Southern California; Dr. Schwitzer, CHUV Lausanne; Dr. Patel, University of Chicago Medicine.*

## Research

**22 MultiBand SENSE widens possibilities for fMRI and dMRI in brain**

Users see MultiBand SENSE advance their neuroscience studies.

*Steinberg (VCU, USA), Caan (AMC, Netherlands), Gispert (PMF, Barcelona, Spain), Watts, Garavan (UVM, USA)*

**30 Enhancing brain tumor MRI with APT weighted imaging**

Confidence in differentiating low and high grade brain tumors  
*Dr. Curran, Dr. Miller, Phoenix Children's Hospital, USA*

Results from case studies are not predictive of results in other cases. Results in other cases may vary. Results obtained by facilities described in this issue may not be typical for all facilities.

# Philips introduces the next MR wave

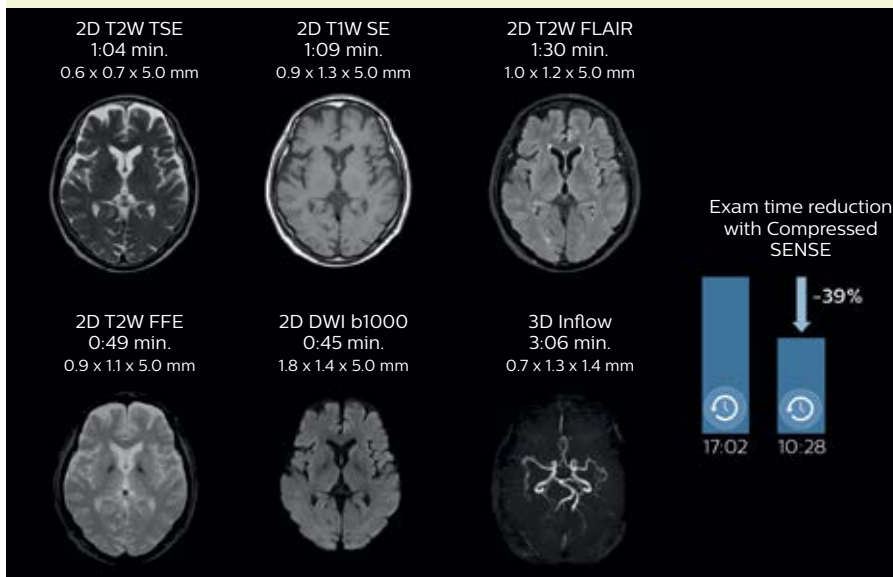
At Philips, we want to push the boundaries of healthcare and deliver seamless care while putting the patient first. Recognizing the challenges you are facing in radiology, we introduce a next wave in MR.

## Welcome to MR with a new point of view

Our next generation of innovations is built for a world where MR plays a greater role in delivering better care for your patients. In 2017 and 2018, we showcased several solutions that will help making this vision a reality. Our innovations are designed to help you achieve a confident diagnosis, keeping patient experience and care at the forefront. To find out more, visit [www.philips.com/TheNextMRWave](http://www.philips.com/TheNextMRWave)

### Compressed SENSE Speed done right, every time.

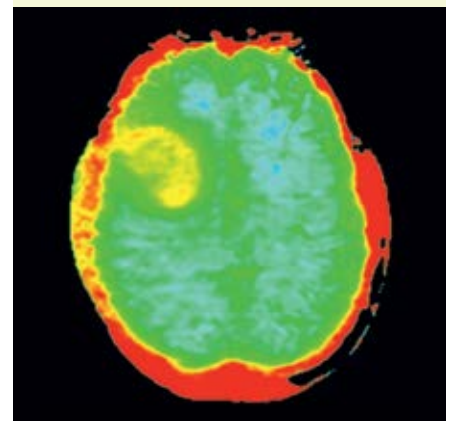
For radiology departments under pressure to perform more MR procedures and reduce waiting times, we developed Compressed SENSE, a massive data undersampling technique, that speeds up 2D and 3D sequences, across all body areas and for all anatomical contrasts. It can be applied to accelerate an entire patient examination. See also page 6.



**This accelerated brain examination with Compressed SENSE takes only 10:28 minutes.** Before, without Compressed SENSE, the same examination needed 17:02 minutes. Courtesy of Kumamoto Chuo Hospital, Japan, Ingenia 3.0T.

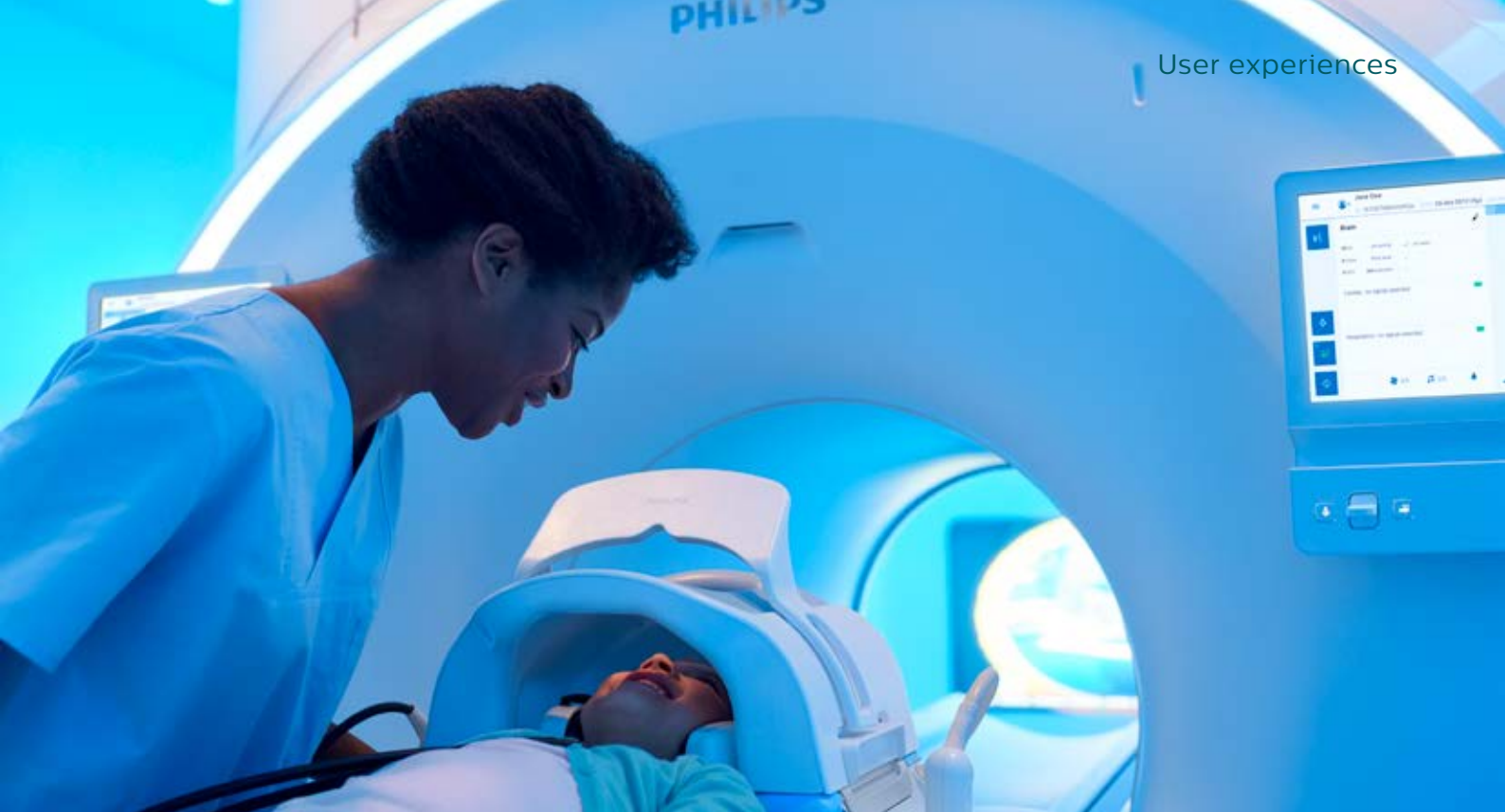### 3D APT Enhanced diagnostic confidence in neuro oncology

3D APT (Amide Proton Transfer) is our contrast-free MR technique that addresses a need for more confident diagnosis in neuro-oncology. It makes use of endogenous cellular proteins to produce an MR signal that directly correlates with cell proliferation, a valuable marker in neuro oncology. Read more on page 34.



**3D APT of brain tumor.** Courtesy of Krankenhaus der Barmherzigen Brüder, Trier, Germany.





# Ingenia Elition X

## A revolutionary breakthrough in diagnostic quality and speed

Every day, healthcare moves forward with innovations. For radiology, the need for high productivity and an improved patient experience as well as excellent imaging, can be daunting, as performing MRI is often perceived as a trade-off between productivity and image quality. Innovations are needed for significant improvements.

The Ingenia Elition X delivers superb image quality, and performs MRI scanning up to 50% faster with Compressed SENSE<sup>1</sup>. The touchless, guided patient setup at the bore helps achieve a fast overall exam time. Furthermore, the Ingenia Elition X offers an immersive audio-visual experience to calm patients and guide them through MR exams.

The Philips **Ingenia Elition X** solution offers cutting-edge MR imaging techniques, while setting new directions for clinical research in 3.0T imaging based on new gradient and RF designs.

### Delivers speed without sacrifice - **every time**

- Enjoy patient setup in under one minute<sup>2</sup>
- Accelerate your exams by up to 50%<sup>1</sup>
- Automate your scan planning

### A **confident** diagnosis

- Achieve up to 60% higher resolution<sup>1</sup>
- Scan your DWI images up to 30% faster<sup>3</sup>
- Enhance your diagnostic confidence in neuro oncology
- Unlock new territories in neurofunctional MRI

### Dramatically improves **patient comfort**

- Reduce acoustic noise for your patient
- Guide your patients through the examination
- Provide an immersive visual experience

<sup>1</sup> Compared to Philips scans without Compressed SENSE

<sup>2</sup> Based on in house testing

<sup>3</sup> Compared to Ingenia 3.0T Omega HP R5.3

Results from case studies are not predictive of results in other cases. Results in other cases may vary.

# Faster\* MRI throughout the whole body with **Compressed SENSE**

## **Compressed SENSE allows up to 50% acceleration\* of individual scans with high image quality in Kantonsspital Winterthur**

As soon as the Compressed SENSE technology became available to the MRI team at Kantonsspital Winterthur (Switzerland), the site started applying the acceleration possibilities for their MRI scans of the brain, spine and joints as well as pelvis and abdomen. Using Compressed SENSE appeared a simple yet powerful way to accelerate MRI scanning for different contrast types and sequences, in 2D as well as 3D. The significantly reduced scan times convinced the team to plan for adjusting all their ExamCards, with the objective to shorten patient timeslots and then actually plan for increasing their number of MRI patients per day. This is of strategic importance to help them generate revenue when reimbursements go down.



### **Sabine Sartoretti, MD**

Dr. Sartoretti is Head of Neuroradiology at the Institute of Radiology and Nuclear Medicine, Kantonsspital Winterthur in Winterthur, Switzerland. She specializes in diagnostic neuroradiology. Her interests are dedicated stroke imaging, intra- and extracranial vessel wall imaging, brain tumor imaging, perfusion weighted imaging, diffusion weighted imaging, MR spectroscopy.

***“Our goal is to reduce scan time, but we want the same image quality as before.”***

### **How fast can we scan without losing image quality?**

The new Philips Compressed SENSE technology is a powerful acceleration technique for a wide variety of MRI sequences in a broad range of anatomies. The method combines compressed sensing and sensitivity encoding as in SENSE into one, more powerful, acceleration technique called Compressed SENSE.

Kantonsspital Winterthur (KSW) was one of the first 10 sites in the world to receive Compressed SENSE on their Ingenia 1.5T and Achieva 3.0T MRI scanners. Neuroradiologist Dr. Sabine Sartoretti and radiologist Dr. Rene Patzwahl have been using it since September 2017 and are very satisfied with the results. “As Compressed SENSE works in virtually all anatomical areas and with many different scan techniques and contrast types, it has the potential to help us reduce the scan time per patient. We can, for example, accelerate a routine brain protocol with 6

sequences (DWI, transverse T2, transverse T1 IR, SWI, 3D FLAIR, 3D T1 TFE with gadolinium) by 22% by accelerating three sequences (SWI, 3D FLAIR, 3D T1 TFE with gadolinium) between 30 and 40%. That shorter scanning time will then benefit our patients and in addition, it will allow us to scan more patients.”

In order to get there, Compressed SENSE has to be incorporated into KSW's customized set of ExamCards. “Our goal is to reduce scan time, but we want the same image quality as before, because most of our ExamCards have been meticulously optimized to our preferences.”

“Our approach for the last weeks has been to add an additional sequence with Compressed SENSE to the original exam, and then compare the images. In this approach we have initially been using a Compressed SENSE (CS) factor as recommended by Philips, then followed by applying either higher or a lower CS factors. Repeating this in a next patient

\* Compared to scans without Compressed SENSE

and for the different sequences, and carefully looking at the images afterwards, helps us decide what the best Compressed SENSE factor is for us.”

### Accelerating sequences one by one results in shorter exams

Dr. Sartoretti remembers how Compressed SENSE immediately impressed her in the first scans. “Our first sequence with Compressed SENSE was a 3D FLAIR in the brain on the Ingenia 1.5T, where we used a Compressed SENSE factor of 8.2. Then we tried a 3D TSE mDIXON sequence with a CS factor of 7. In both cases the quality was really good.”

In the neuroradiology area, Dr. Sartoretti initially focused on using Compressed SENSE in 3D imaging. “We use it now for 3D FLAIR, 3D DIR, 3D T1 TFE, 3D mDIXON T1 TFE, 3D TOF, 3D PCA and also for SWIp and 3D T1 Black Blood. We decided to first concentrate on 3D because of the large effect with 3D sequences, but of course we also want to try it with 2D sequences.”

Examples that Dr. Sartoretti mentions to particularly stand out are the venography with 3D PC that is 50% faster, and also the 3D T1 TFE, where speed was increased by 50%. Their TOF sequences were accelerated by 40%.

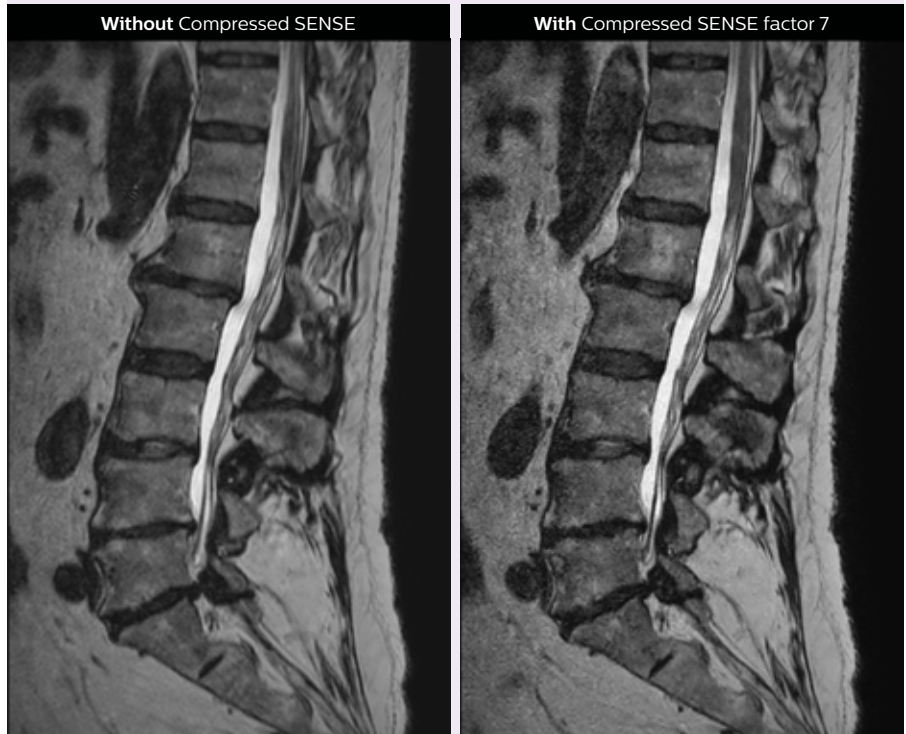“Our aim for the spine is to use Compressed SENSE to help us make the switch to using 3D SpineVIEW. In lumbar spine, for example, we can reduce scan time for 3D T2W SpineVIEW by 27% to 4:46 minutes, voxel size 0.8 x 0.8 x 1 mm.”

“In the end, we would like to just perform a 3D T2W, and 3D T1W, and a STIR T2W for cervical and lumbar spine imaging, and then do secondary reconstructions. That’s why we need high resolution for the 3D sequences, and combining with Compressed SENSE then helps to reduce scan time. In this way, replacing the 2D sequences with 3D sequences is much better for the patient, because we can reduce the time of the scan. Another advantage is that if sometimes a scan is not done properly, we have more freedom to do reconstructions afterwards with the 3D sequences and still make a confident diagnosis from the exam.” >>

“Our aim for the spine is to replace all 2D sequences with 3D sequences.”

### Accelerating lumbar spine

In this example Compressed SENSE has a 26% shorter scan time and improved spatial resolution simultaneously.

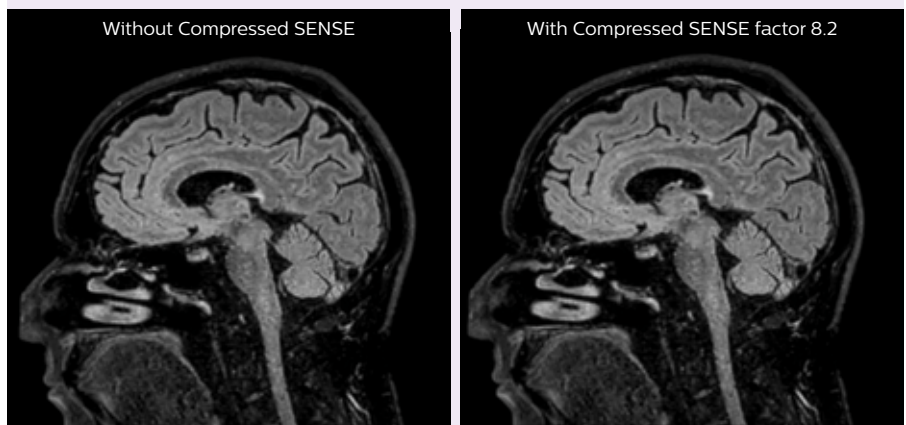


3D T2 SpineVIEW, scan time 6:29 min.  
Voxel size 1 x 1 x 1.4 mm

3D T2 SpineVIEW, scan time: 4:46 min.  
Voxel size 0.8 x 0.8 x 1 mm

### Shorter scan time in brain

Compressed SENSE allows 28% shorter scan time with the same spatial resolution.



3D FLAIR, scan time 5:02 min.  
Voxel size 1.1 x 1.1 x 1.1 mm, Ingenia 1.5T

3D FLAIR, scan time 3:36 min.  
Voxel size 1.1 x 1.1 x 1.1 mm, Ingenia 1.5T

**Significant acceleration\* in MSK, breast, abdomen, liver**

The KSW team also started implementing Compressed SENSE in ankle, elbow, knee and wrist MRI exams, for replacing the 2D PD fat sat with 3D PD fat sat. So far, result look good: it's possible to obtain a good acquisition time with a high resolution. The team envisions to finally end up with musculoskeletal ExamCards consisting

of three sequences, for example 3D PD-weighted fat sat – which is the most important sequence in MSK – plus a T1 and a STIR sequence. Or alternatively two T1 sequences and the 3D sequence.

At KSW, Compressed SENSE is also applied to reduce scan time for breast imaging. 2D STIR is now faster and silicon-only sequences are 30% faster,

for example. The 3D T1 THRIVE can be accelerated by approximately 40% and Compressed SENSE is currently being added to the dynamic T1 sequence, where the goal is to get higher resolution in the same scan time.

There are also some initial results for the abdomen, liver, and pancreas. The goal for MRCP is to accelerate this sequence by 50%. So far, only a few cases were done with accelerated dynamic T1 imaging, shorter breath holds and shorter in-phase and out-phase sequences. When more data is available, the team will carefully compare images and define their preferred balance. So far, there seems to good potential for decreasing breath hold duration to approximately 10-12 seconds.

**What is impact on exam time, on patients, on diagnostic reading**

Dr. Sartoretti recognizes two main effects of Compressed SENSE on the practice. "First, we can reduce the time needed per patient. By adding it to multiple sequences in an exam, we can maybe accelerate our examinations by 20-40%, which is considerably faster, and that's very good for the patients. Another effect is that we are replacing our 2D sequences with 3D sequences, which will be very helpful for the diagnostic reading of the sequences, especially in the musculoskeletal area."

In some cases, Dr. Sartoretti also sees the benefit of keeping the acquisition time the same, and increase the amount of detail in images. "In nerve imaging, for example of plexus and in peripheral neurography, more detail is helpful to see the tiny nerves. We also like to add Compressed SENSE to the 3D T1 Black Blood sequence, for obtaining higher resolution when looking at the detailed anatomy of vessel walls and to visualize pathology of these tiny vessels in the brain." The lumbar spine example above also illustrates an improvement of spatial resolution with use of Compressed SENSE.

Dr. Sartoretti's intention is to ultimately include Compressed SENSE in all ExamCards. "We modify a few ExamCards every day, but it will take some time to adapt them all, as we have between 200 and 300 different ExamCards."

*"We can maybe accelerate our examinations by 20-40%, and that's very good for the patients."*

**Comparing 2D with 3D using Compressed SENSE**

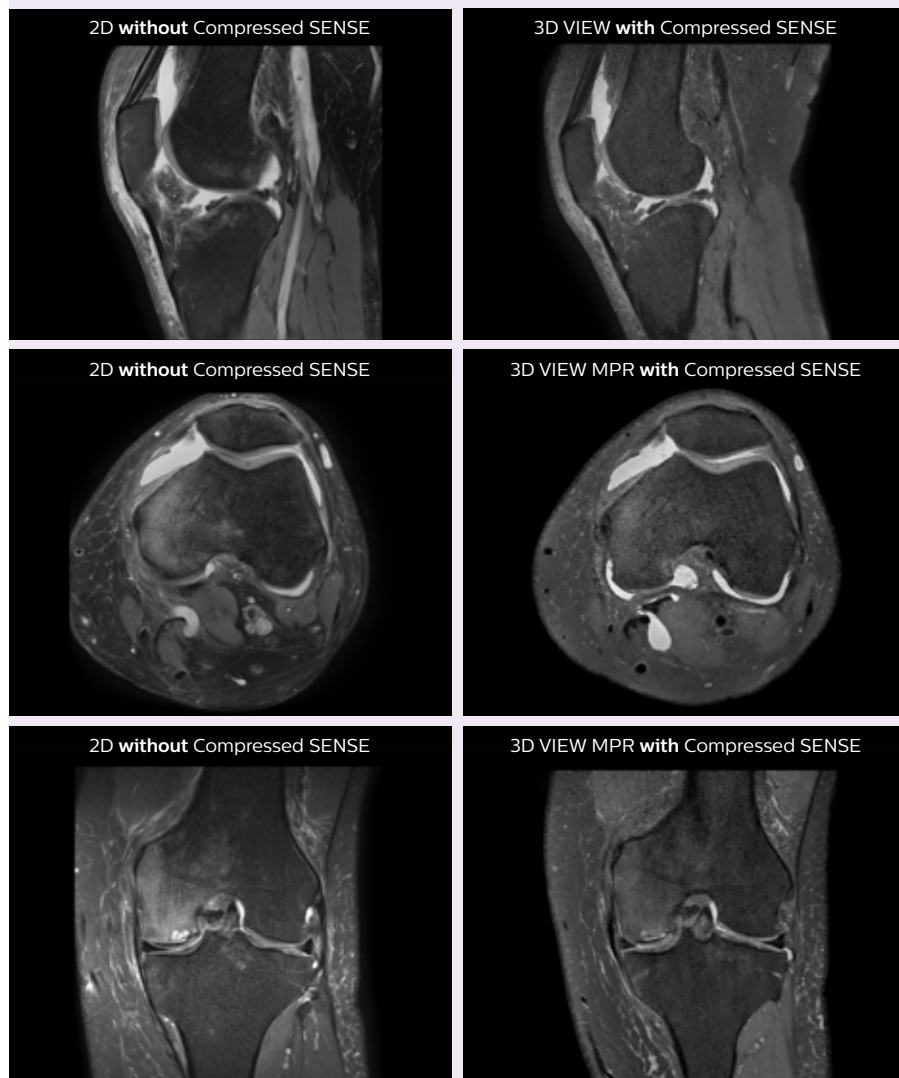
A good acquisition time with high resolution is obtained when moving from three 2D acquisitions in three planes to one 3D acquisition with Compressed SENSE. In this example, Compressed SENSE with 3D VIEW PD SPAIR is 50% faster than three separate 2D scans and has improved spatial resolution.

**Without Compressed SENSE**

Three separate 2D PD scans in three orientations. Scan time 2:55 + 3:37 + 3:51 = 10:23 min. Voxel size 0.55 x 0.65 x 3 mm

**With Compressed SENSE factor 10**

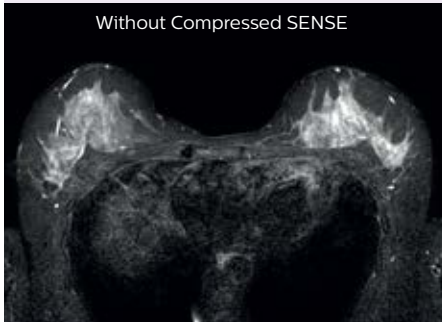
3D VIEW PD SPAIR high resolution knee Scan time 5:03 min. Voxel size 0.6 x 0.6 x 0.6 mm





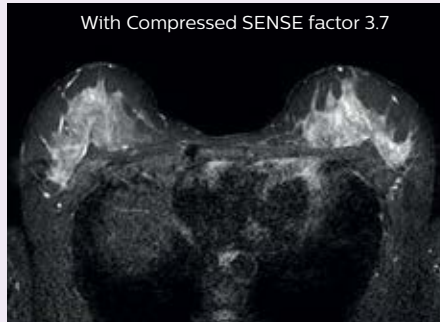
## Accelerating 2D breast MRI

Compressed SENSE allows 29% shorter scan time with similar spatial resolution.



Without Compressed SENSE

2D STIR, scan time 3:39 min.  
Voxel size 1 x 1.25 x 3 mm



With Compressed SENSE factor 3.7

2D STIR, scan time 2:36 min.  
Voxel size 1 x 1.26 x 3 mm

### Aiming for substantial reduction of overall scan time per patient

Dr. Sartoretti's believes that implementation of Compressed SENSE will help them to substantially accelerate complete MRI examinations. "For brain examinations, we would like to gain about 10 minutes per examination. We're working on this currently. For example, for a standard brain examination without contrast we now use a 30 minutes timeslot, and we would like to bring that down to about 20 minutes. And of course the timeslot also includes the time needed to position the patient on the table."

"Similarly, for the spinal cord and for the lumbar spine, we now have 30 minutes timeslots, which we would also like to reduce to 20 minutes, in total, including the patient positioning and scanning time. We would like to accelerate the scanning itself by 40%, so that scanning uses considerably less time than it took previously. My MSK colleague also told me that he would like to reduce the scanning time in joints to 15 minutes."

### Scanning more patients to help relieve economic pressure

Dr. Sartoretti is adopting Compressed SENSE at a rapid pace as she sees possibilities for helping the department deal with economic pressure and workflow challenges. "In 2018 reimbursements will be reduced here in Switzerland, so we get paid less per patient. At the same time, examinations are getting more complicated, so we need more time for the reading. And of

course, we continually need funds to always have state-of-the-art machines with good software, good sequences and good coils to perform well. To compensate, we need to attract more patients for break even. And that's where we believe that Compressed SENSE can help us, as faster scanning can allow us to do more patients per day."

"Right now, we scan between 40 and 45 patients per day on our three MRI scanners. We are relatively slow, because we see many older patients, patients from intensive care and patients with severe medical conditions, so that we need quite much time just to position these patients. Our aim is to use Compressed SENSE to help us increase to scanning around 50 to 55 patients per day."

Dr. Sartoretti also aims to slightly change their MRI patient mix. "Because complicated examinations for inpatients require more time than MR examinations of most outpatients – for scanning as well as for reading – we would like to become more attractive for outpatients. Scanning outpatients is easier for us, because they often need less time for positioning, they cooperate better, and the diagnostic

***"A typical brain exam in our patient group takes 24 min, which we now have reduced to 19 min."***

reading is often easier because of an often less complicated diagnosis. In our partner institute, scanning mostly outpatients, they do 16 to 20 patients per day on one MRI machine."

"So we would like to have a better mix of in- and outpatients, which we expect to help us perform our workload in better timing. Currently, our waiting list for outpatients is too long, typically more than one week. If we could add more timeslots, so that we can offer outpatients a timeslot the next day, for example, we believe we could also get more outpatients from referring physicians."

### Faster\* scans in virtually any area of the body

Faster MRI scanning without losing image quality is key to making MRI faster and cheaper and thus accessible to more patients. Philips was the first to introduce commercially available parallel imaging, called SENSE, and continuous innovations have resulted in the powerful dS SENSE and in MultiBand SENSE offering great flexibility in neuroscience. And now, with Compressed SENSE, additional acceleration can be applied in virtually any area of the body.

"Compressed SENSE offers opportunities to significantly reduce examination times. Fast scanning benefits patients, as they don't need to spend much time in the scanner. For us, the faster scanning can help increase patient throughput. And of course, seeing more tiny details, for instance with 3D, helps us in making confident diagnoses," concludes Dr. Sartoretti. <<

***"We would like to have a mix of in- and outpatients, which will help us with the timing of our workload."***

# MRI in-bore solutions: **patients love it, departments thrive**

## **Patients really like MRI in-bore solutions, and case studies on reduced need for sedation and less rescans**

Recent studies by hospitals in Denmark, Japan and Germany demonstrate the broad impact of enhancing the experience of patients in the MRI scanner. It helps the centers stand out in their market, as satisfied patients and referring physicians spread the word. With an improved in-bore experience, for instance with In-bore Connect, image quality benefits and reductions in rescans\* are reported, because a relaxed patient is less likely to move. Next to that, an impressive 80% reduction in the need for sedation is found in a case study at one center in Germany.



**Yoshitada Masuda, RT, PhD**  
Chief Radiological Technologist at the Department of Radiology, Chiba University Hospital, Chiba, Japan.

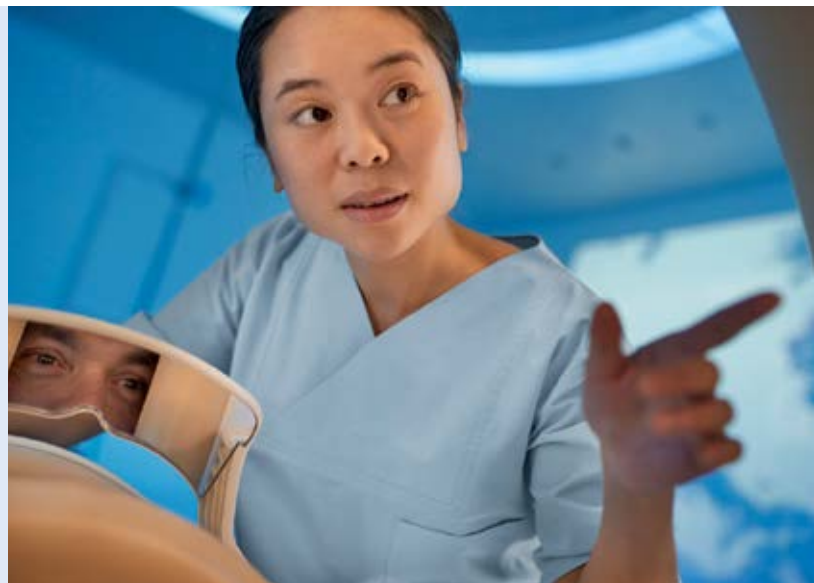

From left to right: **Jonas Bovin, Jeannette Brus Mortensen** and **Kristian Fogh**, radiographers at the MRI department of Herlev Hospital, close to Copenhagen, Denmark.

### **Designing the patient's experience during MRI**

For patients, an MRI exam can be a long, stressful, noisy, experience. Feelings of anxiety and discomfort can make it hard to remain still and complete the procedure. This can lead to motion artifacts in the images, or to the need for rescans and even exam cancellations. Some patients need sedation to successfully undergo MRI.

To improve on this, Philips provides a holistic approach to help MRI patients feel comfortable and relaxed. During the scanning, an audiovisual experience and additional features can distract and inform patients. Users have collected data that illustrates how large the effect can be.



## Majority of patients would recommend a scan with In-bore Connect

A multi-center study was conducted to capture the effect of In-bore Connect on patients and staff. The participating centers were Herlev Hospital in Denmark, using an Ingenia 3.0T system with In-bore Connect and Chiba University Hospital in Japan, using an Achieva 1.5T dStream and Ingenia 3.0T both with In-bore Connect.

Data from 1,217 patient scans were collected before and after installation. All conditions were kept equal except for the In-bore Connect option being on or off. Additionally, almost 200 patients completed a questionnaire on their experience during the MRI scan.

Dr. Yoshitada Masuda of Chiba University Hospital found that “Before using In-bore Connect, 88% of our patients indicated they were not satisfied with their MRI experience, and that made a big impression on us. After installing In-bore Connect, we found that this really helps patients have a calmer, better experience, especially those who are nervous.”

The patient surveys from Herlev and Chiba show that 84% of the patients feel calmer because of the In-bore Connect. A clear majority of patients say they would recommend the MRI system with Ambient experience and In-bore Connect to others needing an MRI (NPS 60).

## Entertainment and guidance in the bore to relax patients

The current multi-center study focused on the effect of In-bore Connect on top of that previous finding. In-bore Connect is designed for patients feeling a sense of isolation while in the scanner, maybe wondering how much longer the examination will still take, feeling alone, or not knowing why the noise stopped.



The **progress bar** is displayed on the video screen that the patient is watching while in the scanner. It shows the patient in real time how the scan progresses. So, it helps to give patients a sense of time during examination.

## “Many patients say they were really glad they could see how much time the scanning still takes”

The MRI technologists Kristian Fogh, Jonas Bovin and Jeannette Brus Mortensen at Herlev Hospital have noticed that their patients feel significantly more comfortable with the In-bore Connect. “The progress bar is very much appreciated by our patients. Many say they were really glad they could see how much time the scanning still takes before the examination is completed. Especially patients who have been in an MRI scanner before recognize this as a big improvement”, says Mr. Fogh. “In-bore Connect is making it easier to give patients a good experience here.”

The majority of patients stated that they find it important to understand how long the examination is still going to take. No less than 84% of the surveyed patients indicated that the progress-bar helped them to feel calm. >>



## Entertainment and guidance in the bore to relax patients

Patients lying in an MRI scanner with In-bore Connect undergo an immersive experience. It offers patient entertainment while involving and informing them with a progress bar, breath-hold guidance and AutoVoice. It can be also combined with up to 80% noise reduction by using ComfortTone.



The **breath-hold guidance** function coaches patients through the breath holding that is needed for some scans. It shows a patient when to start and how long he or she still needs to hold breath.

### Breathhold guidance can make a difference for completing a scan

The multi-center study results show that patients find it significantly easier to be compliant with breath-hold instructions. “After a scan, patients often say that it helped them to see how long a breath-hold will still last,” says Mr. Fogh. “Seeing that you only have to hold breath for two more seconds, for example, can help a lot in achieving it. I consider this is a great improvement for achieving a successful breath-hold scan.”

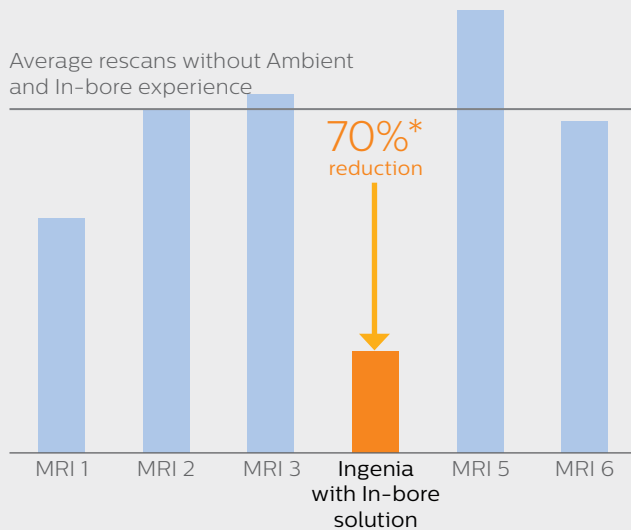
According to Dr. Masuda, also the patients at Chiba really appreciate the sense of time they get from both the progress bar and the visual breathhold guidance. Also AutoVoice contributes as it announces table movements and next scans, in their own language. “It’s a comprehensive solution. All features together help achieve this effect,” says Dr. Masuda.

### Good results with difficult patients

“We have often seen the large effect it can have on a patient entering the MRI room. I remember one patient that felt claustrophobic and reluctantly came to his MRI appointment, but afterwards he said that he had an excellent experience,” says Dr. Masuda.

In Japan, patient experience is also important because it can benefit cost effectiveness. “When a patient is relaxed, we can more easily obtain good image quality than with a nervous, restless patient who is more likely to move. Patient motion causes artifacts or interrupted scans, leading to repeat scans or even rescheduling the exam, which costs additional time. We see every day how In-bore Connect helps to relax patients, allowing our technologists to obtain high quality MRI images.”

**“The progress bar and AutoVoice really help me in my daily work”**



### Improving MRI experience can reduce the need for repeat scanning

In an earlier study, Herlev Hospital had already been scanning with the initial version of In-bore experience in their Ingenia scanner room with Ambient Experience. In a study performed in 2015, they demonstrated a **70% reduction in the number of interrupted scans** on their Ingenia 3.0T with In-bore solution compared to the average of their five other Philips MRI scanners.

\*Compared to the average of the other 5 Philips MR scanners without Ambient and in-bore experience. Results from case studies are not predictive of results in other cases. Results in other cases may vary.

## Building reputation and referrals with focus on patient satisfaction

To the team at Herlev Hospital it is clear that In-bore Connect increases patient satisfaction significantly. “Most of our patients feel that the experience they had in the scanner with In-bore Connect is much better than their previous experiences. Especially patients feeling worried were glad to be able to look out at a screen, and see the progress. Patients indicate that this helps them relax,” says Mr. Fogh

“Patient satisfaction is a key goal at our hospital, which is why we invested in improving the patient experience during MRI. And funny thing is, that it is a quite easy way to really, significantly improve the experience for our patients,” says Mr. Fogh. And Ms. Mortensen adds “Our name is on the Danish map, we are known for having this focus and this in-bore solution in Herlev Hospital. Some patients we scan have travelled quite far.”

Also at Chiba University Hospital, patients are significantly more satisfied when undergoing MRI with Ambient Experience and In-bore Connect. “Our patients are telling referring physicians about their experience with In-bore Connect and asking for that scanner for their MRI examination.” says Dr. Masuda. “And we are receiving many visits from colleagues from other hospitals that are interested in acquiring it at their own institutions.” >>

**“We have often seen the large effect it can have on a patient entering the MRI room”**

“Our name is on the Danish map, we are known for having this focus and this in-bore solution in Herlev”

Jeannette Brus Mortensen



“Patients are asking their physicians if they can have In-bore Connect during their MRI examinations”

Kristian Fogh



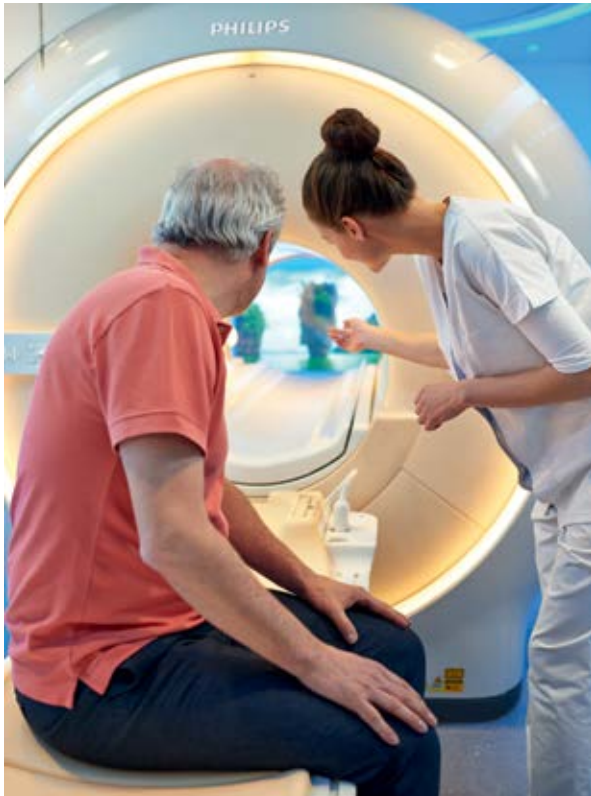“It is a quite easy way to really, significantly improve the experience for our patients”

Jonas Bovin



“We found that In-bore Connect really helps patients have a calmer, better experience”

Yoshitada Masuda, RT, PhD



**“Our patients were calmer and more compliant”**

#### References

1. Andre JB, Bresnahan BW, Mossa-Basha M, Hoff MN, Smith CP, Anzai Y, Cohen WA. *Towards quantifying the prevalence, severity, and cost associated with patient motion during clinical MR examinations.* J Am Coll Radiol. 2015;12:689-95.
2. Mélendez JC, McCrank E. *Anxiety related reactions associated with magnetic resonance imaging examinations.* JAMA. 1993;270:745-47.
3. USA Customer Survey (118), September 2015, data on file.
4. *Relaxed patients, reduced motion, increased productivity.* Philips FieldStrength, [www.philips.com/fieldstrength](http://www.philips.com/fieldstrength)
5. Kesseböhmer J. *Can enhancing the MRI in-bore experience reduce the need for patient sedation?* Diagnostic Imaging Europe 2017

**“We found a significantly lower need for sedation among patients scanned on the Ingenia with In-bore Experience”**

#### **Can enhancing the MRI experience reduce the need for patient sedation?**

The Radiologisches Zentrum am Kaufhof (RZK) in Lübeck, Germany, is using an Ingenia 1.5T S with in-bore experience solution in addition to three 1.5T MRI systems from other brands. The center's MRI case load is basically covering the whole spectrum, but the largest fraction is musculoskeletal imaging. The Ingenia system is in operation since 2015 and, according to Dr. Jan Kesseböhmer, patient comfort had been a main requirement for selecting that system, in addition to energy efficiency and the need for up-to-date imaging capabilities.

Dr. Kesseböhmer recognized the opportunity to not only differentiate the practice from competitors, but also provide a high degree of patient comfort during scanning with the Philips Ingenia 1.5T S with its in-bore solution. “It allows us to adhere to – or even raise – our high standard of patient comfort. The room lighting and the in-bore experience provide a relaxing environment through an immersive video experience during the scan, that we expected to enhance patient comfort and cooperation, as well as improve workflow. Ingenia 1.5T S also offers the possibility to perform scans with reduced noise.”

#### **A better overall impression and reduced anxiolytics use**

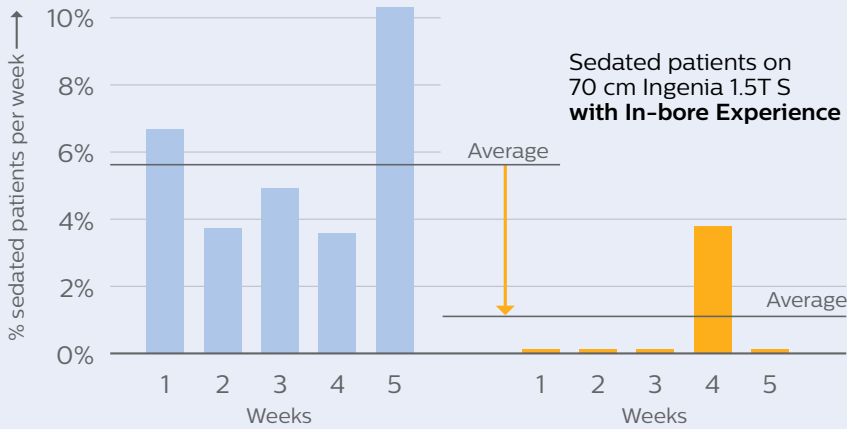
Six months after installing the system, a retrospective survey on patient experience was conducted, together with a review of the practice data. “We learned that for a majority of our patients the overall impression of Ingenia with in-bore experience was better than the overall impression of our other 70 cm wide systems without in-bore experience,” says Dr. Kesseböhmer.

“The retrospective preliminary data also suggested that we were using much less anxiolytic sedative medication for patients in the Ingenia MRI system with in-bore solution. This provided us with a further understanding of the value that the relaxing environment provides. We believed we could have a significant, measurable impact on patient anxiety due to the distracting nature of the in-bore solution.”

#### **Sedation can help patients undergo MRI but has downsides**

Sedation is a commonly used approach to allow patients to undergo an MRI examination without major patient movement that can deteriorate image quality. Dr. Kesseböhmer distinguishes several scenarios of patients requiring sedation in order to successfully complete an MRI examination. “For patients with claustrophobia or a history of needing sedation in the magnet,

### Sedated patients on 70 cm 1.5T systems without In-bore Experience



### The number of sedated MRI patients was 80% lower with In-bore Experience in this case study

The study results show a significant ( $p = 0.005$ ) decrease in the percentage of patients who required sedation\* with the In-bore Experience, a substantial 80% difference.

\*Case study performed at Radiologischer Zentrum am Kaufhof in Lubeck, Germany (n=583). Courtesy of Dr. Kesseböhmer. The medication referred to is diazepam 10 mg iv. Results represent a case study performed at a single location. Results from case studies are not predictive of results in other cases. Results in other cases may vary.

we know beforehand that they will need sedation. Secondly, there are patients who get very anxious when entering the MRI room and are offered sedation right at that moment. A third, and fortunately small group, are patients who start a scan but then appear incapable to complete it, so that we have to cancel the examination and try again with sedation.”

The need to sedate patients can pose significant operational disruptions and administrative burdens for imaging centers. Evaluating whether a patient needs sedation takes time and additional handling. The risk of respiratory depression imposes the need for monitoring a sedated patient during the scanning. For the patient, there are also practical considerations, such as dizziness, nausea and the advice to not drive directly after their MRI exam. These factors can negatively affect both the patient and staff experience, and raise costs.

### Decreasing the need for patient sedation with In-bore Experience at RZK in Lübeck

The results of the retrospective study made Dr. Kesseböhmer decide to conduct a prospective study, to further compare the Philips Ingenia 1.5T S with In-bore Experience with the institution’s two other 1.5T systems. All three systems have a 70 cm wide bore diameter.

“We started this study to confirm our retrospective observation that the Philips system would decrease the need for sedation, and we again found a significantly lower need for sedation among patients scanned with the Philips system. The percentage of patients requiring sedation while being scanned with the Philips MRI In-bore Experience decreased by 80% versus the average of our two other wide-bore 1.5T MRI systems.[5] We discovered that our patients were calmer and more compliant when scanned using the Philips MRI In-bore Experience.”

### Achieved goals and further observations

The effect that In-bore experience has on patients can be amazing, according to Dr. Kesseböhmer. “We had a 7-year-old boy who was very anxious and shy when he came here for an MRI scan. However, after being scanned in the system with In-bore Experience, he was totally changed. He was so elated and interested, and was making suggestions about lengthening the movie, and so on. He wasn’t thinking anymore about why he was there, but about how great the MRI machine was. For us, having a good acceptance of the MRI without sedation is really the clue to examining children.”


Another big impact is that patients seem to feel less isolated and left alone in the magnet. “Patients sometimes wonder what’s coming, for example when there is a pause due to preparing a next sequence. But with the In-bore Experience, patients continuously have information about the study, how long the next scan will take, and whether the table is going to move.

Reflecting on our goal with this scanner, to differentiate ourselves – I think this has really been achieved, with the biggest impact being that in-bore experience for the patient. I think this is something special, and I’m pretty sure that patients are talking about it. And we now know that use of sedation is not an inevitability in MRI and this is great news for our patients.” <<

**“Reflecting on our goal to differentiate ourselves, I think this has really been achieved”**

# How to perform **MRI** of patients with MR Conditional cardiac devices

## **MR Conditional pacemakers and ICDs should be no impediment for scanning patients**



Cardiac pacemakers, implantable cardioverter defibrillators (ICDs), or implantable loop recorders are electrically active cardiac devices, which used to be contraindicated for MRI. However, that is no longer the case if the device is labeled MR Conditional [1].

In such cases, the MRI scan must be set up to meet the MR conditions specified by the implant manufacturer. This article addresses questions like: what is the difficulty with active cardiac devices, what are MR Conditional devices, what are the conditions, how to make an MRI scan comply with the conditions and how to design the patient pathway.

### **Also patients with cardiac implants need MRI scans**

"It's long ingrained into the minds of physicians that MRI and implanted cardiac devices don't mix and they're contraindicated. However, nowadays, if patients have an active cardiac device that is MR Conditional, they can undergo MRI when needed [2]," says Amit Patel, MD, Director of Cardiac MR and CT at the University of Chicago Medicine."

And the need definitely exists. It has been estimated that due to the increased prevalence of cardiac implants and the increased use of MRI, there is a 50-75% probability that a patient with a pacemaker will need an MRI at some point during their life [3].

"Because pacemakers were contraindicated for MRI for many years, I think that a lot of referring physicians may not yet be aware that modern-day MR Conditional active cardiac devices allow patients to undergo MR procedures. So it's partly an educational process to get the general acceptance of patients with MR Conditional cardiac devices," says Dr. Frank Shellock, PhD, an expert in MR safety.

### **What are potential risks of active cardiac devices in MRI?**

"Pacemakers and ICDs are complex, electrically active cardiac devices which may interact with the magnetic and

electromagnetic fields of an MRI system in different ways. There are basically three main risks," says Torsten Sommer, MD, Director of the Department of Diagnostic and Interventional Radiology of the German Red Cross Hospital in Neuwied.

"First, the active cardiac device can not differentiate intrinsic heart activity of a patient from pulsed electromagnetic fields of the MRI system. As a consequence, MR scanning may block or inhibit cardiac pacing which may be harmful or even fatal for pacemaker-dependent patients."

"Second, heating of the device leads due to interaction with the radiofrequency (RF) field used in MRI can lead to thermal tissue damage in the heart muscle and irreversible pacing capture threshold increases. The third risk is that the gradient fields used in MRI may induce voltage pulses in the leads that can induce severe cardiac arrhythmias."

### **How safe are MR Conditional cardiac implanted devices?**

Since the first regulatory approvals in 2008, MR Conditional pacemaker systems have been offered by cardiac device manufacturers. These systems, composed of a pacemaker pulse generator and leads, are tested for MR examination under certain specified conditions.





**Torsten Sommer, MD**, Director of the Department of Diagnostic and Interventional Radiology at the German Red Cross Hospital in Neuwied, Germany. As a radiologist he specialized in cardiovascular imaging and MR safety and is the lead author of numerous (inter)national papers on MRI in patients with cardiac pacemakers and implantable cardioverter defibrillators.



**Frank Shellock, PhD, FACR, FACC, FISMRM**, Adjunct Clinical Professor of Radiology and Medicine and Director for MRI Studies of Biomimetic Microelectronic Systems at the University of Southern California, USA. Additionally he is the Founder of both the Institute for Magnetic Resonance Safety, Education, and Research ([www.IMRSE.org](http://www.IMRSE.org)) and the MRI safety website [www.MRIsafety.com](http://www.MRIsafety.com).



**Jürg Schwitter, MD**, Professor of cardiac imaging and Director of the Cardiac Magnetic Resonance Centre at the University Hospital CHUV, Lausanne, Switzerland. He is an expert in cardiac MRI, with an extensive research record in the assessment of coronary artery disease, tissue viability, and cardiac mechanics and energetics.



**Amit Patel, MD**, Associate Professor of Medicine and Radiology and Director of Cardiac Magnetic Resonance and Computed Tomography, at the University of Chicago Medicine, Chicago, USA. He is a cardiologist, specialized in the use of advanced imaging techniques to provide individualized therapies for patients with heart disease.

## *“Understanding of and compliance with the conditions of use for the specific pacemaker system are essential for patient safety”*

“Understanding of and compliance with the conditions of use for the specific pacemaker system are essential for patient safety,” says Dr. Sommer. “These conditions include limitation of MR parameters such as the specific absorption rate (SAR), the maximum slope/amplitude and the maximum slew rate of the gradient fields. These parameters determine the amount of lead heating induced by the RF fields and the amount of voltage induction in the leads induced by the gradient fields. So, surveillance and limitation are critical.”

Robert Kowal, MD, chief medical officer for the Cardiac Rhythm and Heart Failure division at Medtronic, a company that produces MR Conditional implants, explains how low-power pacemakers as well as high-power ICDs were modified to make MR Conditional models of such devices. “The ferromagnetic material was reduced, and the mechanical switch was replaced with a sensor. In addition, filters have been added so that the pulsed electromagnetic MRI fields will not interfere with device functions or induce voltages high enough to stimulate the heart. Finally, the implanted device software includes dedicated protective modes for MR imaging.”

Computer modeling and randomized clinical trials have been used to assess the safety of Medtronic MR Conditional active cardiac devices for full-body MR scans [4,5]. Also for imaging the heart itself safety has been established for MRI scans under specific conditions of patients with an MR Conditional pacemaker [6]. It is shown that acquisition of diagnostic-quality cardiac images is possible in the presence of an MR Conditional implant in the vast majority of patients [7,8].

### **Routine procedure in some hospitals**

“It’s absolutely crucial for physicians to understand that many patients now have cardiac devices that are MR Conditional. This means that MRI scanning is possible, but special conditions have to be fulfilled,” says Dr Sommer.

“We are using a dedicated pathway with an established cooperation with the cardiology department and are scanning about 250 to 300 pacemaker and ICD patients a year. So, for us it’s a quite familiar procedure which is fully integrated in the clinical workflow.”

### **Pacemaker patients can get MRI, but why not yet in every hospital?**

However, many centers appear reluctant to begin imaging patients with MR Conditional cardiac implants. “One reason for this is difficult accessibility of information about the precise conditions of use, which may vary greatly among different device manufacturers. An even more important concern of many radiologists is how to ensure that MR scanning is in compliance with the requested limitations of SAR values of the RF field and maximum gradient slope and slew rate of the gradient fields,” says Dr. Sommer.

“So, when patients with MR Conditional cardiac devices contact a radiology department for MRI, they may still experience that acceptance is low. And increasingly, patients are becoming aware of this discrepancy. A patient with an MR Conditional pacemaker may not understand, why he is still refused an MRI exam.” Currently, these patients may have to contact a more “specialized” MRI center which is usually part of a larger tertiary hospital.

### **Special preparations before MRI of patients with pacemakers**

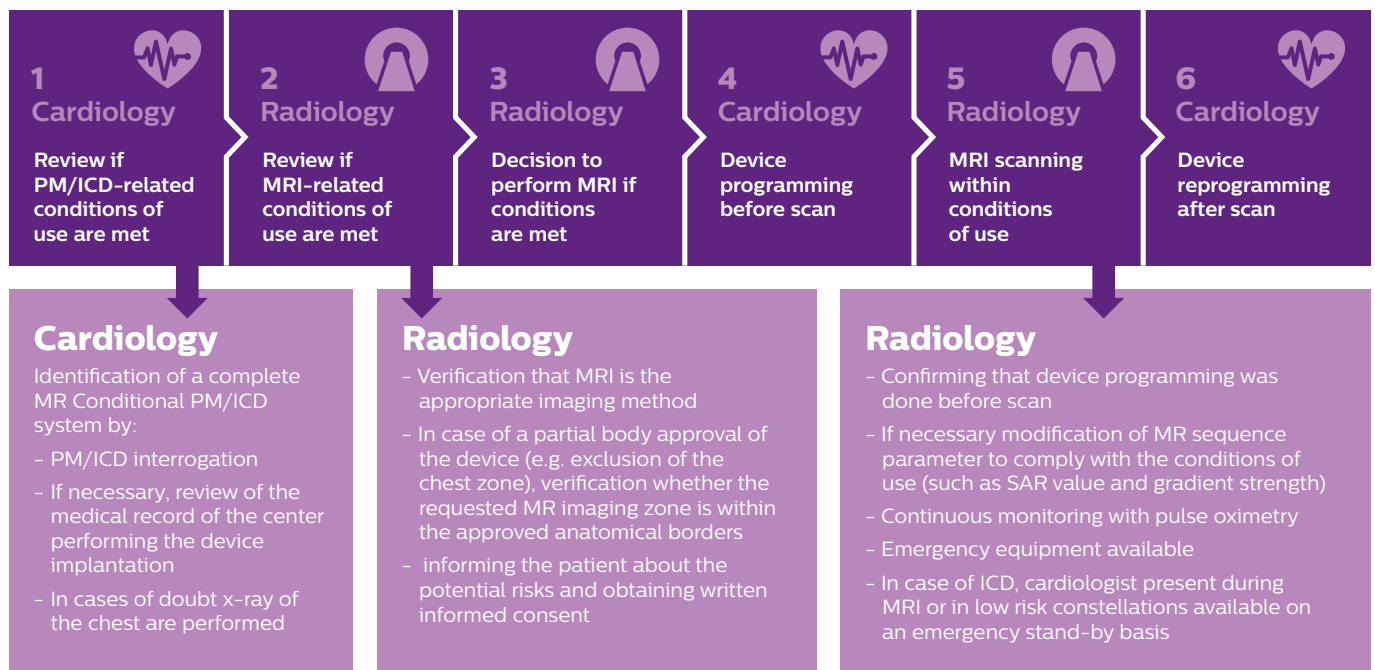
When a patient with an MR Conditional active cardiac implant presents, the exact brand and type of the implanted device must first be determined. If the device is MR Conditional, then the next step is to retrieve the implant’s MR conditions that are specified by the implant manufacturer [9-10], for instance from the implant manufacturer’s documentation or website.

Just before the MRI scan the implanted device is programmed to safe mode in the cardiology department and it is reprogrammed >>

*“When we understand that the patient has a cardiac device, we send this patient to cardiology to check what device the patient has”*

## Pathway for MRI of pacemaker/ICD patients

As used at the German Red Cross Hospital, Neuwied, academic teaching Hospital of the University of Bonn. Adapted from the German Roentgen Society statement and the consensus paper of the German Cardiac Society and the German Roentgen Society.



### Checklist Cardiology

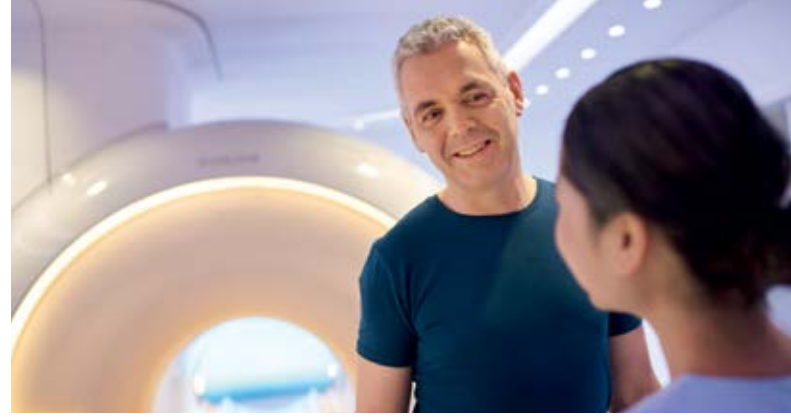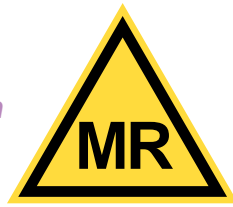- 1 Verification of a complete and approved MR conditional pacemaker system consisting of an MR conditional pacemaker generator and MR conditional pacemaker leads
- 2 Verification of left or right pectoral implantation site of the pacemaker system
- 3 Implantation time > 6 weeks
- 4 Electrically intact pacemaker leads
- 5 Pacing capture thresholds within the normal range
- 6 Sufficient battery capacity based on the manufacturer's specification
- 7 No additional cardiac leads (particularly no abandoned pacemaker leads), no additional components such as lead adapters or lead extensions
- 8 Exclusion of other cardiac implants, depending on the manufacturer's specification
- 9 Written documentation by the attending cardiologist indicating that the electrophysiological conditions of use of the device have been fulfilled



### Checklist Radiology

- 1 Verification of the conditions of use with respect to design and field strength of the MR system
- 2 Verification of the conditions of use with respect to amplitude and slew rate of the MR gradient system
- 3 Verification of the conditions of use with respect to the SAR value of MR scans Whole-body vs. partial-body approval
- 4 Presence of other extra-cardiac implants that rule out MR examination
- 5 Final written documentation by the attending physician indicating that the MR-related conditions of use of the pacemaker have been fulfilled.

*“An MR Conditional item has demonstrated safety in the MR environment within defined conditions [1]”*



again after the MR exam. All scan sequences of the MRI exam must to be set up to stay within the limits and conditions specified by the implant vendor.

“We have a process in place that includes electrophysiologists, who are experts in these devices, and imaging physicians, who are the experts in imaging,” says Dr. Patel. “Together they have set up a protocol and infrastructure so that the device can be interrogated before and after the MRI and it can be reprogrammed, as necessary, before and after. During the MRI scan, an ACLS (Advanced Cardiovascular Life Support) certified person with some expertise in device programming needs to be present to monitor the patient.”

“The screening procedure for patients with cardiac implants can differ between sites,” says Dr. Shellock. “At many sites in the USA, the MRI technologist or radiographer is responsible for screening the patient, identifying an implant and then also looking at the information to determine what the MR conditions are for that particular implant or device. Technologists have the experience and are trained in MRI safety. There may be other MRI safety trained individuals, including imaging nurses, MRI technologist aides, or assistants, who have been appropriately educated and trained enough to handle screening procedures as well.”

### **A well-designed pathway benefits an efficient process**

Jürg Schwitter, MD, cardiologist at the University Hospital of Lausanne, Switzerland explains that a well-designed patient trajectory is an essential element of providing an MRI service for patients with MR Conditional cardiac implants.

“We established a pathway that we have been using for two or three years now. It is particularly important to control the workflow before the patient enters the MR suite. Our pathway helps us avoid waiting time at the machine and makes the technologists feel comfortable. As we do a lot of cardiac MR in the same unit, there is always a cardiologist around that they can consult. I think it’s also important to emphasize the cost-effectiveness of our pathway: we manage to have almost no loss of machine time, when scanning pacemaker patients or ICD patients.”

**First step is finding out which device the patient has** MRI of a patient with an MR Conditional cardiac implant needs to be performed under the MR conditions specified for that particular implant. So, the first step is determining what exactly is implanted in the patient.

“To properly determine the particular type of implant that’s present, is definitely one of the challenges that are faced during

the screening procedure,” says Dr. Shellock. “We need to know if it is a standard pacemaker or one of the specialized MR Conditional cardiac devices, such as an MR Conditional pacemaker [9-10].”

“Most of our patients carry a pacemaker card or implant card, which facilitates the process of finding MR conditions,” says Dr. Sommer. “A pacemaker card provides important information, including the manufacturer, the model name and number of the pacemaker itself and the leads. With this information we can contact the manufacturer’s hotline or website to find the MR conditions.”

### **Cardiologists can often directly identify an implant**

“When the patient is referred by the cardiologist who implanted the cardiac device, the cardiologist can provide specific information about the type of implant. Sometimes though, additional work needs to be done to identify the specific type of make and model of the implant that’s present in the patient, such as reviewing the operative notes of the implantation procedure,” says Dr. Shellock.

“In our hospital, the workflow usually starts with a phone call from the patient or the referring physician to our department,” explains Dr. Sommer. “When we understand that the patient has a cardiac device, we send this patient to cardiology to check what device the patient has, and to learn if there are abandoned leads, additional cardiac electrodes or other electrophysiological conditions such as lead defects, low battery status or increased pacing capture thresholds which might be a problem.”

“From the perspective of a cardiologist, establishing the identity of an implant can sometimes be more direct,” says Dr. Patel. “Most electrophysiology clinics will have each of the different device manufacturers’ programmers there, and you can just place the programmer over the chest wall and see if it recognizes the device. There are only a few different manufacturers that would account for the bulk of the patients.”

“I think it may be more challenging for an imaging physician to figure out. But I think one of the key messages is that this: if you’re going to image these patients, it should be done in collaboration with an electrophysiology group of some sort.”

### **Accessing specific MRI conditions**

Finding the MR conditions for the specific implant that a patient has is a key step before performing the MRI exam, emphasizes Dr. Shellock. “For example, some MR Conditional, active cardiac devices may have designated conditions that state a >>

### *“Patients with MR Conditional cardiac devices may still experience that acceptance for MRI is low”*

field strength 1.5 Tesla, only. Another condition that is usually specified is a maximum SAR value that may not be exceeded during the MRI scan. This information is important to manage those patients properly in order to meet the conditions for a particular cardiac device.”

Dr. Sommer says that establishing the scanning conditions for implants can sometimes be a challenge “It’s important to determine if the patient’s full system is MR Conditional. That is not so straightforward, because a pacemaker consists of the implantable pulse generator (IPG) and the electrodes. And it’s necessary that all of those are MR Conditional and also that the combination of them is MR Conditional.”

“In radiology we check the exact MR conditions for the implant, because not all MR Conditional devices are cleared for full body MRI. With some devices with only partial body approval it’s allowed to scan the head and below the hips. So, basically, radiology and cardiology together have to make sure that the conditions that have to be met are clear,” says Dr. Sommer. “This information is essential to manage these patients properly and to meet the conditions for a particular cardiac device.”

Dr. Sherlock created and maintains the MRIsafety.com website that provides a lot of information. “We work quite closely with the device manufacturers and encourage them to provide the required information, particularly the MR Conditional statements and the guidelines to follow. MRIsafety.com contains links to many manufacturer websites.”

### **Switching the MR Conditional device to scan mode**

Dr. Schwitter’s institute in Switzerland schedules an appointment for the patient at the outpatient cardiology department 30 or 45 minutes before the MRI scan. “The patient goes to cardiology to switch the pacemaker to MR scan mode. After we performed the MRI exam, we send the patient back to cardiology for activating the pacemaker program again.”

“There is a form that accompanies the patient, which the cardiologist signs at after activating the safe scan mode, and the technologist signs when the scan is done without any problems. Then the patient goes back to cardiology, the MRI-safe mode is switched off, and the cardiologist signs again and sends the form back to our department. In this way we know that everything was okay.”

MRI of patients with an MR Conditional implant has become a routine procedure at Dr. Schwitter’s institute. “We do this



quite often, several times per week. During the two to three years we have now used this procedure, there was not a single complication.”

### **The MRI scan itself: how to meet the conditions**

“If the device is MR Conditional, safe imaging is possible, but only when the implant’s MR conditions are fulfilled. However, even when you know the conditions, it can still be challenging to control these during the MRI imaging,” says Dr. Sommer. “A radiologist or technologist must know how to achieve that on the scanner and how to check that.”

“The MR conditions are basically a list of parameter values that need to be met,” says Dr. Sherlock. “They first define the static magnetic field strength and frequency that are acceptable. But there are also limits for the SAR value and possibly gradient limitations (slew rate or dB/dt). That information is identified and confirmed prior to scanning the patient. It’s also necessary to determine if any special conditions must be met with regard to the type of transmit coil that’s used.”

“MR users need to make sure that the particular conditions can be met. In the USA it is usually the MRI technologist who has to make sure that scanning parameters are properly selected to meet the conditions for a particular cardiac device and, but I think it’s often a challenge on how exactly to do that.”

Dr. Sommer shares this view. “The radiologist or technologist has to know how to control that the implant’s MR conditions are met, for instance SAR and gradient limits, and actually, that is not easy. I’m very glad that MRI companies are working on the subject and offer a user interface such as Philips ScanWise Implant to make it easier for users to control the relevant MR parameters for safe scanning of patients with these MRI Conditional devices.”

### **Guided workflow to simplify scanning of patients with implants**

“I see MRI equipment manufacturers willing to help out and becoming more of a partner with the MRI healthcare workers with regard to situations where implants are present,” says Dr. Sherlock. “The Philips ScanWise user interface is a great tool.”

Philips has developed ScanWise Implant to simplify scanning of patients with MR Conditional implants. It guides the user when entering the implant’s conditional MR values. Values such as maximum spatial gradient field, SAR, B1+rms, dB/dT or slew rate can be entered as specified by the implant

**“It’s of great help that Philips ScanWise Implant offers a user interface that makes it easy for the user to make the MRI scanner meet the implant’s conditions.”**

vendor, without the need for side calculations. It provides a graphical representation of the area exceeding the maximum spatial gradient field value to help guide the MR operator to position the patient in the scanner’s bore. ScanWise Implant automatically applies these values for the entire examination. There is no need to check each individual sequence.

### **Are radiology departments ready?**

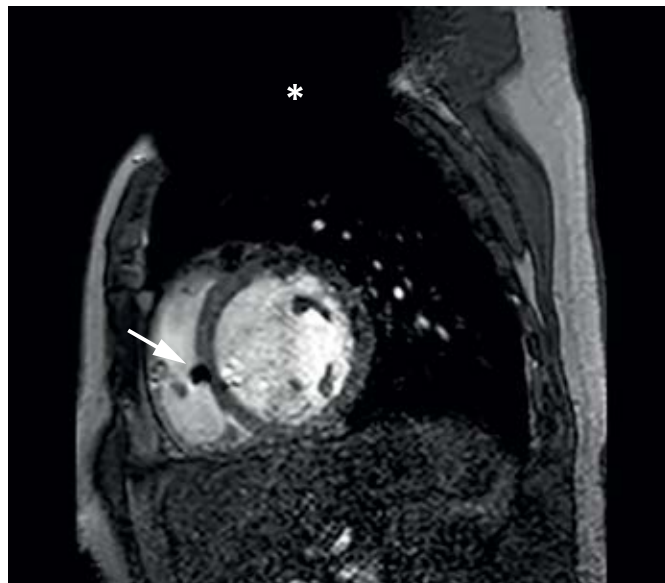
With the increasing prevalence of implants in an aging population, and increasing demand for MRI in the same group, there will increasingly be called upon imaging centers to be capable of scanning this patient group. Opening up the possibilities for patients with MR Conditional implants in need of an MRI scan requires educational initiatives for changing the perception that implanted cardiac devices are always a contraindication for MRI.

Recognizing that a significant barrier for scanning MR Conditional device patients is the care pathway, Medtronic offers tools and training to assist hospitals, according to Dr. Kowal. Facilitating collaboration between cardiology and radiology, the company assists in helping institutions implement a care pathway that works for that location.

### **Getting started involves three things**

“In Germany information and education on performing MRI of patients with active cardiac devices is available to those who look for it. The joint consensus paper of the German Roentgen Society and the German Cardiac Society provides physical and electrophysiological background information and specific recommendations for the management of patients with cardiac devices, outlining the responsibilities of radiology and cardiology regarding patient education, indications, monitoring and device reprogramming,” says Dr. Sommer.

“In the end, I think three things are important for safe and successful MR imaging of patients with active MR Conditional cardiac devices. First, verification that the device is MR Conditional and knowing the exact conditions of use. Second, establishing a pathway for managing the patient in close collaboration between radiology and cardiology. Then third is controlling – meaning monitoring and modifying if necessary – the safety-relevant physical MR parameters to make sure that the implant’s conditions of use are met during MRI scanning. In this context it’s of great help that Philips ScanWise Implant offers a user interface that makes it easy for the user to make the MRI scanner meet the implant’s conditions.” <<



### **MRI of heart with MR Conditional ICD**

A patient with an MR Conditional ICD and suspected myocarditis presented for MRI. This short axis view of the heart is created with an SSFP (steady state free precession) sequence on a Philips Achieva 1.5T system. The cardiac MRI exam reveals normal dimensions and regular function of the right and left ventricle. Note the ICD lead in the right ventricle (arrow) and the signal void in the left pectoral region, indicating the ICD-IPG (asterisk). Courtesy of Dr. Sommer.

### **References**

1. ASTM F2503-13. ASTM International, West Conshohocken, PA, 2013
2. *Scanning patients with MR Conditional implants*. Philips FieldStrength; 2015.
3. Kalin R, Stanton MS. *PACE* 2005;28:326-328.
4. Gimbel JR, Bello D, Schmitt M, et al. *Heart Rhythm*. 2013;10:685-91.
5. Shenthar J, Milasinovic G, Al Fagih A, et al. *Heart Rhythm*. 2015;12:759-65.
6. Wollmann CG, Thudt K, Kaiser B, et al. *J Cardiovasc Magn Reson*. 2014;16:30
7. Schwitter J, Gold MR, Al Fagih A et al. *Circ Cardiovasc Imaging*. 2016;9: pii: e004025.
8. Schwitter J, Kanal E, Schmitt M et al. *Heart Rhythm*. 2013;10:864-72
9. Colletti P, Shinbane J, Shellock FG. *Am J Roentgenol* 2011;197:457-459.
10. Shinbane J, Colletti P, Shellock FG. *J Cardiovasc Magn Reson*. 2011;13:63.
11. Luechinger R, Schwitter J, Bruder O. *Protocol for MR-conditional PMs or ICDs*. CMR-Update, 2nd ed. 2012, p38, Lausanne, Switzerland, www.herz-mri.ch
12. Sommer T, Luechinger R, Barkhausen J et al. *Rofo*. 2015;187: p781-782.
13. Sommer T, Bauer W. et al. *Fortschr Röntgenstr* 2017; 189: p211-212
14. Indik JH, Gimbel JR, Abe H, et al. 2017;14(7):e97-e153.

# MultiBand SENSE widens possibilities for fMRI and dMRI in brain

## A response to the growing need for better, faster functional and diffusion MRI in the brain

The wealth of information from functional and diffusion MRI data has activated a large amount of neuroscience research and led to a demand for even more diffusion data and higher temporal resolution in functional MRI, with full brain coverage and in acceptable scan times. This inspired development of a next generation of acceleration: MultiBand SENSE can now accelerate functional and diffusion imaging without compromising image quality. It uses multi-band excitation to acquire multiple slices simultaneously, and reconstruct the individual slices using sensitivity encoding.

MultiBand acceleration factors of up to 8 are possible for BOLD fMRI, which enables better spatial and temporal resolution in scans that need to be performed quickly.

### Accelerated imaging with excellent resolution for fMRI and dMRI

Over the last decade we have seen a wave of research using MR methods, yielding new discovered insights with potential value in a broad area of neurological diseases and mental disorders. To expand their studies, neuroscientists were craving for improved MR capabilities to resolve more detail in their studies.

Functional and diffusion MRI (fMRI and dMRI) are often used by neuroscientists for visualizing disruptions or abnormalities in connectivity pathways, for instance in research into early recognition of central nervous system disorders, such as depression, bipolar disorder, Huntington's disease, and Alzheimer's disease [1-4]. The high incidence of such diseases drives advancement in identifying biomarkers to quantify and identify treatment influence.

The use of MultiBand SENSE is embraced by these neuroscientists as its acceleration helps for studying function and connectivity in the brain. It allows to obtain a high temporal resolution in BOLD fMRI. And the additional possibility to

perform multi-echo acquisitions at the same time enables differentiation between actual brain activation signals and other physiologically influenced signals coming from breathing, heartbeat, or head motion. This may help to "clean up" the functional brain images and thus visualize details that were previously difficult to image. This could find its use in visualizing disease and monitoring patient responses to treatment.

According to Joel Steinberg, MD, having a capability like MultiBand SENSE is almost essential for institutions to meet demanding imaging criteria needed to participate in multi-center clinical studies requiring high imaging specifications within strict time limits.

***“MultiBand SENSE has greatly improved temporal and spatial resolution, while maintaining full brain coverage”***

## The principle of MultiBand SENSE

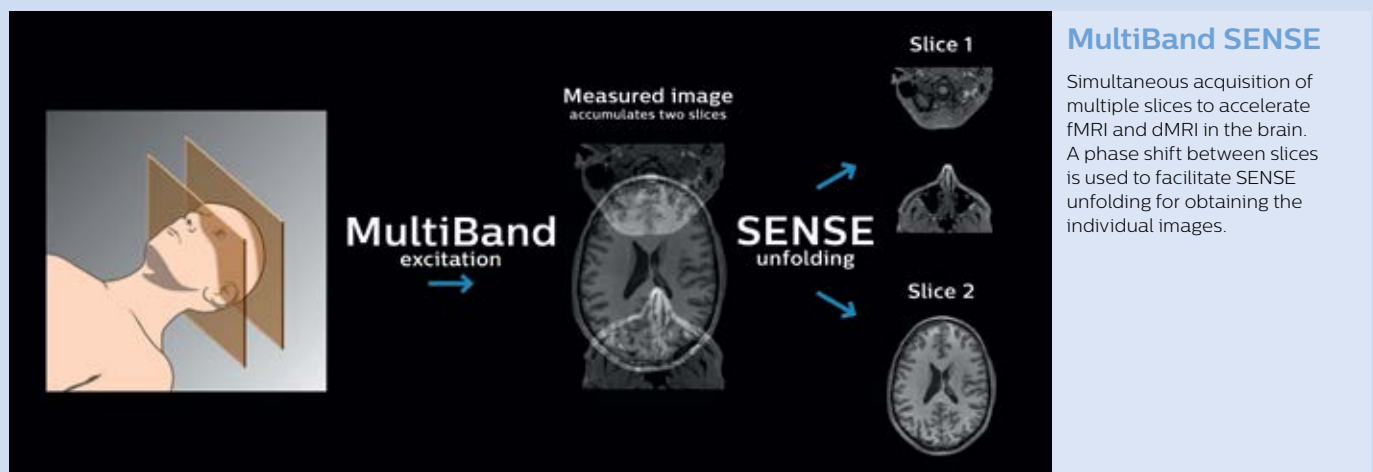
# Simultaneous slice excitation and sensitivity reconstruction

MultiBand SENSE starts with the simultaneous excitation of two or more slices, while the acquisition readout is unchanged. So, the base resulting image is actually an accumulated image of all excited slices. However, similar to normal SENSE algorithms, the signal can be unfolded to reveal the separate images.

This unfolding can be complicated when coil sensitivity profiles are similar for the separate slices. Therefore, the MultiBand SENSE technique employs a phase shift during

excitation to simplify the unfolding process, and virtually eliminate artifacts generated by residual aliasing and noise enhancement [5].

The result is that MultiBand SENSE can acquire multiple slices in a time identical to that of a single slice acquisition, which thus provides a significant acceleration. The acceleration is chosen via the MultiBand SENSE factor that indicates the number of simultaneously acquired slices, which is always an integer number.



## Practicalities of using MultiBand SENSE

- For BOLD fMRI, up to 8 slices can be acquired simultaneously with MultiBand SENSE. The distance between these slices should be kept large enough by ensuring sufficient coverage in the slice direction to prevent noise and signal leakage during unfolding.
- A further advantage is that MultiBand SENSE can be combined with in-plane dS SENSE, enabling high spatial and temporal resolution, respectively. At the same time there is less distortion because of the reduced EPI readout. A correctly tuned balance of dS SENSE and MultiBand SENSE is essential, since both use the same sensitivity encoding algorithm. This balancing will depend on the required spatial resolution, coverage, image quality, and temporal requirements of the acquisition.
- In addition, multi-echo can be used in the same MultiBand SENSE acquisition, which allows neuroscientists a more in-depth analysis. In this

advanced analysis, signals can be determined to be proportional to echo time (or not), indicating whether these signals are actual functional related changes or relate to spatial B0 variations respectively.

- In diffusion MRI, not only the 90° excitation pulse, but also the 180° refocusing pulses are slice dependent when using MultiBand SENSE. This has two significant consequences. First, the bandwidth of these complex multislice 180° pulses limits the maximum acceleration factor to 4. And secondly, SAR is increased due to the combination of high bandwidth 90° and 180° pulses.
- Scan time reduction and increased angular resolution are desired by dMRI users. In diffusion imaging, a shorter minimum TR becomes possible with MultiBand SENSE, which allows using a larger anatomical coverage and a higher number of diffusion directions. For DWI and DTI, MultiBand SENSE can result in up to 73% reduction of scan time compared with normal diffusion scanning. >>



**Joel L. Steinberg, MD**, is a psychiatrist at the Institute for Drug and Alcohol Studies at the Virginia Commonwealth University (Richmond, Virginia, USA) and is the director of the Collaborative Advanced Research Imaging Program at the Wright Center for Clinical and Translational Research. His research interests include using fMRI and DTI to examine the basis of neurological afflictions, including addiction, MS, and cognitive impairment.

*“Time is of the essence, most subjects cannot tolerate staying in the scanner too long for an fMRI task”*

## Boosting fMRI to unravel the neurological basis of addiction

The Institute for Drug and Alcohol Studies at VCU is involved in research on addictions, other branches of psychiatry, research programs on traumatic brain injury and several large multi-center studies, including the ABCD study. “So, we use a lot of fMRI and also a good amount of diffusion imaging here,” says Dr. Steinberg. “I think MultiBand SENSE is an excellent technique for getting better temporal and spatial resolution from fMRI and dMRI scans that would otherwise be almost impossible to perform on patients, because of time considerations.” In studies examining the neurological basis of drug and alcohol addiction, BOLD functional imaging is used for characterizing brain functional connectivity abnormalities in substance abusers versus normal controls.

MultiBand SENSE helps Dr. Steinberg increase temporal resolution in BOLD fMRI. “In event-related fMRI, it’s favorable to get very frequent acquisitions, in order to obtain a better sampling of the brain’s physiological activity over time. With a MultiBand factor of 6 we can get a TR of only 800 ms. Without MultiBand, our TR would be much higher. So MultiBand SENSE gives us a huge improvement in SNR, as it allows us to get more acquisitions during the same period of time. And time is of the essence, because most subjects cannot tolerate staying in the scanner for too long while performing an fMRI task.”

“For children, we try to keep the scans to 5 minutes each. We try to get 8 minutes for adults, but certainly no scan is longer than 10 minutes. Within these limited time periods, MultiBand SENSE has greatly improved our temporal resolution, while maintaining an excellent isotropic spatial resolution of 2.4 mm and 60 slices; that’s excellent full brain coverage.”

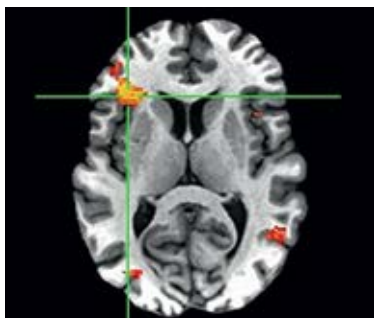
Dr. Steinberg adds that before using MultiBand SENSE, fewer acquisitions were being made with a poor temporal resolution of

2,300 milliseconds. However, using MultiBand SENSE now, “we’re able to improve the temporal resolution, SNR, spatial resolution, and still get full brain coverage, without making time too long for the research subject.”

### Towards higher detail in structural brain connectivity imaging

“With diffusion methods we’re looking for the effects of various substances of abuse on pathology in the white matter tracks, such as decreased white matter integrity as measured by changes in the diffusion parameters across the axon membrane, and also changes in the diffusion along the axis of the white matter track,” says Dr. Steinberg. “So in general, the better spatial resolution is, the better we can characterize tracks and tease apart the different tracks that may be passing through a single voxel. Crossing fibers that are not resolved may produce incorrect values for that voxel, falsely suggesting abnormality. These could throw off the whole endeavor of white matter tracking technology.”

Dr. Steinberg notes several improvements that MultiBand SENSE provides for these structural connectivity measurements. “Our diffusion quality is excellent with a MultiBand SENSE acceleration factor of 4. We get 1.7 mm isotropic spatial resolution and full brain coverage with 80 slices for imaging the white matter structural connectivity in the brain. Remember that we are limited by the time that a patient can tolerate staying in the scanner, but still we can get excellent spatial resolution, with a great number of gradient directions – 96 for example – which enables high angle resolution for our white matter connectivity studies. Without MultiBand SENSE, spatial resolution would be worse and we certainly wouldn’t be able to acquire as many gradient directions or b-values within the same period of time.”



### fMRI of viewing and matching facial expressions

BOLD fMRI activation, depicted in color, of left anterior insula (MNI plane  $z = 8$  mm) in a single subject by a contrast between viewing and matching faces with negative emotion (angry, sad, scared) versus happy faces. The voxelwise threshold is  $p < 0.001$ , and colored voxels survive false discovery rate correction to  $p < 0.05$ . The activated voxels in color are overlaid on the subject’s own 3D-TFE image displayed in grayscale, after transforming the data to MNI space. The fMRI pulse sequence was a single shot FFE echo planar acquisition using MultiBand SENSE factor 6, dS SENSE factor 1, isotropic voxel size 2.4 mm, 60 transverse slices, TR 950 ms, TE 30 ms, flip angle 52 degrees, 517 dynamic scans, total scan duration 8:21 minutes. Image provided by James M. Bjork, PhD, Associate Professor of Psychiatry at VCU.





**Matthan Caan, PhD**, is assistant professor and MRI physicist at the Academic Medical Center Amsterdam, The Netherlands. His research is into sparse imaging at high field and higher order diffusion modelling. He applies advanced neuroimaging protocols in clinical studies.

*“The high sampling rate possible with MultiBand SENSE now allows us to measure and filter out physiological noise in functional imaging data.”*

## Mapping brain activity in patients with eating disorders

At the Academic Medical Center (AMC) in Amsterdam, researchers want to examine resting state networks in the brain of anorexia patients as well as the differences in the brain’s responses to pictures of high- and low-caloric food items. Matthan Caan, PhD, researcher and MRI physicist at AMC, developed the fMRI protocol for this study, using MultiBand SENSE to accelerate it.

“Our aim was to sample faster than the cardiac pulsation, so we wanted to be able to shorten repetition time TR to 700 ms,” says Dr. Caan. “We achieved that by using a MultiBand SENSE factor of 6 resulting in a 6-fold acceleration. We could still get good spatial resolution also with these settings. The fMRI task length is approximately nine minutes, which sets the total protocol length.”

“The high sampling rate possible with MultiBand SENSE now allows us to measure and filter out physiological noise – using independent component analysis – in functional imaging data. We can then examine the BOLD signal really related to

the function of the brain and appreciate differences in strength and location of brain activation that occurs when the anorexia patients look at the high- or low- caloric food.”

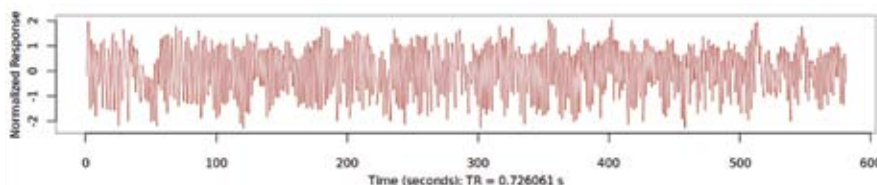
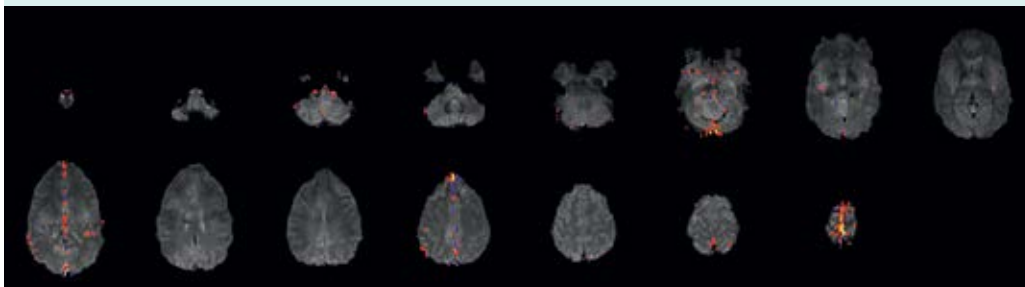
### More diffusion data in the same time

Dr. Caan indicates that also diffusion imaging benefits from MultiBand SENSE. “We can speed up imaging and acquire more data in the same amount of time. In other words, it provides more statistical power within the same measurement time, which helps to perform better model fits, and get more precise parameter estimates. Or we can perform studies with smaller groups, something that was not possible previously.”

According to Dr. Caan, the diffusion protocol with MultiBand SENSE uses four b-values up to b 2200, 164 gradient directions, 58 slices in 16 minutes. “In this protocol, we use a MultiBand SENSE factor of 3. We found this to provide our preferred homogeneous image quality, for instance when acquiring data in transverse orientation, and then looking at the coronal plane.” >>

### Measuring and filtering out physiological noise in fMRI

Physiological noise is an important source of unexplained variation in fMRI analyses. With MultiBand SENSE, sampling rates below one second become feasible. This allows for capturing cardiac and respiratory signals. These can be automatically determined and then filtered out using independent component analysis [6]. The fMRI pulse sequence was a single shot FFE echo planar acquisition using MultiBand SENSE factor 5, dS SENSE factor 1.25, isotropic voxel size 2.7 mm, 50 transverse slices, TR 700 ms, TE 30 ms, flip angle 52 degrees, 765 dynamic scans, total scan duration 9:01 minutes. Image provided by Matthan Caan, PhD, Assistant Professor at the AMC.





**Richard Watts, PhD**, is Co-Director of the University of Vermont MRI Center for Biomedical Imaging, and an Associate Professor in the Department of Radiology. His academic interests include T1-weighted imaging in multiple sclerosis, Alzheimer's disease, brain tumors, multimodal imaging of mild traumatic brain injury (mTBI), therapeutic hypothermia, and imaging connectomes using high b-value diffusion imaging.



**Hugh Garavan, PhD**, is a cognitive neuroscientist at the University of Vermont. With a background in cognitive psychology, his primary interests are in understanding the neurobiology of cognitive control functions. He uses structural and functional MRI to study individual differences and psychopathology with a specific focus on addiction and adolescent development.

## High demands for visualizing adolescent brain connectivity

The University of Vermont (UVM) is one of the research sites participating in the Adolescent Brain and Cognitive Development (ABCD) study\* of long term brain development. This multicenter study of brain development and child health aims to recruit 10,000 children ages 9-10 and following them into adulthood, and integrating structural and functional brain imaging with genetics, neuropsychological, behavioral, and other health assessments. The study includes detailed structural and functional brain MR imaging at different ages, according to a standardized protocol. UVM employs MultiBand SENSE technology to perform diffusion imaging and fMRI that meet the advanced specifications of the study [8].

Richard Watts, PhD, Co-Director of the UVM MRI Center for Biomedical Imaging, explains how MultiBand SENSE aids him in diffusion imaging: "For the ABCD study, we have really high specifications, including the use of high b-values and many diffusion directions. At the same time, we need to acquire all these data in less than 10 minutes – something that we couldn't do without using MultiBand SENSE."

According to Dr. Watts, MultiBand SENSE also helps to meet the needs for fMRI "We're imaging six times faster for functional MRI, with the option to move this up to eight. This means we can really push spatial and temporal resolution."

According to Dr. Hugh Garavan, UVM would not have been able to participate in the ABCD study if they had not had MultiBand SENSE: "Having MultiBand SENSE in the protocol means UVM can play a role in what is probably one of the largest child development studies ever attempted."

***"We're imaging six times faster for fMRI. This means we can really push spatial and temporal resolution"***

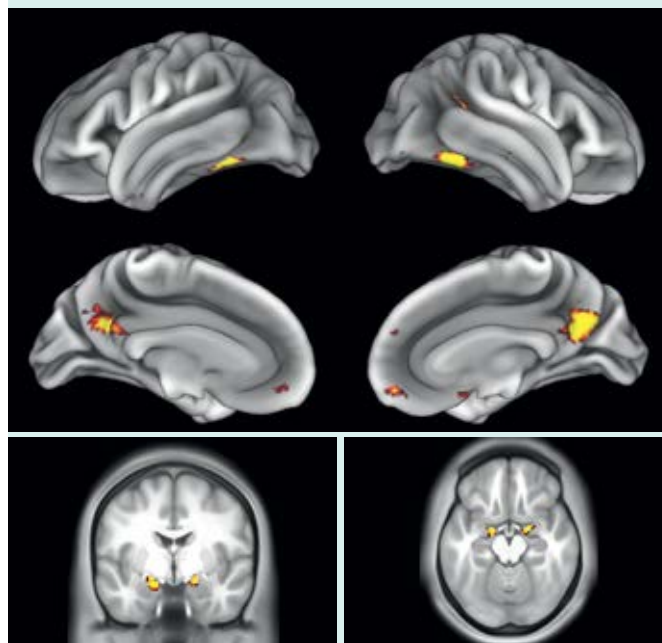
### fMRI test of faces and places

Emotional n-back task combines a test of working memory with the use of emotive (faces) and neutral (places) images. The contrast in the images is between the activity when faces are presented compared to places, showing activation in the amygdala, fusiform, and occipital face areas.

Processing based on the Human Connectome Project (HCP) pipelines. The high resolution of the fMRI data allows extraction of the cortical surface, with minimal averaging of non-cortical signal. Surface based analysis provides improved cross-subject alignment, and prevents signal contamination between adjacent sulci.

Group analysis of 88 9- and 10-year olds part of ABCD, all scanned at UVM on Philips Achieva 3.0T dStream. Scale runs from red p<0.001 to yellow p<10<sup>-5</sup>.

Images provided by Dr. Watts.



Acquisition using the ABCD protocol for fMRI with TR 800 ms, TE 30 ms, flip angle 52°, 2.4 mm isotropic imaging resolution with a 216×216×144 mm<sup>3</sup> field of view using a MultiBand acceleration factor of 6 (60 slices, no gap). Two runs of 5 minutes per subject.

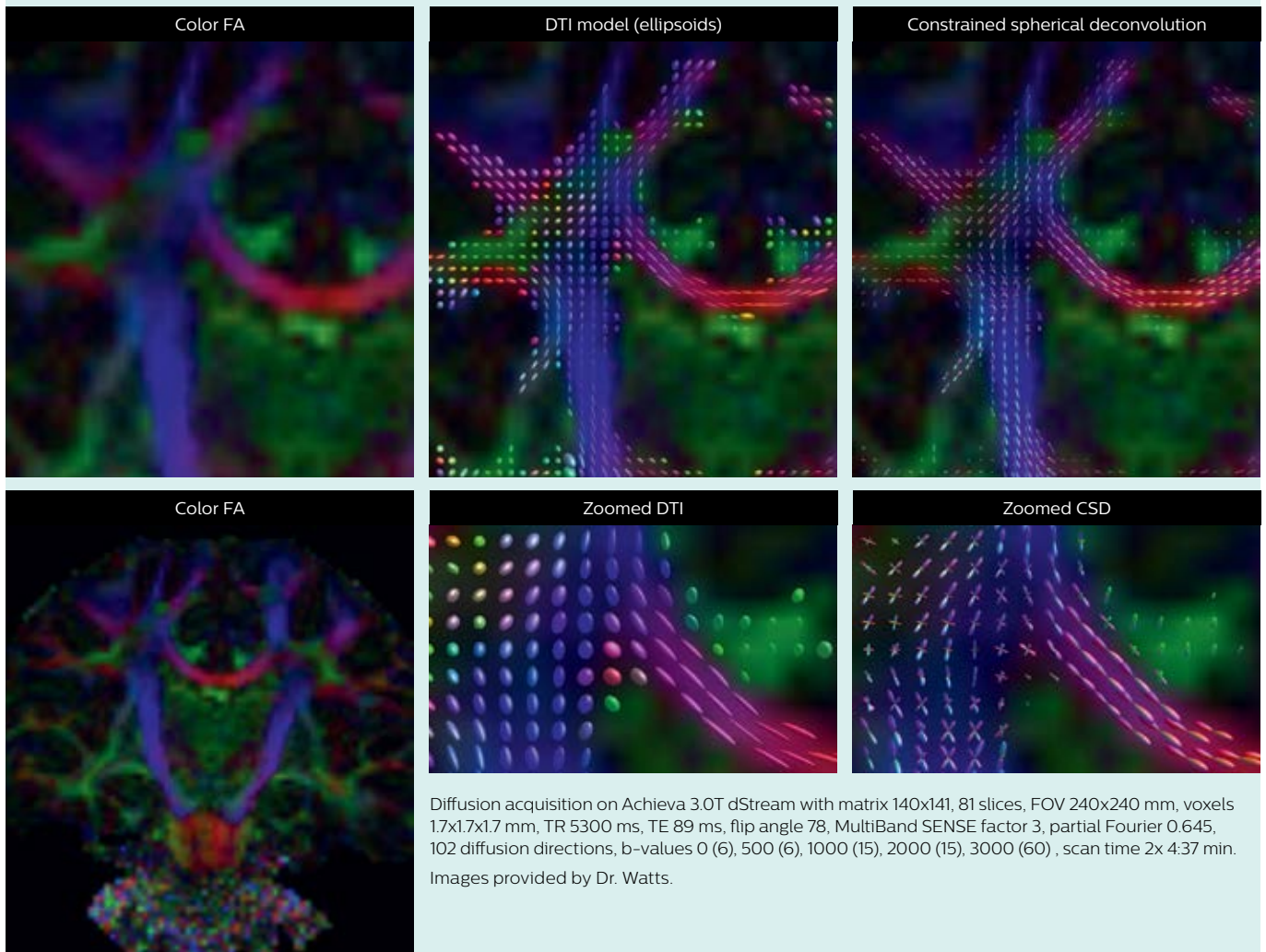
*“I would definitely recommend to anyone working with fMRI to seriously consider using MultiBand SENSE”*

*“We can speed up diffusion imaging and acquire more data in the same amount of time”*

### Advancing diffusion MRI

These images are produced using the ABCD protocol and illustrate the use of more sophisticated and accurate models of diffusion. The color FA maps are shown for reference. The diffusion tensor model represents the diffusion within each voxel as an ellipsoid.

Alternative models, such as constrained spherical deconvolution, better capture the rich information available with the use of high b-value dMRI and many sampling directions. In much of the brain, voxels contain multiple white matter tracts, and it is essential to capture this information to be able to perform accurate tractography and generate diffusion connectomes.





**Juan Domingo Gispert**, is head of Neuroimaging at the BarcelonaBeta Brain Research Center, Pasqual Maragall Foundation. His research interests combine development of neuro image acquisition and analysis techniques with their application in studying the aging and diseased brain. His group is focusing on detection of cerebral alterations in preclinical stages of Alzheimer's disease.

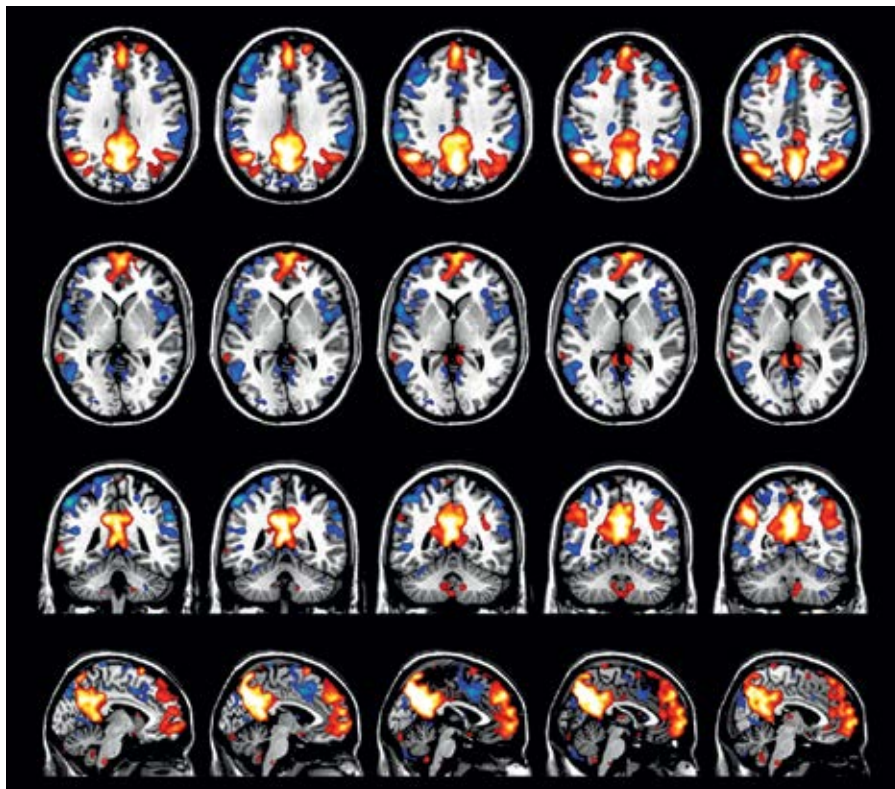
*“We use MultiBand SENSE to double the amount of scans we acquire in a fixed amount of time”*

## Studying preclinical Alzheimer’s disease with MRI

Dr. Juan Domingo Gispert of the Barcelonabeta Brain Research Center, at the Pasqual Maragall Foundation, says there is converging evidence of a preclinical stage of Alzheimer’s disease (AD). “This means that even 20 years before the onset of symptoms, specific cerebral pathology might be already present in some individuals. Being able to identify individuals at risk of developing AD in the future, and trying to implement preventive strategies to avoid or delay the onset of the actual symptoms, is the ultimate goal of our research. Nowadays, patients at risk for cardiovascular disease – individuals with hypertension or high blood cholesterol – receive drugs in order to bring those risk markers back to normal. We have the same vision for managing Alzheimer’s disease in future.”

Pasqual Maragall, former mayor of Barcelona, created the foundation when he was diagnosed with Alzheimer’s disease himself. He believed that research is the only way to fight and hopefully defeat the disease at some point in future. “This involvement of a public figure, that people trust and rely on, was crucial in recruiting participants for our study. We had virtually thousands and thousands of people volunteering to participate,” says Dr. Gispert.

To better understand the preclinical stage of AD, the research center established a cohort of almost 3,000 healthy individuals, most of which are adult children of Alzheimer’s disease patients, who regularly undergo clinical and cognition tests and surveys.



**Resting state fMRI**

Default mode network as discovered by resting state fMRI in one participant of the ALFA cohort [7]. rs-fMRI allows us to find networks of brain regions with highly correlated activity and sustaining distinct brain functions. The default mode network (in warm color scale) is active when the brain is focused on introspective thinking and has been shown to be altered in Alzheimer’s. Interestingly, brain areas of this network are known to show abnormal levels of one of the pathological hallmarks of Alzheimer’s (b-amyloid deposition) in preclinical stages. We want to better understand the alterations of these brain networks in preclinical stages of Alzheimer’s and explore their potential use as biomarkers.

Imaging was performed using Ingenia 3T CX with a 32ch dS Head coil, TR 1.6 sec, TE 35 ms, voxel size 3.1 x 3.1 x 3.1 mm, 46 slices and Multiband SENSE factor 2.

Image provided by Dr. Gispert.

## More fMRI data in same time thanks to MultiBand SENSE acceleration

“Neuro imaging is very central to our research. Approximately 2,000 volunteers are eligible for MRI scanning, says Dr. Gispert. “MRI is used every three years to examine morphology, vascular lesions, as well as structural and functional connectivity. The basic protocol includes fMRI and a DTI sequence. And the question is always, how to get the most detailed information, with the different sequences, in a fixed amount of time. MultiBand SENSE can help us there.”

“We perform a resting-state fMRI sequence in all individuals of the cohort. Because of the vascular dynamics of resting-state in the brain, we feel it doesn’t make sense to go to shorter acquisition. So, we use MultiBand SENSE to double the amount of scans we acquire in a fixed amount of time. We are extremely happy with the quality we get for retrieving the default mode network. In about eight minutes, we acquire 300 volumes of 46 slices with an isotropic voxel size of 3 mm and a TR of 1.6 ms.”

“We have optimized all our protocols to allow quantitative analysis. Another important aspect is to use a field of view large enough to allow whole brain scanning for all 2,000 participants in the cohort, because total intracranial volume has been suggested to be a relevant factor in Alzheimer’s disease.”

## Clinical implications and next steps for MultiBand SENSE

Developing faster MRI is one of the key elements in creating the possibility to offer MR to more patients, a key objective in our vision at Philips. With the launch of SENSE, Philips was the first vendor to bring parallel imaging to the market. Continuous further innovations have resulted in the powerful dS SENSE and Philips MultiBand SENSE that can be combined with dS SENSE and multiecho offering great flexibility.

Neuroscientists using MultiBand SENSE in their fMRI and diffusion studies already see it can have a great impact. “I would definitely recommend to anyone working in the fMRI or diffusion imaging fields to seriously consider using MultiBand SENSE,” says Dr. Steinberg. Dr. Caan concurs: “My expectation is that MultiBand SENSE will be the default method of acquiring functional and diffusion data in studies from now on. I think it would reduce imaging time for protocols with the same parameter settings.”

Dr. Gispert is very satisfied with the progress made by implementation of MultiBand SENSE and the support offered by the global Philips clinical science network. “I would strongly recommend MultiBand SENSE to others doing research in neuroscience. In our case, our link to the Philips Clinical Science network has also been important, because the team helped us tailor the technical abilities of the scanner to our specific research project.” <<

## MultiBand SENSE to speed up diffusion or go for more detail

“In our study, we use a standard sequence for diffusion. MultiBand SENSE helps us here to reduce the acquisition time of the diffusion sequence, and thus allowing us to spend some extra time of our MR protocol on other sequences, for example for acquiring high resolution anatomical images of the hippocampus. We are extremely interested in looking at very subtle abnormalities in the hippocampus in individuals, who are cognitively intact.”

Some of Dr. Gispert’s colleagues use MultiBand SENSE for extensive diffusion imaging studies. “The great thing about MultiBand SENSE is that in a relatively short time – within 20 minutes – we can run very detailed DTI sequences providing multi-shell diffusion data in well over 100 different directions. That really opens ways to studying brain connectivity in a very detailed manner and link that to functional connectivity, both in healthy brain and for psychiatric conditions”

To summarize, Dr. Gispert says: “MultiBand SENSE helps us in two ways: one is that we acquire more data in a given amount of time, which allows us to find subtle changes in the preclinical stages of Alzheimer’s disease. Second, MultiBand SENSE allows us to scan the whole brain for every participant in the cohort; this helps us avoid selection bias.”

## References

1. Nir TM, Jahanshad N, Toga AW, Berstein MA, Jack CR Jr., Weiner MW, Thompson PM. *The Alzheimer’s Disease Neuroimaging Initiative (ADNI). Connectivity network measures predict volumetric atrophy in mild cognitive impairment.* Neurobiol Aging. 2015;36:S113–S120.
2. Shaffer JJ, Ghayoor A, Long JD, Kim RE, Lourens S, O’Donnell LJ, Westin CF, Rathi Y, Magnotta V, Paulsen JS, Johnson HJ. *Longitudinal diffusion changes in prodromal and early HD: evidence of white-matter tract deterioration.* Hum Brain Mapp. 2017;38:1460–77.
3. Wang T, Shi F, Jin Y, Yap PT, Wee CY, Zhang J, Yang C, Li X, Xiao S, Shen D. *Multilevel deficiency of white matter connectivity networks in Alzheimer’s disease: a diffusion MRI study with DTI and HARDI models.* Neural Plast. 2016;2016:2947136.
4. Wang Y, Wang J, Jia Y, Zhong S, Niu M, Sun Y, Qi Z, Zhao L, Huang L, Huang R. *Shared and specific intrinsic functional connectivity patterns in unmedicated bipolar disorder and major depressive disorder.* Sci Rep. 2017;7:3570.
5. Setsompop K, Cohen-Adad J, Gagoski BA, Raij T, Yendiki A, Keil B, Wedeen VJ, Wald LL. Neuroimage. 2012 Oct 15;63(1):569–80. doi: 10.1016/j.neuroimage.2012.06.033
6. Beckmann CF. *Modelling with independent components.* Neuroimage [Internet] 2012;62:891–901. doi 10.1016/j.neuroimage.2012.02.020.
7. Molinuevo et al. *The ALFA project: A research platform to identify early pathophysiological features of Alzheimer’s disease.* Alz Dem. June 2016 Volume 2, Issue 2, Pages 82–92. doi 10.1016/j.trci.2016.02.003
8. ABCD study\* <https://addictionresearch.nih.gov/abcd-study>

\* Philips is not sponsoring this study.

# Enhancing **brain tumor MRI** with APT weighted imaging

## Confidence in differentiating low and high-grade brain tumors



**John Curran, MD**, Pediatric neuroradiologist and Director of Pediatric Neuroradiology, Phoenix Children's Hospital. His interests include imaging of pediatric brain tumors and imaging of epilepsy.



**Jeffrey H. Miller, MD**, Pediatric neuroradiologist and Vice Chair of Radiology for Research and Academic Affairs at Phoenix Children's Hospital. His academic affiliations include Clinical Assistant Professor of Radiology, University of Arizona College of Medicine, the Mayo Clinic-Scottsdale and the Barrow Neurological Institute at Phoenix Children's Hospital. His current research interests are functional MRI, MR connectomics, and brain PET-CT. He has lectured extensively on advanced pediatric MR imaging.

Amide Proton Transfer (APT) weighted imaging is an emerging MRI method that generates image contrast different from conventional MRI. APT weighted imaging is a chemical exchange saturation transfer (CEST) MRI method and its signal is based on the concentration of endogenous proteins and peptides typically present in high-grade brain tumor tissue. Therefore, APT weighted imaging does not require any contrast agent administration.

### **APT enriches diagnosis of brain tumor MRI**

Physicians at Phoenix Children's Hospital (PCH) have been studying the value of APT in clinical practice to investigate to what extent APT weighted imaging could be used in the diagnostic and post-therapy imaging of children with brain tumors. Their results suggest APT weighted imaging has the potential to provide higher confidence in determining both the grade of tumor and the extent of residual tumor post-surgery. Many treatment pathways rely on accurate determination of the aggressiveness or "grade" of tumors for the optimal selection amongst treatment options to offer the best possible care choice for patients.

### **Looking for improved confidence in brain tumor diagnoses**

MRI is widely used for visualizing primary brain tumors and secondary lesions in oncology patients. Still, there are cases where radiologists would like to have additional capabilities for their diagnosis, for instance in distinguishing high-grade and low-grade tumors with more confidence and ultimately for performing the numerous follow-up MRI exams without contrast

***"Some high-grade tumors demonstrate no gadolinium enhancement and certain low-grade tumors occasionally enhance"***

administration in children after brain tumor resection. In the United States alone, nearly 80,000 new cases of primary brain tumor are expected to be diagnosed in 2017, including more than 26,000 primary malignant brain tumors.[1] Gliomas represent 75% of all malignant tumors, and 55% of these are glioblastoma with 12,930 cases predicted for 2017.[1,2]

Given that incidence, and the impact of the correct diagnosis and appropriate treatment paths, oncologists and radiologists welcome innovative tools to support their current means and strategies. One of these may be adding APT weighted imaging to the MRI exam. APT contrast correlates with the presence of proteins and peptides that may be related to cell proliferation. Since cell proliferation is a feature of tumors, APT color maps can be useful in identifying and quantifying tumor tissue.[3,4]

### Tumor grading can affect critical decision making

The choice of treatment paths often strongly depends on the tumor grade. Common treatment options for high-grade tumors include surgical tumor resection followed by additional therapy such as radiation and or chemotherapy. Quick and decisive action is desirable in these cases as median survival for glioblastoma, for instance, is between 12.6 and 14.6 months, although longer rates have been reported.[8,9] Given the lower tumor growth rate of low-grade tumors, a range of potential treatment options exist for these cases. The selection of the most appropriate treatment is based on the balance of therapeutic benefits and side effects. At times, surveillance imaging may play a role while the choices of definitive therapy are being considered.[10]

MR imaging is often used by radiologists and physicians in estimating the grade of brain tumors, but there is sometimes still uncertainty.[9,11] Differentiating between low-grade and high-grade tumors is not straightforward, even for the highly experienced radiologist. Gadolinium enhancement is not always specific for tumor grade, as some high-grade tumors demonstrate no gadolinium enhancement and certain low-grade tumors occasionally enhance (e.g. DNET). Gadolinium enhancement also occurs in any area of a blood-brain barrier disruption, such as treatment-related injury.[12]

### The power of APT for grading brain tumors with MRI

While the gold standard for grading of gliomas is histopathology after biopsy, MRI is often used in monitoring glioma patients, and APT can be a valuable addition to the MRI exam in these patients. Tumor grade and APT signal have been observed to be commonly positively correlated: high-grade tumors tend to exhibit a high APT contrast.[12-15] APT images can be seen to visualize tumor with more emphasis than post-contrast images, resulting in a scan that may be easier to interpret. Scientific studies comparing tumor grades with APT signal in adult glioma suggest that APT can support tumor grading, separating high-grade from low-grade, even when traditional MRI is inconclusive.[5,13,14]

### APT may be a powerful addition to grade tumors with MRI

Dr. Jeffrey Miller, pediatric radiologist at PCH also noticed the relation between APT contrast and tumor grades in the studies done at his hospital. "In several cases we have seen a high APT signal in high-grade tumors and moderately increased APT signal in cases with intermediate and low-grade tumors that have the characteristic of high signal change on T2 and FLAIR, and no contrast enhancement."

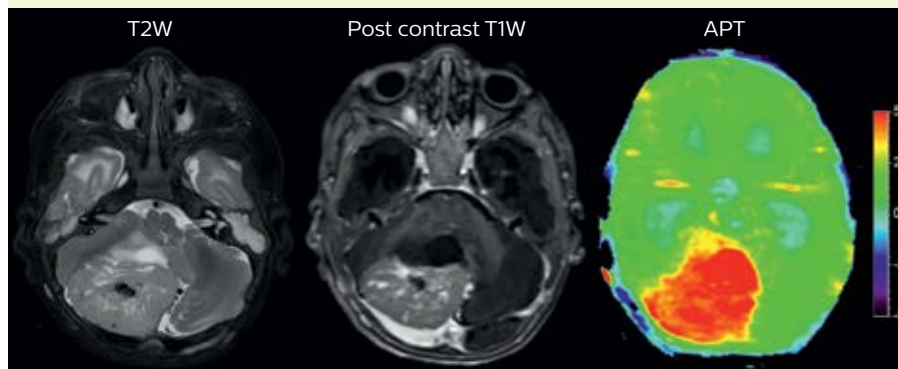
He points out the potential clinical implications of this observation. "When we're faced with patients where the diagnosis is a little bit ambiguous, we often have to make choices and value judgements, which could mean either just following up the tumor or lesion, with the risk that it could change when we were wrong and there could be time lost. Or we have to go into invasive situations where we have to biopsy."

"It would be very impactful and valuable to have a sequence like APT weighted imaging, which could assist us in making those decisions with more confidence. That would be meaningful for the individual patients and take out some ambiguity in what we are doing."

"However, in order to reach that lofty goal, we will need more investigation, use the sequence in a larger population, and gain more understanding of situations and conditions where APT has its maximal value." >>

### APT imaging of high-grade tumor

Tumor evaluation in a 1-year-old child with medulloblastoma. This aggressive tumor type is very solid and homogeneous. The high APT signal corresponds with the post-contrast image of this high-grade tumor.



*"It would be impactful to have a sequence like APT, which could assist us in making those decisions with more confidence"*

# APT reflects concentration of endogenous proteins in brain tumor

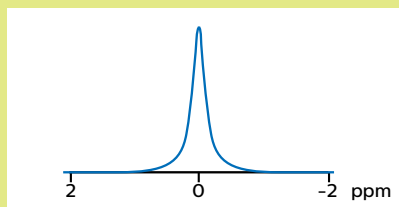
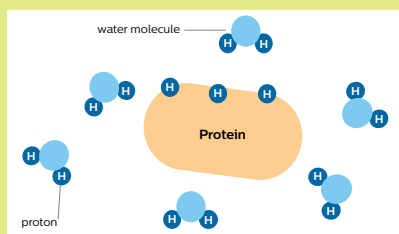
In APT weighted imaging and other CEST methods, the MRI signal is generated by a mechanism different from that of basic MRI. The signal of amide protons in peptide bonds of proteins is too low to be measured in normal MRI, but the hydrogen (proton) exchange between protein amide groups and surrounding water allows a different way to measure these amide protons.

In APT a narrow RF prepulse (saturation pulse) at the amide hydrogen's frequency is given to attenuate its MR signal. Because the amide group and water continually exchange hydrogen atoms, the number of saturated protons will build up in water, so

that the measured water signal will become lower. The change of the MRI signal of water provides an indirect way to measure the presence of amide. APT images are usually presented as color maps, created by using an asymmetry calculation so that presence of APT is shown as a positive colored signal.

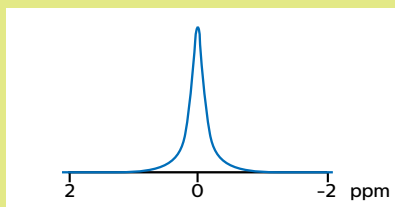
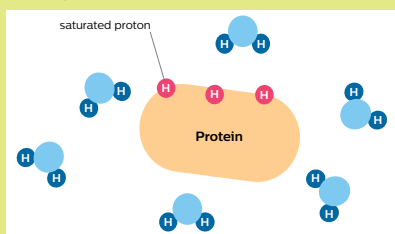
Studies have shown that the APT signal correlates with the concentration of a protein that is related to cell proliferation. The concentration of this protein, and thus the APT signal strength responds to the grade of malignant tumors.[5-7] APT contrast can potentially highlight tumors that wouldn't be seen otherwise.

Proteins with amide protons surrounded by water molecules that are moving around.



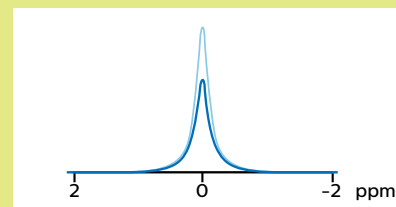
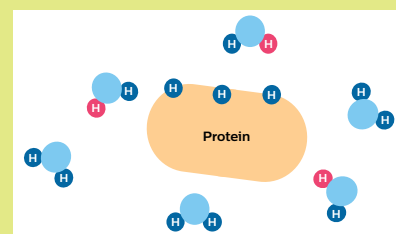
MR signal of water is high

Saturation prepulse on protein's amide proton frequency nulls MR signal of these protons



MR signal of water is high

As a result of chemical exchange the nulled protons move from the protein to water molecules.



MR signal of water is reduced due to the proton exchange. In APT, this signal change is used to calculate an APT map that is sensitive to the concentration of the protein.

## APT may illuminate post-resection images with crucial information

MRI may be performed after tumor resection, to look for residual tumor or tumor regrowth. Also here, the different contrast mechanism of APT may help in diagnosis. Dr. Miller remembers a particular case. "After a very good resection, we saw small changes on the post-contrast T1-weighted and the T2-weighted images that looked like a post-surgical little bit of fluid. Interestingly, however, we saw a focal area of APT signal, right in the center of that abnormality. As we usually do when a bit unsure, we followed it up and, unfortunately, found tumor regrowth in that region," Dr. Miller says. "Cases like this motivate me, and others who care about this population, to investigate how this APT method could be used on large scale in this population and help us in providing high value diagnostic information."

The hospital's physicians also saw a case where APT had a negative predictive value. Following the resection of a high-grade tumor, they saw a similar small change in the images of this patient. However in this case, the APT signal was rather low. In a recent rescanning of this patient, no recurrence was seen.

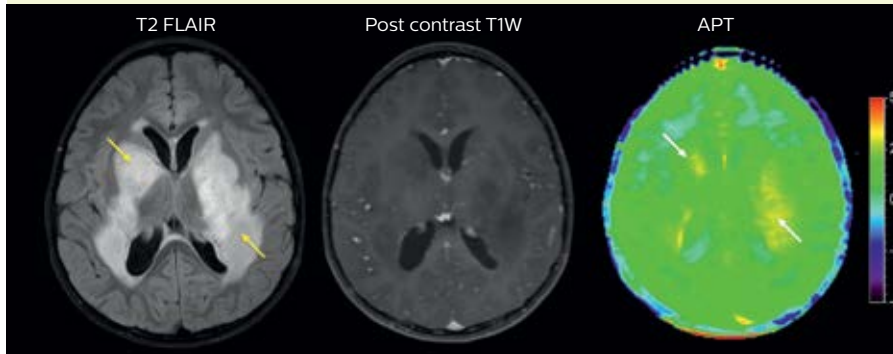
## APT MRI study encouraging for the youngest tumor patients

Radiologist John Curran, MD, has been the main researcher in studying APT weighted imaging at Phoenix Children's Hospital. "At this time, APT has been added to approximately 70 MRI studies of children with brain tumor and we have seen some encouraging early results," says John Curran, MD, radiologist at Phoenix Children's Hospital (PCH). "We will need larger studies with more patients to accurately assert the correlation. However, it doesn't need to be a 100% correlation to be useful in brain

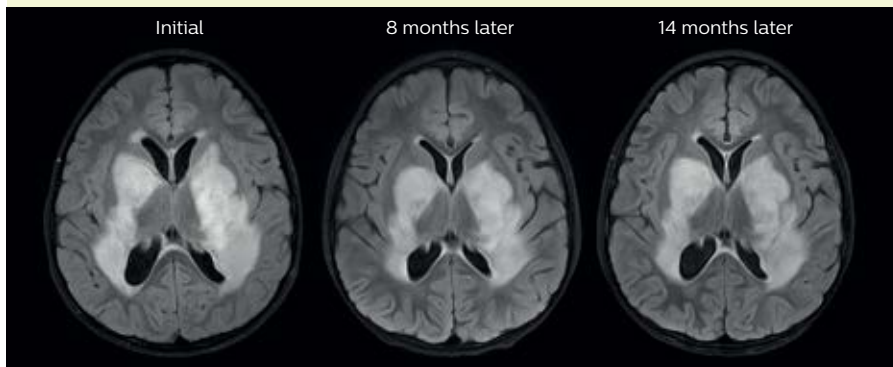


## APT imaging of low-grade tumor

Low-grade glioma in a 5-year-old patient with neurofibromatosis 1. This low-grade lesion does not enhance on the post-contrast images, but does show an intermediate APT signal. The lesion stability over time confirms that it is a low-grade pathology.



## Follow-up over time



*“Cases like this motivate me to investigate how this APT method could be used on large scale”*



tumor follow-up scans, because we also look at the FLAIR and at other images. The goal is to catch something before it gets too big, if it needs new surgery or new therapy and if we see something suspicious – as opposed to definite recurrence – it is often not a matter for immediate action, but for follow up.”

The PCH physicians involved in the trial overall express cautious optimism that APT weighted imaging may someday greatly reduce the need for contrast injection in pediatric patients. “If we can bring APT forward as a reasonable substitute, particularly in our follow-up brain tumor cases that would be of great benefit,” says Dr. Curran. “Use of contrast agent is tightly controlled in our general neuroradiology imaging, and contrast agent is only administered when it is really needed. So, our study focuses on determining if we in the future could use APT to diminish the use of contrast agents.”

## Promising results with APT inspire further plans

Dr. Curran has been comparing APT weighted imaging to post-contrast MRI in children with brain tumor history. “In many cases, we have seen that APT is positive when post-contrast T1-weighted imaging is positive. So, we’ve been trying to assess if that relationship holds up well enough to possibly use APT instead of giving a child contrast agent in certain circumstances.” The study uses APT research software that was developed by Philips in a research collaboration.

“Brain tumor MRI usually includes post-contrast imaging. So, in our young patient population, our concerns relate to the need to

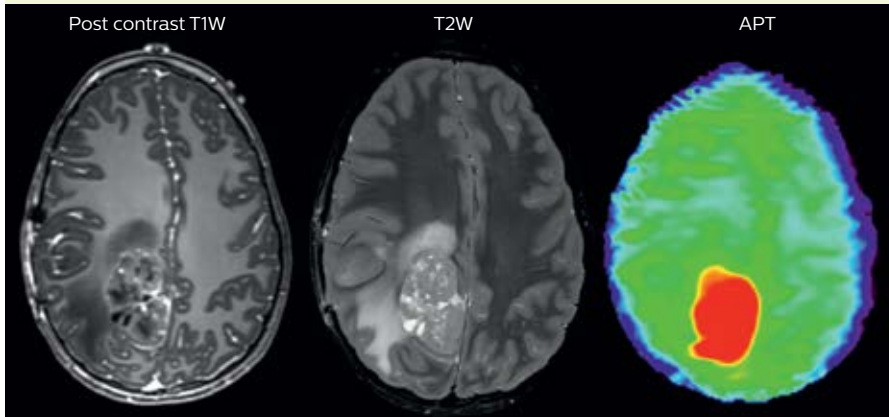
administer gadolinium-based contrast agent in follow-up scans in children after brain tumor resection. A study published by my colleague Dr. Miller showed that if a tumor is resected in a young child, by the time that child is at young adult age, an appreciable amount of gadolinium has been deposited in the brain.[16] APT does not require any contrast agent. So, if we can bring APT forward as a reasonable substitute, particularly in our follow-up brain tumor cases, that would be of great benefit.”

## Looking forward to further research on the potential of APT

According to Dr. Curran, the main APT research focus at PCH has so far been on investigating its capabilities in visualizing brain tumors and its potential for reducing the need for contrast. “We hope that APT in future can help us in further characterizing tumors with MRI, but more research will need to be done before we fully know what is possible and effective. By looking at specific aspects of tumors that are APT positive, we hope to correlate APT signal to more precise histology or tumor markers.” “We look forward to in future have a test to help us with the direction of therapy, such as choosing chemotherapy agents, plus or minus radiation and so forth. Perhaps APT may in future have a potential to help us there in some way,” Dr. Curran says. “The possibilities seem very broad.”

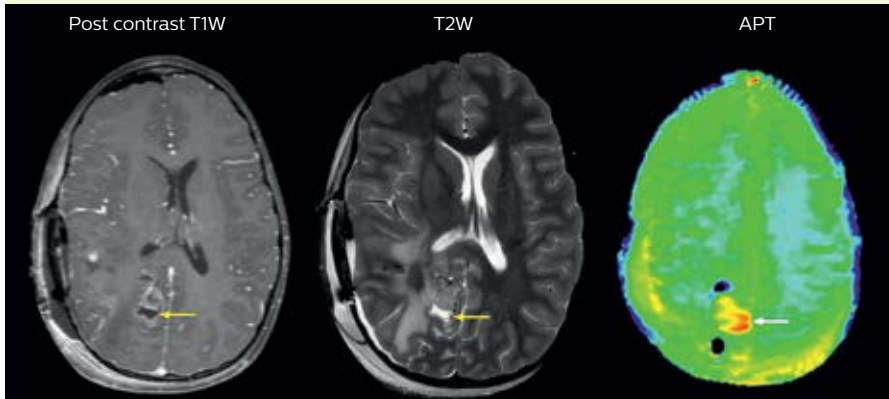
Dr. Miller concludes by summarizing “We’ve had some really good experience in using an APT method in a clinical situation. We have learned a lot in the process and see a lot of potential for it in the future.” >>

## APT in post-surgery evaluation



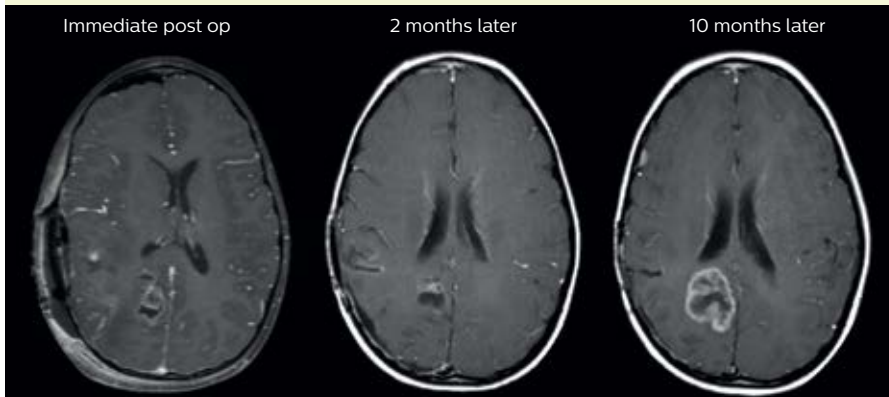### Large metastatic brain lesion

This 10-year-old patient underwent Ewing's sarcoma tumor resection 7 years ago, but was found to now have a large metastatic lesion in the brain. This lesion shows clearly increased APT signal.



### MRI with APT post resection

Immediately post resection MRI was again performed. T2-weighted and post-contrast T1-weighted images are quite inconclusive for distinguishing residual tumor tissue from postoperative tissue changes. On the APT image some high signal is still seen, which would suggest residual tumor tissue.



### Follow-up over time

In later follow-up scans the post-contrast T1-weighted images suggest recurrent tumor growth. So, it would be interesting to study the predictive value of APT in a large patient group.



## References

1. American Brain Tumor Association, *Brain Tumor Statistics*.
2. Central Brain Tumor Registry of the United States, *2016 CBTRUS Fact Sheet*.
3. Togao O, Hiwatashi A, Keupp J et al. *Amide Proton Transfer Imaging of Diffuse Gliomas: Effect of Saturation Pulse Length in Parallel Transmission-Based Technique*. PLOS ONE 2016.
4. Togao O, Keupp J et al. *Magn Res Med* 2017 77(6):2272-2279.
5. Togao O, Yoshiura T, Keupp J et al. *Neuro-Oncol* 2014; 16(3), 441-448
6. Jiang S, Eberhart CG, Zhang Y et al. *Eur J Cancer* 2017 83:9-18
7. Zhou J. *Magnetic Resonance Neuroimaging*. Methods in Molecular Biology (Clifton NJ, 2011), 711, 227-237.
8. American Brain Tumor Association, *Brain Tumor Information, Types of Tumors, Glioblastoma (GBM)*
9. Lobera, A et al. *Imaging in Glioblastoma Multiforme*. Medscape 2017.
10. Paleologos, N. *Low Grade Glioma: Update in Treatment and Care*. ABTA Patient and Family Conference, 2014.
11. Upadhyay N, Waldman AD, *BJR* 2011; 84: S107-S111.
12. Wen Z, Hu S, Huang F et al. *NeuroImage* 2010; 51(2), 616-622.
13. Park KJ, Kim HS, Park JE et al. *Eur Radiol* 2016, 26: 4390
14. Park JE, Kim HS, Park KJ et al. *Radiology* 2016, 278
15. Wang X, Yu H, Jiang S, Wang Y et al. Abstract #1105, ISMRM 2017.
16. Miller JH, Hu HH, Pokorney A et al. *Pediatrics* 2015;136:e1637.
17. Zhou J, Payen JF, et al. *Nature Medicine* 2003, 9:1085-1090
18. Zhou J, Lal B et al. *Magn Reson Med* 2003, 50:1120-1126
19. Jones CK, Schlosser MJ et al. *Magn Reson Med* 2006, 56:585-592

© Royal Philips N.V. 2018

All rights are reserved. Reproduction in whole or in part is prohibited without the prior written consent of the copyright holder.

Philips Healthcare reserves the right to make changes in specifications and/or to discontinue any product at any time without notice or obligation and will not be liable for any consequences resulting from the use of this publication.

Printed in Belgium.  
4522 991 36251

FieldStrength is also available via the Internet:  
[www.philips.com/fieldstrength](http://www.philips.com/fieldstrength)  
[www.philips.com/mri](http://www.philips.com/mri)  
[www.philips.com/netforum](http://www.philips.com/netforum)

**Editor-in-chief**

Karen Janssen

**Editorial team**

Annemarie Blotwijk, Paul Folkers (PhD),  
Liesbeth Geerts (PhD), Karen Janssen,  
Marc Van Cauteren (PhD).

**Contributors**

Faiza Admiraal (PhD), Jonas Bovin, Megan Breuer (PhD),  
Matthan Caan (PhD), John Curran (MD), Kristian Fogh,  
Hugh Garavan (PhD), Liesbeth Geerts (PhD),  
Juan Domingo Gispert, Frank Hoogenraad (PhD),  
Karen Janssen, Jan Kessenböhmer (MD), Harry Klijn,  
Robert Kowal (MD), Sandra Maass, Yoshitada Masuda (PhD),  
Jeffrey Miller (MD), Paula Montesinos (PhD), Amit Patel (MD),  
Jürg Schwitter (MD), Frank Shellock (PhD), Torsten Sommer  
(MD), Joel Steinberg (MD), Jeannette Brus Mortensen,  
Sabine Sartoretti (MD), Richard Watts (PhD), Tomio Yukawa.

**Subscriptions**

Please subscribe on [www.philips.com/fieldstrength](http://www.philips.com/fieldstrength)

**Correspondence**

[FieldStrength@philips.com](mailto:FieldStrength@philips.com) or  
FieldStrength, Philips Healthcare, Building QR 0119  
P.O. Box 10 000, 5680 DA Best, The Netherlands

**Notice**

FieldStrength is created for users of Philips MRI systems. It is a professional magazine for users of Philips medical equipment. It provides the healthcare community with results of studies performed by colleagues. Some articles in this magazine may describe research conducted outside the USA on equipment not yet available for commercial distribution in the USA. Some products referenced may not be licensed for sale in Canada.

Results from case studies are not predictive of results in other cases. Results in other cases may vary. Results obtained by facilities described in this issue may not be typical for all facilities. Images that are not part of User experiences articles and that are not labeled otherwise are created by Philips.

# Stay in touch

## with Philips MRI

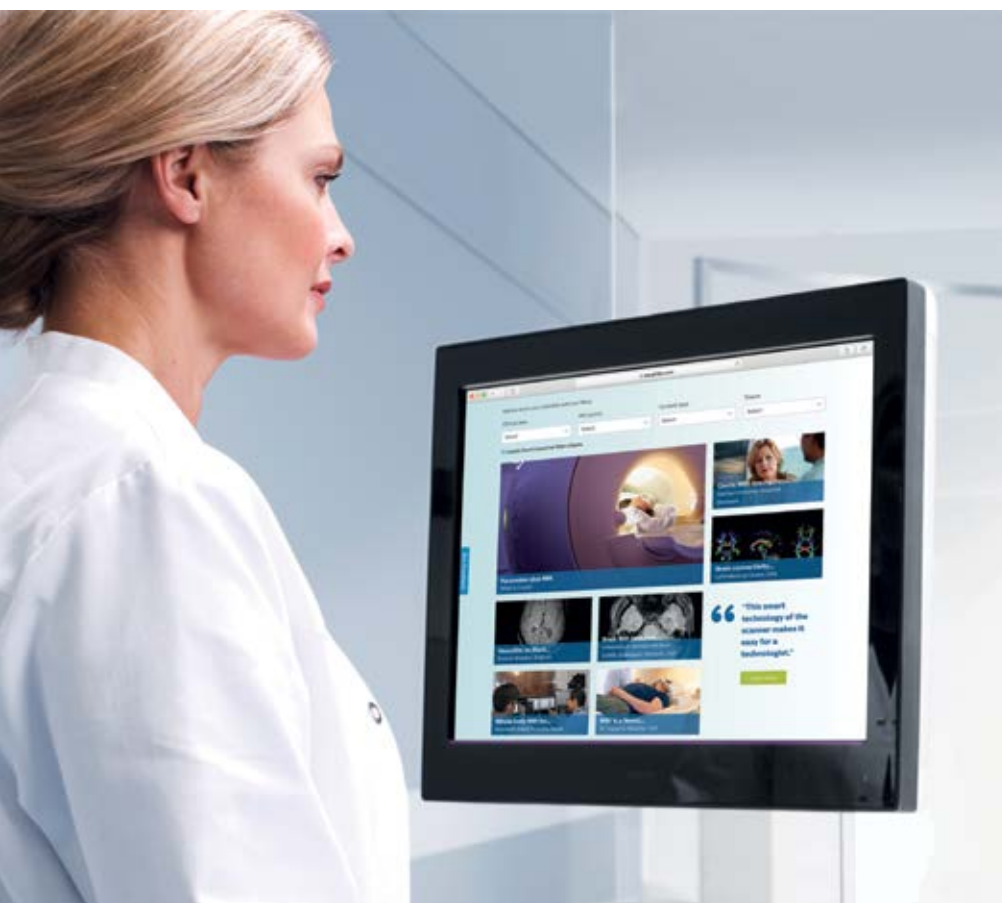FieldStrength is a professional magazine for users of Philips MR systems. It provides results of MR studies performed by Philips users.

### Don't miss an issue

Read more articles or register for your personal email subscription at: [www.philips.com/fieldstrength](http://www.philips.com/fieldstrength)

#### You may also be interested in:

- NetForum to find or share case studies, ExamCards and best practices, see [www.philips.com/netforum](http://www.philips.com/netforum)
- MR body map to view clinical cases of nearly every anatomy, see [www.philips.com/mrbodymap](http://www.philips.com/mrbodymap)
- Philips MRI products, see [www.philips.com/mri](http://www.philips.com/mri)



## FieldStrength MRI articles

Always first available online  
Subscribe to not miss any articles

[www.philips.com/fieldstrength](http://www.philips.com/fieldstrength)

