

The Philips logo, consisting of the word "PHILIPS" in a bold, blue, sans-serif font, is positioned in the top left corner of the page. It is set against a white background that is part of a larger blue graphic element.

FieldStrength  
MRI articles

A photograph showing two men in a clinical setting. They are looking at a large monitor that displays several MRI scan images. The man on the left is older with grey hair, and the man on the right is younger with dark hair. The monitor shows multiple cross-sectional views of a patient's body, likely a head and neck area, with various anatomical structures highlighted in different colors. The background is slightly blurred, focusing attention on the men and the monitor.

# Approaches for including **MRI in radiation therapy planning**

FieldStrength MRI magazine

News - July 2016

[www.philips.com/fieldstrength](http://www.philips.com/fieldstrength)

## **UMC Utrecht offers insight in their experiences with integrating MRI into radiation therapy planning workflows**

Radiation therapy (RT) uses imaging to support delineating anatomy for dose planning. In general, the aim is to target the tumor and spare the surrounding tissues as much as possible. This requires careful planning to ensure spatial accuracy and calibrated dosing. University Medical Center Utrecht (UMCU, Utrecht, Netherlands) has embraced MRI to enhance radiation therapy planning with the benefit of its high soft tissue contrast.

***“Using MRI in radiation therapy means we can differentiate soft tissues and visualize organs and anatomical structures, but it takes some experience to interpret the details seen in the image.”***



Marielle Philippens, MD, PhD

Marielle Philippens, MD, PhD, has been a radiobiologist and medical physicist with focus on MRI physics in the department of Radiation Oncology at University Medical Center Utrecht since 2008. Her research interest is functional imaging for oncology, with particular focus on diffusion weighted MR imaging. Her research focus areas are head and neck cancer, rectal cancer and breast cancer.

## **Good delineation can help spare critical anatomical structures**

Advances in radiation therapy delivery devices allow more complex dose plans to be made. This drives the need for better delineation of tumors and surrounding tissues, but defining the target volume is still a challenge. Target delineation allows the radiation dose to be tailored to the anatomy [1-4] so that a high dose can be directed to the tumor, and a lower dose to the surrounding tissue. Ultimately, less radiation on surrounding tissue may help to preserve functionality of healthy tissue.

While CT is used as the standard imaging modality, it suffers from limitations in providing good soft tissue contrast, especially in regions where soft tissue structures are in close proximity to each other [1]. In this context, the benefits of MRI for radiation therapy treatment planning are long recognized.

MRI offers high soft tissue contrast, thereby providing anatomical, as well as functional information for organ delineation and

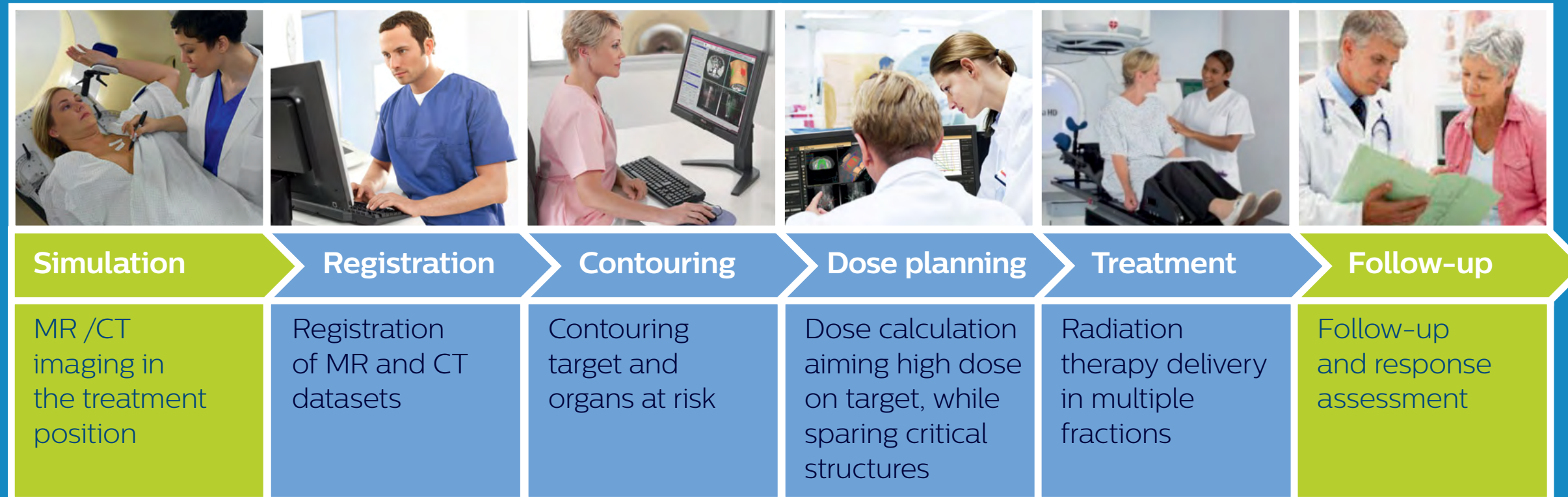
visualization of surrounding anatomy and critical structures, thereby helping to support good determination of target volume [1].

Marielle Philippens, MD, PhD, a medical physicist in the radiotherapy department at UMC Utrecht further explains: "In treatment of the head and neck, for instance, we always try to save the parotid glands and the salivary glands. In cases of prostate and cervix cancer, we aim to spare the bladder and rectum as much as possible. To achieve this, we need to first find the outline of the target. In my experience, it can be quite difficult to delineate this with CT, even when using contrast agent. This is why the high soft tissue contrast of MRI is attractive for radiation therapy planning."

***"In cases of prostate and cervix cancer, we aim to spare the bladder and rectum as much as possible"***

## Simplified overview of MR imaging in radiation therapy workflow

Imaging plays a vital role at several steps in the radiation therapy workflow to visualize targets and critical structures for contouring, and to assess treatment response.



### Choosing MRI protocols for treatment planning

In clinical practice, MRI is mostly used in conjunction with CT for visualization of targets and critical structures [5], while CT is used to delineate anatomical structures and provide Hounsfield Units (HU) for dose calculation.

“MRI can provide different types of contrast,” says Dr. Philippens. “This allows us to see more details than on CT. We can differentiate soft tissues and visualize organs and anatomical structures, but it takes some experience, particularly with head and neck tumors, to understand how to interpret the details seen in the image.”

“MRI can provide anatomical and functional information. The most important sequence for tumor delineation is the T1-weighted scan after contrast administration. On post-contrast T1-weighted MR images with fat suppression, the tumor can be distinguished due to its high perfusion and leaky vessels. We also use pre-contrast T1-weighted images, which show tumor extension into the fatty tissue.

“On the T2-weighted MRI with fat suppression the tumor with its edematous surrounding tissue can be clearly distinguished. This is particularly useful if the tumor does not show enhancement after contrast injection.

“Diffusion weighted imaging (DWI) shows very high contrast between the tumor and surrounding tissue. DWI helps us to see how a tumor extends into another structure, which we may not see on the T1-weighted or T2-weighted images. However, as DWI images are prone to distortions, these are mainly used to visualize the tumor and for response assessment, and not yet so much for delineation. I like to include diffusion weighted imaging, as it is so easy to see the tumor in these images. In my opinion, it has great potential, both for supporting tumor delineation and in response assessment.”

**“In my opinion, diffusion weighted imaging has great potential for RT.”**



## Successful planning requires a good fit between MRI and CT

Ideally, the patient position during the MRI scan should be exactly the same as during radiation therapy treatment, to ensure that organs are in the same position and that the target volume planned on the images will match the volume that is irradiated. Therefore, a flat tabletop and an external laser for patient alignment are often used during MRI to obtain spatial correlation in radiation therapy treatment planning and good coregistration of MRI and CT images.

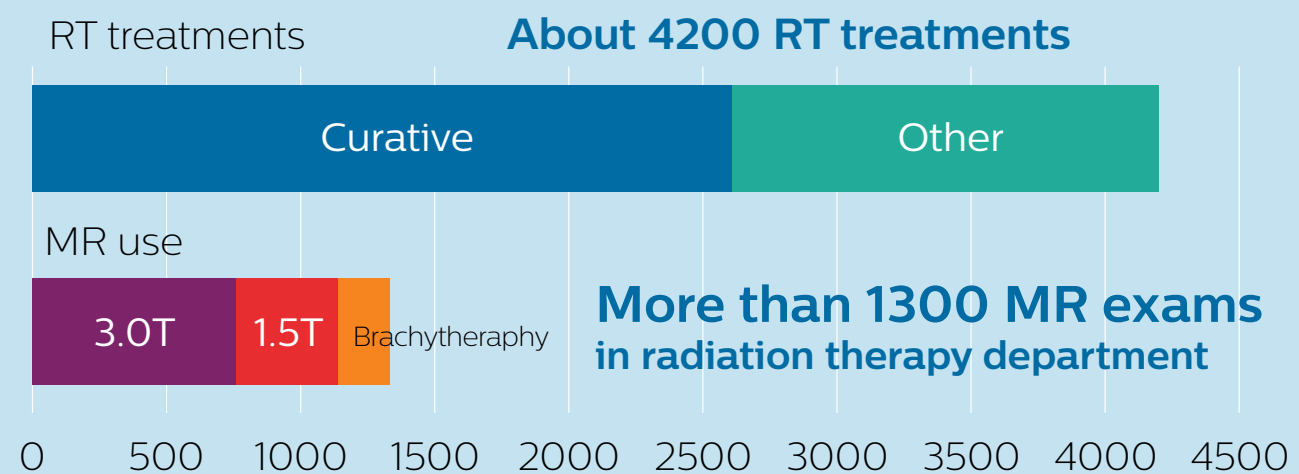
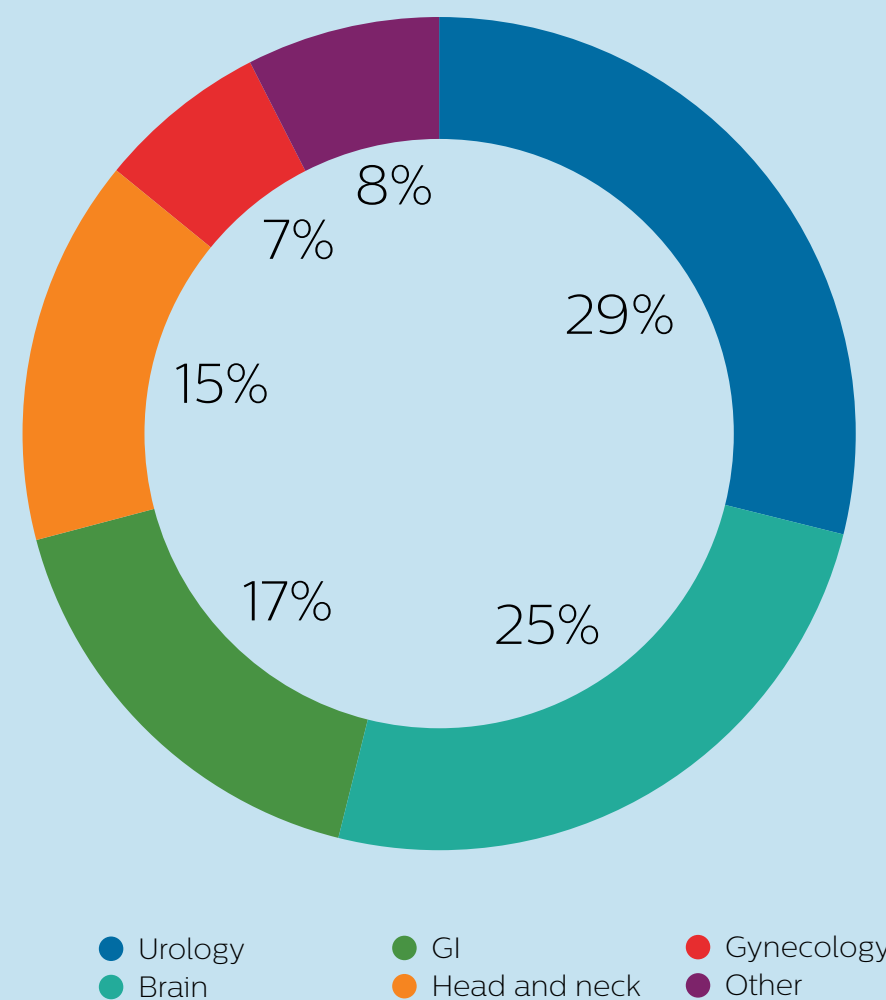
“For coregistration of MRI and CT images, we aim to use an MRI contrast type with few non-linearities and good tissue differentiation, preferably acquired as non-angulated axial slices,”

says Dr. Philippens. “Either 3D scan protocols or multislice 2D protocols with contiguous slices are used to allow target volume reconstruction in the different orthogonal directions.”

## MRI is used for planning in a variety of anatomies

At UMC Utrecht, Dr. Philippens and her colleagues are using MRI in planning external beam radiation therapy (EBRT) for treatment of tumors in a variety of anatomies, such as organs in the pelvis (including bladder, prostate, rectum and cervix), the brain, the esophagus, pancreas, the larynx and oropharynx, bone metastases and sarcomas. In addition, MRI is also used to guide brachytherapy in the prostate and cervix.[6]

Use of MR in RT planning at UMC Utrecht in 2015



The University Medical Center Utrecht Department of Radiotherapy is a leading center in radiation therapy, continuously striving to improve methods and provide excellent patient care. UMC Utrecht has two Philips Ingenia MR-RT systems (1.5T and 3.0T) for RT treatment simulation as well as a Philips Achieva 1.5T system dedicated for brachytherapy. Furthermore, it is an Atlantic MR-Linac consortium member. UMCU regularly organizes courses on MRI in radiotherapy for physicians, technologists and radiation oncologists, see: <http://mri-in-radiotherapy.nl/>

## High dose on the lesion rather than on the whole prostate

MRI is capable of visualizing the prostate and the surrounding organs such as rectum, penile bulb, bladder, the apex and seminal vesicles, as well as visualizing intra-prostatic lesions [2,4].

“All our patients undergo an MRI exam – along with CT – before radiotherapy of the prostate,” says Dr. Philippens. “For prostate delineation, we are scanning a balanced TFE with fat suppression. We can also see the gold fiducial markers in these images, which are used for position verification and are therefore used for registration to CT. For geometric accuracy of the image,

we choose a 3D sequence, which is corrected for the gradient non-linearities in all directions.

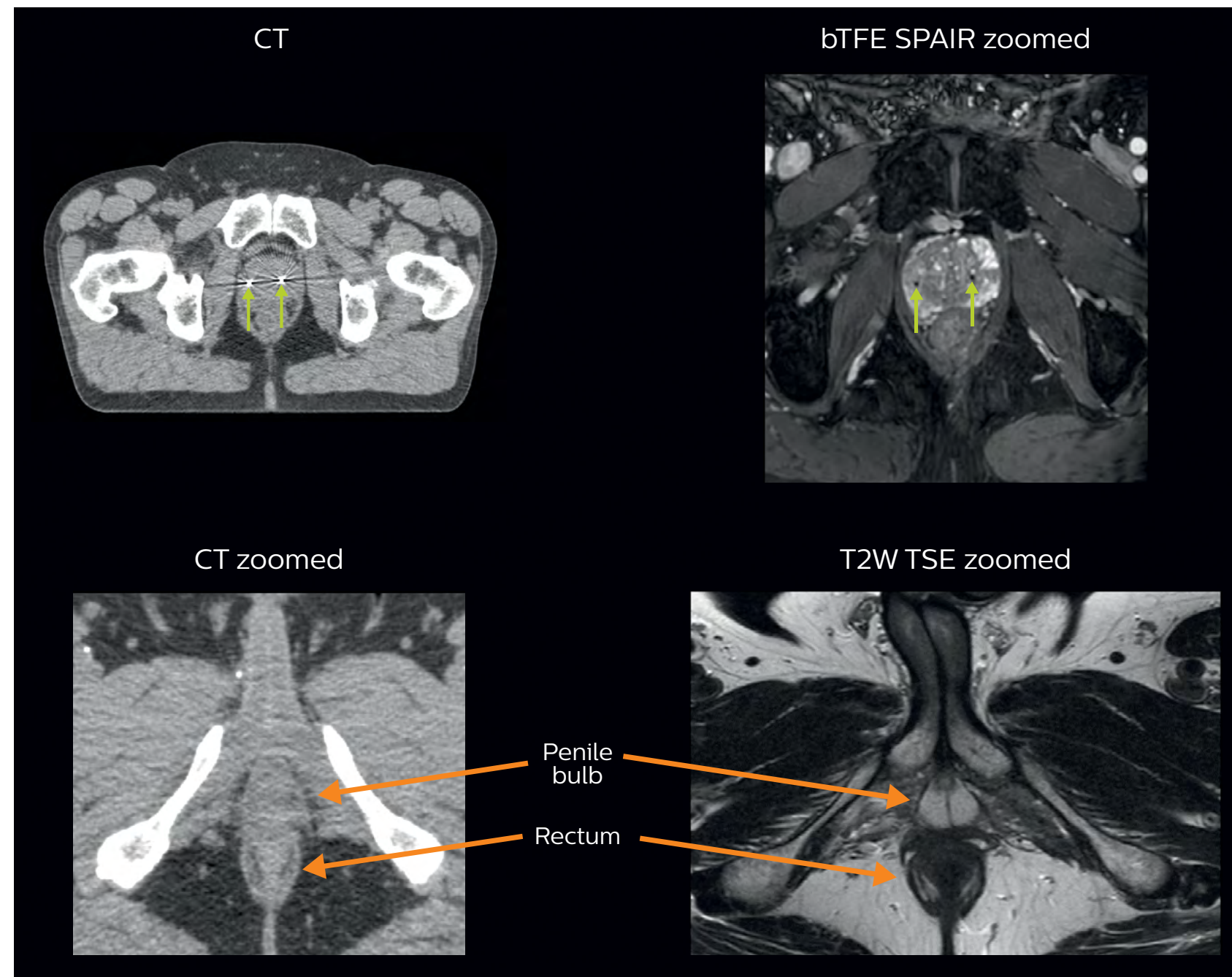
“In addition to helping in delineation of the prostate, MRI also helps in visualizing the lesions inside the prostate, which may not be possible in CT.

“When we can visualize intraprostatic lesions, the radiation therapist can then plan to boost them, giving a higher dose to those lesions instead of giving a uniform dose to the whole prostate, in the hope to better treat the patient and have less risk of recurrent tumors. However, this is not yet clinical routine. For visualizing the lesions, we not only use anatomical, T2-weighted imaging, but also diffusion weighted MRI and dynamic contrast-enhanced MRI.

## Visualizing critical structures with MRI before prostate radiation therapy

A 63-year-old patient with prostate cancer, cT3bNxM, Gleason 7 underwent MRI on Ingenia 3.0T MR-RT before radiation therapy.

Intraprostatic lesions are visible on the bTFE MR image, but not on the CT image. MRI shows excellent soft-tissue contrast for the visualization of critical structures like the rectum and penile bulb. Fiducial markers (green arrows) are used in registration of MR images to CT, to transfer the MR-based delineations onto the CT image dataset.





## Case study: Comprehensive MRI exam of prostate for RT planning

A 70-year-old male with cT3bNxM0, Gleason 6, PSA 7.9  $\mu\text{g/L}$  was referred for radiation therapy treatment.

The bTFE sequence with SPAIR fat suppression shows the outline of the prostate as well as the gold fiducials. It is important that both are defined in the same, high resolution image, since the positioning of the patient during radiotherapy treatment is based on the position of the gold fiducials.

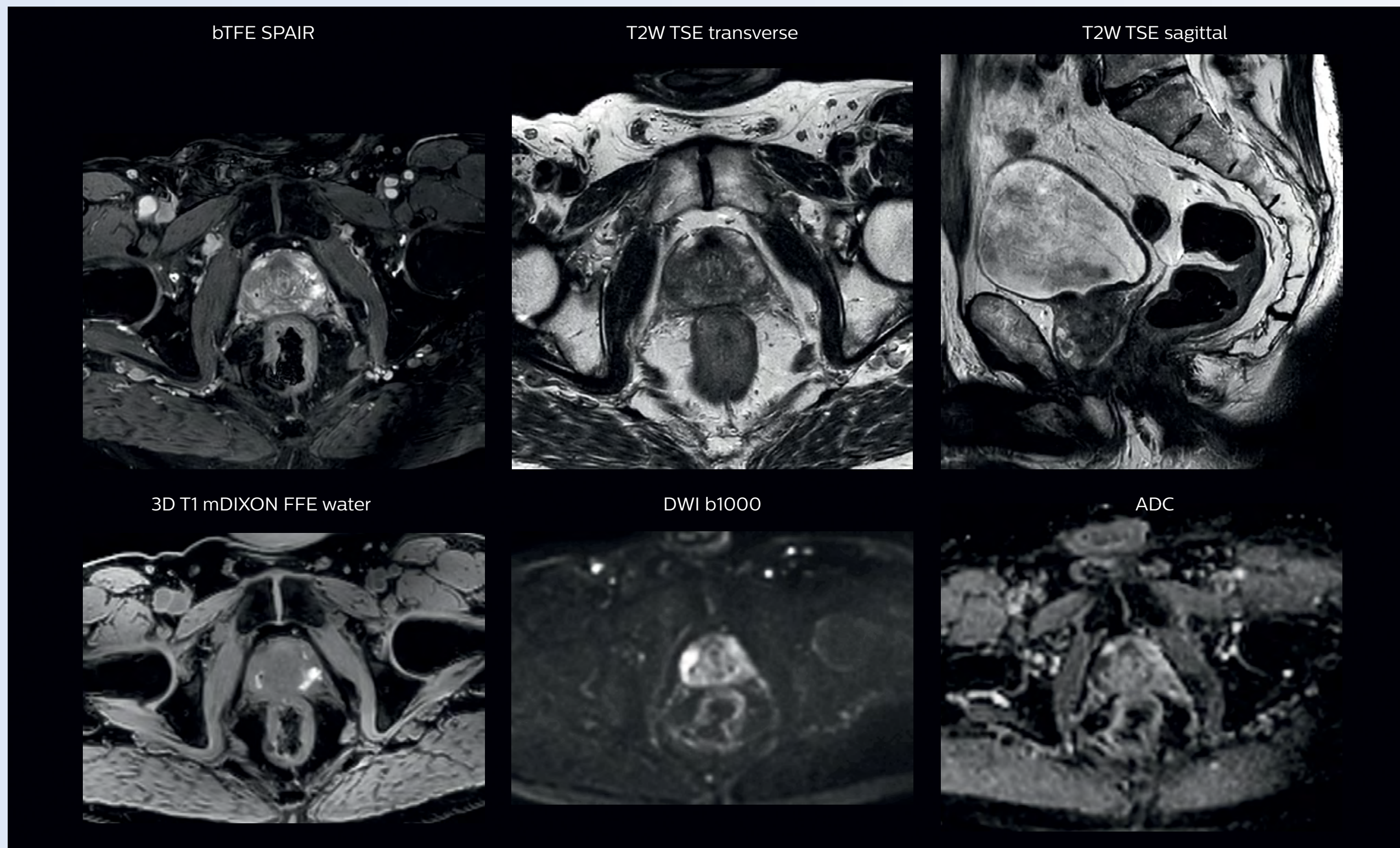
The transverse and sagittal T2W TSE images help us identify the prostate tumor foci, which typically have lower signal intensity than normal prostate. For patients that are referred for brachytherapy the T2W image is used to identify the presence of extracapsular extensions as these are a contraindication for brachytherapy.

The 3D T1 FFE mDIXON is used to identify abnormalities that could be hemorrhages due to biopsies or insertion of fiducial markers. These hemorrhages may look similar to tumor foci on T2-weighted images and ADC map.

Transverse DWI with SPAIR and 6 b-values is used to visualize the tumor foci (bright appearance), which mostly have a low ADC.

The dynamic T1 FFE with 120 dynamics and a temporal resolution of 2.4 seconds is also used visualize the tumor foci, which often show a high perfusion.

Philips Ingenia 3.0T using the Anterior coil and the integrated Posterior coil.





***“For cervical cancer, MRI is already standard of care in our department for image-guided brachytherapy.”***

## **Avoid dosing critical structures around the cervix**

“For cervical cancer, MRI is already standard of care in our department in image-guided brachytherapy. For planning external beam radiation therapy, we now also always include MRI, because it is so important to avoid dosing the bladder, the rectum, small bowel and sigmoid,” says Dr. Philippens.

Other critical structures that are potentially vulnerable are the kidneys, the femoral head and the spinal cord. Bone marrow is especially important to preserve if the patient will receive chemotherapy, as that can cause bone marrow depletion [7].

“By doing an MRI between EBRT and as treatment planning for brachytherapy we can also see how the tumor evolves before starting with brachytherapy. This helps us to follow tumor shrinkage, helps in tumor selection and allows to know the dose in the bladder and the rectum.

“As the cervix and uterus can change position depending upon how full the bladder is, several treatment plans are made based on the MRIs with different bladder filling: empty, half-full and full. The treatment on a certain day depends on the filling of the bladder. Although it’s worth doing this, we never do it with CT, because of the ionizing radiation involved.

“We mostly use sagittal, coronal and transverse T2-weighted MR sequences for delineation of the tumor, the CTV, bladder, small bowel, sigmoid and rectum. We repeat this after treatment for monitoring treatment response.”

### **Use of MRI in radiotherapy for cervix cancers**

- Before EBRT planning (with different bladder fillings)
- Between radiotherapy fractions for monitoring treatment response
- Between EBRT and brachytherapy for brachytherapy planning
- Before and after each brachytherapy treatment.
- Follow-up 3 months after treatment



***“If we want to boost a tumor, we need to know where the outline is. We cannot see that well on CT, so we use MRI.”***

### **MRI for response assessment after radiation therapy of the rectum**

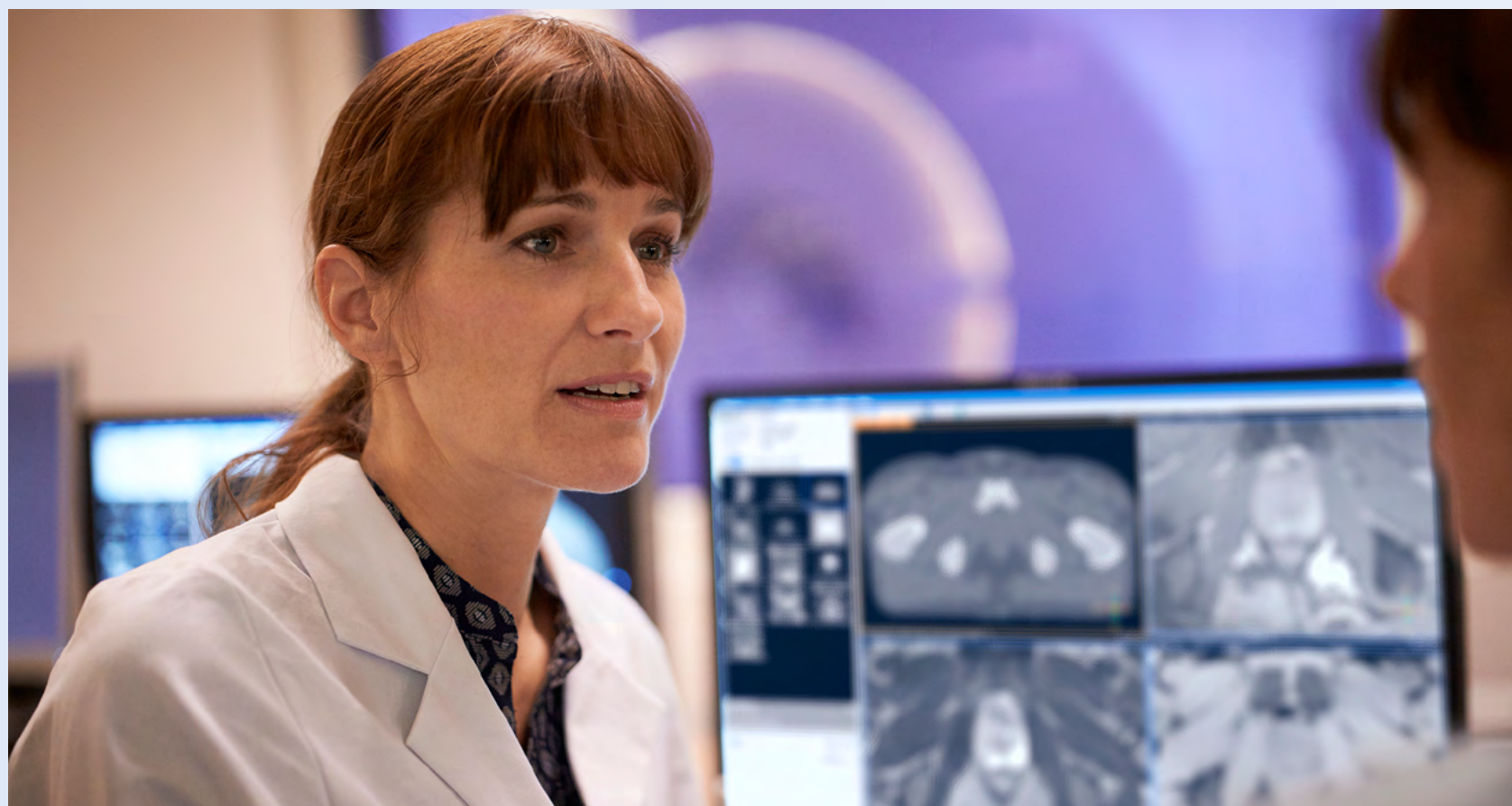The latest guidelines in the management of rectal cancer, published by the European Society for Medical Oncology, include the use of MRI for staging. According to these guidelines, MRI is the method of choice for intermediate/advanced T stage, N stage, and sphincter infiltration, all of which are critical to the determination of treatment strategy and tumor delineation [5].

In RT treatment of rectum tumor, UMC Utrecht uses MRI mostly for response assessment. This is relevant because of the trend toward minimally invasive surgery or even omitting surgery if the patient is believed to have achieved complete remission.

At UMC Utrecht, patients with advanced rectal tumors undergo 25x2 Gy radiochemotherapy, then receive an MRI scan 8 to 12 weeks later, to determine if there is enough remission to perform surgery.

“Surgery for rectal cancer comes with a high morbidity rate and, if the tumor still invades the mesorectal fascia, surgery is unlikely to result in a good outcome. Patient selection after radiotherapy is therefore key when deciding whether to move to surgery, and MRI can help us when making that decision for patients with advanced tumors. For this, I see great potential for diffusion-weighted imaging to help differentiate between tumor and treatment-induced fibrosis.”

In addition to treatment response monitoring, MRI could also be helpful when going for a boost treatment strategy. “If we want to boost a tumor, we need to know where the outline is, which is why we want to use the high soft-tissue contrast of MRI. That is where MRI can really make a difference in radiation therapy planning. We use T2-weighted images for delineation of the tumor; the exam includes sagittal and transverse T2-TSE, DWI, and also a T2-weighted TSE sequence perpendicular through the tumor.”



***“MRI can help us when making the decision to move to surgery for patients with advanced tumors”***



***“In patients with a primary tumor in the head and neck area, we use MRI in daily clinical RT practice to visualize the tumor and critical structures. This may be used to help sparing of critical structures.”***

### **Visualizing critical structures in the head and neck**

“In patients with a primary tumor in the head and neck area, we do use MRI in daily clinical radiation therapy practice to visualize the tumor and critical structures. This may be used to help sparing of critical structures, such as the parotid glands, submandibular glands, esophagus, optic nerves, brain stem and spinal cord [8]. And post-operatively, we scan patients that have tumor growth along the cranial nerves for target delineation,” says Dr. Philippens.

“Because of the challenges posed by CT-MRI coregistration in this area with many degrees of freedom for motion, we image these patients in a radiotherapy mask. However, one disadvantage of using the mask is that a regular head and neck coil cannot be used; a dedicated coil solution would be needed for imaging with a mask.

For this we make use of flexible coils that we position close to the target area. This setup can also be combined with the anterior coil for a larger coverage and enhanced SNR.”

“We use pre- and post-contrast T1- and T2-weighted sequences with the fast and robust mDIXON method for fat suppression,” says Dr. Philippens. “Dynamic contrast-enhanced imaging is performed with high temporal resolution and low spatial resolution, to see the contrast agent uptake in the tumor. Diffusion weighted imaging is used qualitatively to see how the tumor extends into another structure, rather than for strict delineation.”

“In post-operative patients who have had tumor growth along the cranial nerves, we use T2-weighted gradient echo (FFE) on our 3.0T MR-RT scanner to show the nerves for target delineation and look to see if there is still tumor left.”

***“We use pre- and post-contrast T1- and T2-weighted sequences with the fast and robust mDIXON method for fat suppression”***

## Case study: MRI of head and neck for radiation therapy planning

A 75-year-old male was referred for radiation therapy treatment of oropharynx squamous cell carcinoma in the left tonsil region with extension into the soft palate, caudal border lower tonsil region, no midline crossing. On the left side in the neck there are also three enlarged lymph nodes on level 2 and 3 with central necrosis and signs of limited extracapsular extension, T2N2b.

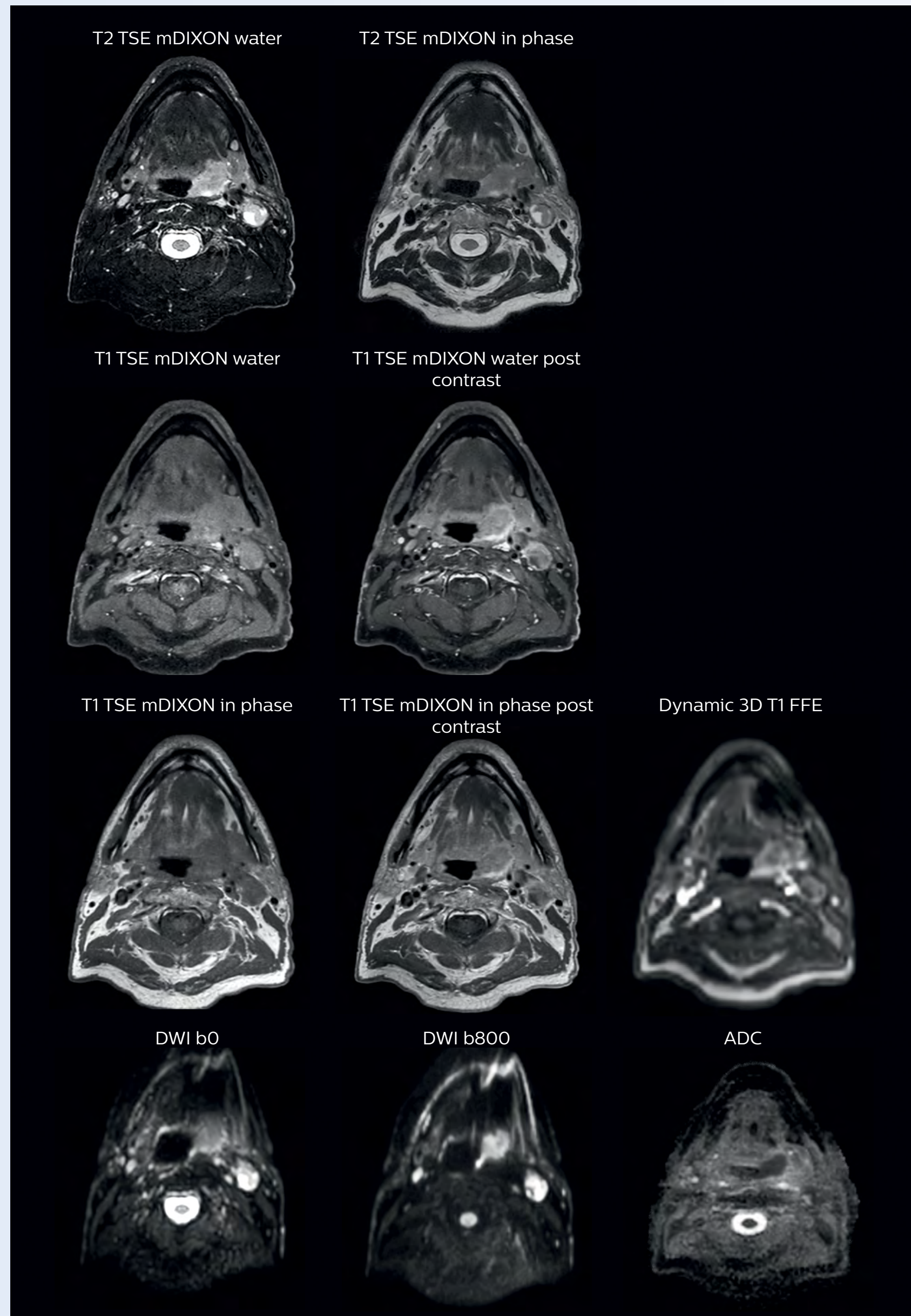
The patient undergoes MRI in the radiotherapy (5-point) positioning mask in Ingenia 3.0T using the Flex coils.

DWI with SPIR is used to visualize the extension of the tumor and lymph nodes, especially retropharyngeal. Transverse T1 and T2 TSE mDIXON water and in-phase images (2 mm thick slices) help to visualize the tumor size and its extension into fatty tissue. The post-contrast T1wTSE mDIXON also shows this.

Dynamic 3D T1 FFE with 45 dynamics and temporal resolution of 2.5 seconds is performed to follow contrast agent distribution. Contrast agent distribution is modeled after conversion of the signal to T1 relaxation times using the small flip angle method.

### Clinical value

Using different contrasts (T1, T2, diffusion, post-contrast T1) in MRI allows us to appreciate contrast changes in the tumor and in the vicinity of the tumor. This helps to delineate the tumor. MRI and especially DWI also helps to visualize the retropharyngeal lymph nodes.





***“Brain was one of the first applications for which MRI became a clinical standard in our department, as the superb soft-tissue contrast of MRI is so obvious.”***

### **MRI helps delineate tumors in the brain**

To spare as much brain tissue as possible, clear differentiation between brain tissue and the tumor is important to support a delineation in radiation therapy planning. “MRI is of high value, as its soft tissue contrast allows to determine tumor volume and extent,” says Dr. Philippens.

“In our protocol, patients referred for radiation therapy of the brain always undergo MRI. It was one of the first applications for which MRI became a clinical standard in our department, as the superb soft tissue contrast of MRI is so obvious. CT has poor capabilities in visualizing the tumor outline.”

“For brain tumors, we only use isotropic 3D MR sequences, acquiring pre- and post-contrast T1-weighted images, and a T2-weighted FLAIR for delineation. For gliomas or larger tumors, we use the 3.0T system for high contrast, high resolution DWI with an ADC map. We image those patients without a thermoplastic mask.”

“For patients with small metastatic lesions, when we are planning stereotactic treatment of brain metastasis, we use 1.5T to have fewer distortions; these patients are imaged with a thermoplastic mask.”





## Which field strength to choose for MRI in radiation therapy planning?

For radiotherapy departments that consider to initiate the use of MRI in radiation therapy planning, Dr. Philippens notes several considerations related to MRI field strength.

- **Site-specific patient population**

“The high 3.0T field strength provides higher SNR and spatial resolution than 1.5T. However, at 1.5T distortions tend to be fewer than at 3.0T. The choice between 1.5T and 3.0T can depend on the anatomies that will need to be scanned and the desired balance between the required resolution and the ability to interpret distortions. For instance, the head-neck area is more sensitive to distortions than the prostate.”

- **MRI knowledge and experience of the staff**

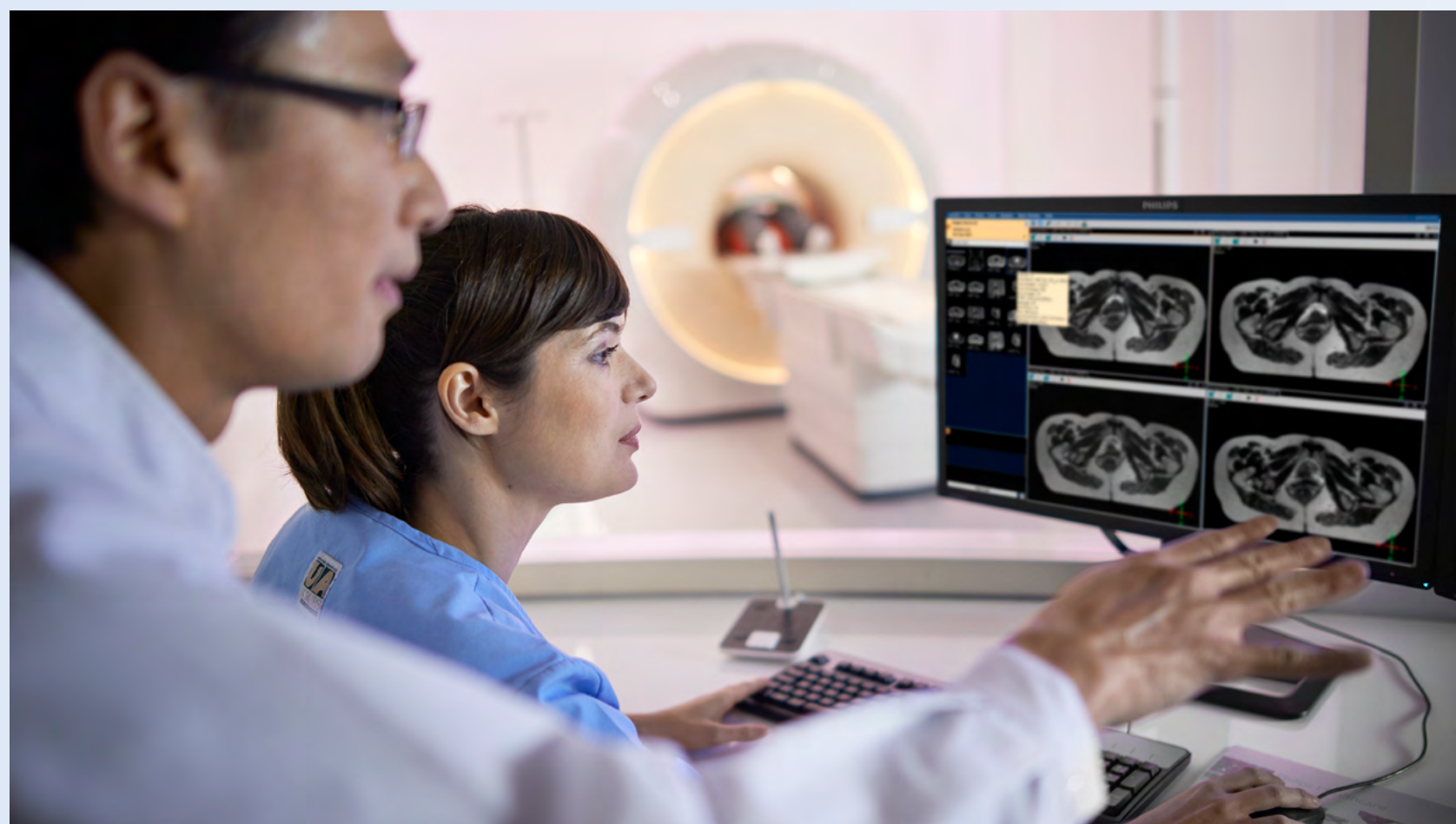“3.0T MRI requires a higher staff expertise than 1.5T. So, for an oncology department starting out in using MRI for radiation therapy planning, choosing 1.5T can help the team become accustomed to the new workflow.”

- **Treatment planning only or broader use**

“If treatment simulation is the main use, I recommend to consider starting with 1.5T, as it is easier for reducing distortions, although resolution and contrast for brain and pelvic tumors are not as good as with 3.0T. If MRI is also used for response monitoring and functional imaging of the tumor, I think 3.0T should be the first choice, although it has to be considered that thoracic imaging (esophagus and lung) are not feasible on 3.0T.”

- **When both 1.5T and 3.0T are available**













































“If a hospital has access to both 1.5T and 3.0T, I’d recommend doing MRI for prostate and rectal cancer planning on 3.0T, and asking the radiologist for a preference on other applications, because the choice depends on the patient and the disease,” says Dr. Philippens. “It also depends on the knowledge of the staff and the medical physicist, who need to adjust the ExamCards and sequences between the two field strengths.”







## Differences between field strengths

This table summarizes the view of the radiation therapy department at UMC Utrecht on differences between 1.5T or 3.0T field strengths for use in radiation therapy applications.

Acquisition techniques	1.5T	3.0T
T2W TSE	 Voxel size: 0.7 x 0.7 x 3 mm <sup>3</sup>	 Voxel size: 0.45 x 0.45 x 3 mm <sup>3</sup>
T1W TSE		
DCE-MRI	 ↓ Spatial/↑ temporal resolution	 ↑ Spatial/↓ temporal resolution
DWI-EPI		 ↓ Geometric accuracy
Non-EPI DWI	 ↓↓ SNR	
PseudoCT/MRCAT for MR-only simulation		 ↓ Geometric accuracy
Treatment simulation, imaging in treatment position	1.5T	3.0T
Brain	 Consider for stereotactic treatment	 Consider for non-stereotactic treatment
Pelvis: prostate, rectum, cervix, bladder	 ↓ Resolution	 ↑ Resolution
Head and neck	 ↑ Robustness	 ↑ Resolution
Thorax: esophagus		 Artifacts due to motion sensitivity and susceptibility
Abdomen: pancreas, liver		 Motion sensitivity concerns
Breast		 Susceptibility artifacts
Tumor visualization and response monitoring	1.5T	3.0T
Brain	 ↓ Contrast, ↓ Resolution	 ↑ Contrast, ↑ Resolution
Pelvis: prostate, rectum, cervix, bladder	 ↓ Resolution	
Head and neck		
Thorax: esophagus		 Artifacts due to motion sensitivity and susceptibility
Abdomen: pancreas, liver		 Motion sensitivity
Breast	 DWI better than on 3.0T, ↓ Resolution	 ↑ Resolution
System-related considerations	1.5T	3.0T
Geometric accuracy		 Larger susceptibility changes
SAR		 SAR limits in high temporal imaging
Staff	1.5T	3.0T
Expertise	 Modest level	 High level
Training	 Modest level	 High level

 Not feasible

 Not preferable, but possible

 Effective, but with some tradeoffs

 Most effective

## Understanding distortions in MRI for radiation therapy planning

Gradient non-linearities and B0 field homogeneities may lead to geometric distortions in the MR images. “The gradient non-linearities can be (partially) corrected for in the reconstruction software. We use a dedicated geometric QA phantom and analysis software to evaluate the system’s gradient linearity on a monthly basis.”

“Patient-induced susceptibilities can also lead to distortions in imaging,” says Dr. Philippens. “Inhomogeneities of the magnet field together with the patient-induced susceptibilities can be reduced by shimming of the magnetic field when the patient is in the magnet.”

***“It is good to involve radiologists with their knowledge, but it ultimately is the radiation oncologist who makes the decision on where to draw the line around the tumor”***

## Training is critical when adopting MRI in RT

Part of the vision for Utrecht’s program has been to start by training its radiation therapy technologists in MRI, rather than training its MRI techs in radiation therapy. Therefore, the radiation therapy technologists at Utrecht have been trained in MR simulation, including MR imaging. The second step is bringing the radiation oncologists together with the radiologists, to ensure a unified focus and workflow.

“In our experience, training and education of the radiation therapy technologists and radiation oncologists in particular is critical to accelerating the clinical adoption of MRI in RT. It is essential to get these team members on board as part of a collaborative effort. The radiation therapy technologists must be well trained in MRI – and not only in safety. They need knowledge of scan protocols, and how to operate the MRI scanner, choose the coils and select the tabletops.

“At this stage, it’s still mostly medical physicists who pave the road, while the impact on clinical benefits and establishment of consensus on delineated volumes on MRI require the active involvement from radiation oncologists,” says Dr. Philippens. “I recommend a multi-disciplinary approach. It is good to involve radiologists with their knowledge on MRI and tumor visualization and differentiation, but it ultimately is the radiation oncologist who makes the decision on where to draw the line around the tumor. Training and education of radiation oncologists is needed to achieve consensus and guidelines.”





## Multidisciplinary effort is the key to success

According to Dr. Philippens, a selection of the key points to training and knowledge requirements include the following:

- A **dedicated MRI system** is needed, with a flat tabletop, coil supports and coil setups specifically designed for radiation therapy MRI.
- A clear, collaborative, **multidisciplinary training plan** should ensure that the technologists understand both the radiation therapy workflow (e.g. importance of patient positioning) as well as the operation of the MRI system. At UMCU, radiation therapy technologists collaborate with radiology technologists, to enhance MRI knowledge alongside the experience of what is important for radiation therapy. All must be well trained on the use of MRI for radiation therapy planning and the differences with CT.
- **Dedicated exam protocols** are required for radiotherapy, for the different application areas. Someone in-house should have the expertise to optimize the preset protocols to the specific needs of the hospital.

- A **medical physicist** who understands both MRI and radiotherapy is crucial for providing ongoing support. This person should team up with an MR physicist from radiology. In addition, there should be collaboration and discussions between medical physicists and radiation oncologists.

After that, the big question is **who is responsible** for patient selection: the radiation oncologist or the radiologist? What duties are appropriate, what's considered diagnostic, and what's considered therapeutic?

“For example, delineating the tumor is a radiation therapy question, but response assessment, even assessing response to radiation therapy, is up for discussion, and will vary from hospital to hospital, depending on the structure of the radiation therapy department and the skill sets involved,” says Dr. Philippens.

“I strongly believe it's important to involve everyone in the process, and contribute knowledge and experiences as a team.”

### References

1. Schmidt MA, Payne GS. *Radiotherapy planning using MRI*. *Phys Med Biol* 2015, 60: R323–361
2. Doemer A, Chetty IJ, Glide-Hurst C, et al. *Evaluating organ delineation, dose calculation and daily localization in an open-MRI simulation workflow for prostate cancer patients*. *Radiat Oncol*. 2015;10:37.
3. Devic S. *MRI simulation for radiotherapy treatment planning*. *Med Phys* 2012, 39: 6701-11
4. Paulson ES, Erickson, B, Schultz C, Li XA. *Comprehensive MRI simulation methodology using a dedicated MRI scanner in radiation oncology for external beam radiation treatment planning*. *Med Phys* 2015, 42: 28-39
5. Glynne-Jones R, Nilsson PJ, Aschele C, et al. *Anal cancer: ESMO-ESSO-ESTRO clinical practice guidelines*. *Ann Oncol*. 2014;25:iii10–20.
6. Metcalfe P, Liney GP, Holloway L, et al. *The potential for an enhanced role for MRI in radiation-therapy treatment planning*. *Technol Cancer Res Treat* 2013, 12: 429–46
7. Jhingran A, Eifel P. *Radiation therapy for cervical carcinoma*. *Glob Libr Women's Med* 2008, doi10.3843/GLOWM.10234J
8. Nuyts S. *Defining the target for radiotherapy of head and neck cancer*. *Cancer Imaging*. 2007; 7:S50–5.

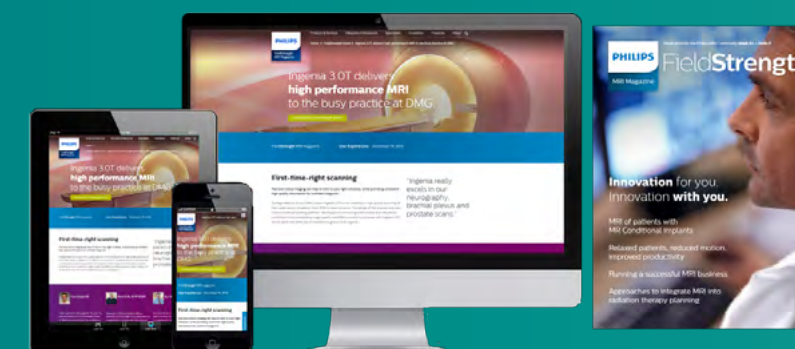Results from case studies are not predictive of results in other cases. Results in other cases may vary.

Results from this facility are not predictive of results in other facilities. Results in other facilities may vary.

# Subscribe to **FieldStrength**

Our periodic FieldStrength MRI newsletter provides you articles on latest trends and insights, MRI best practices, clinical cases, application tips and more. Subscribe now to receive our free FieldStrength MRI newsletter via e-mail.

**Stay in touch with Philips MRI**



## **Related information**

- [Opening new treatment pathways in radiation therapy with MRI \(movie\) ›](#)
- [Ingenia MR-RT MR simulation platform ›](#)
- [Tap the real power of MR simulation – MR-only sim \(movie\) ›](#)
- [White paper: MR-only simulation for radiotherapy planning ›](#)



## **More from FieldStrength**

- [MRI for RT planning – Beaumont Health System ›](#)
- [Scanning patients with MR Conditional implants ›](#)
- [mDIXON saves time and provides homogeneous fat saturation in MRI ›](#)

© 2016 Koninklijke Philips N.V. All rights reserved.  
Specifications are subject to change without notice.  
Trademarks are the property of Koninklijke Philips N.V.  
(Royal Philips) or their respective owners.

[www.philips.com](http://www.philips.com)



### **How to reach us**

Please visit [www.philips.com/healthcare](http://www.philips.com/healthcare)  
[healthcare@philips.com](mailto:healthcare@philips.com)