

SUPPLEMENT TO OCTOBER 2019



Coronary In-Stent Restenosis: An Algorithmic Approach to Diagnosis and Treatment

This supplement is provided with sponsorship from Philips.

The opinions presented herein are specific to the featured physicians and are for informational purposes only. The results from any case study may not be predictive of results for all patients. These articles are not intended to provide medical advice or to take the place of written law or regulations.

AN **HMP** PUBLICATION

Forward

George D. Dangas, MD, PhD

Even in the contemporary era of percutaneous coronary intervention using drug-eluting stents, in-stent restenosis (ISR) remains a common problem, occurring in 5% to 20% of cases, depending on several patient and lesion characteristics. Recurrent ISR can be a common problem in these subjects and adding layer upon layer of stent struts in the restenotic lesion may not be the optimal treatment option. Therefore, identification of the mechanism causing restenosis using intracoronary imaging, and optimization of the treatment of the restenotic lesion, are of paramount importance. This series provides our treatment algorithm, which was developed to systematically classify the pattern and underlying mechanism of ISR followed by suggestions for optimal treatment.



70 E. Swedesford Road, Suite 100, Malvern, PA 19355

© 2019, HMP. All rights reserved. Reproduction in whole or in part prohibited. Opinions expressed by authors, contributors, and advertisers are their own and not necessarily those of HMP, the editorial staff, or any member of the editorial advisory board. HMP is not responsible for accuracy of dosages given in articles printed herein. The appearance of advertisements in this journal is not a warranty, endorsement or approval of the products or services advertised or of their effectiveness, quality or safety. Rapid advances in medicine may cause information contained here to become outdated, invalid or subject to debate. Accuracy cannot be guaranteed. HMP disclaims responsibility for any injury to persons or property resulting from any ideas or products referred to in the articles or advertisements. Content may not be reproduced in any form without written permission. Rights, Permission, Reprint, and Translation information is available at www.hmpglobal.com.

HMP is the force behind Healthcare Made Practical and is a multichannel leader in healthcare events and education with a mission to improve patient care. The company produces accredited medical education events and clinically relevant, evidence-based content for the global healthcare community across a range of therapeutic areas. For more information, visit hmpglobal.com.

©2019 Koninklijke Philips N.V. All rights reserved. Some or all products manufactured by Spectranetics, a Philips company. Approved for external distribution. D050554-00 102019

In-Stent Restenosis: The Clinical Challenge

Kevin J. Croce, MD, PhD

In stent restenosis is the re-narrowing of a stented artery segment and is defined based on angiographic and/or clinical criteria (Table 1).¹ Mehran's classification system describes the morphologic classifications of ISR—focal, diffuse, proliferative, or occlusive—and has prognostic value in predicting the rate of revascularization.²

In-Stent Restenosis Incidence and Outcomes

Drug-eluting stents (DES) have revolutionized treatment of obstructive coronary artery disease improving the durability of percutaneous coronary artery interventions (PCI) by decreasing target lesion revascularization compared to bare metal stents (BMS). The safety and durability of DES is so favorable that BMS use has declined nationally, and contemporary discussions have centered around what role, if any, bare metal stents should have in CAD treatment.³⁻⁶ Despite the advantages of DES over BMS in preventing in-stent restenosis (ISR) and target lesion failure, DES failure continues to be a clinical problem. Second-generation DES have failure rates at 1 year that average 5.7% and 8.7% in non-diabetic and diabetic patients, respectively.⁷ Worse yet, DES TLF rates do not plateau at 1 year, and all modern DES trials show a gradual increase in major adverse clinical events (MACE) over time, such that 5-year TLF rates are in the 9% to 12% range in generally noncomplex lesions (Figure 1). In real world use, modern DES fare even less well with 5-year TLF rates that exceed 15% (Figure 1).⁸ The cumulative rates of DES failure have created a major clinical problem so that > 10% of all PCIs done in the United States (US) are to treat ISR, and the number of ISR interventions appears to be increasing year over year (Figure 2).^{9,10} The burden of ISR nationally generates significant cost to the US health care system, and it is increasingly recognized that PCI patients treated for ISR have an increased risk of death compared to non-ISR PCI patients. This elevated risk of death is present even in elective settings not complicated by acute coronary syndrome presentation (Figure 3).¹¹

ISR patients suffer worse outcomes to some extent because treatments for ISR are not as effective as treatments for de novo coronary artery disease.¹²⁻¹⁷ In the US, the contemporary treatment of initial ISR is to implant a second DES because DES therapy has superior efficacy over balloon angioplasty alone.^{12,14,15} The failure rates for second layer DES are however quite high with clinical TLR rates of 12% to 16% at 12 months and 33% at 3 to 5 years.¹²⁻¹⁸ There currently is an unmet clinical need for more effective treatments for ISR, especially in patients with multi-layer stent failure.

Table 1. Definition and classification of in-stent restenosis.

Angiographic Restenosis and Classification
Diameter stenosis 50%
Type 1 focal: 10 mm in length
IA articulation or gap
IB margin
IC focal body
ID multifocal
Type 2 diffuse: 10 mm intrastent
Type 3 proliferative: 10 mm extending beyond the stent margins
Type 4 total occlusion: restenotic lesions with TIMI flow grade of 0
Clinical Restenosis: Assessed Objectively as Requirement for Ischemia-Driven Repeat Revascularization
Diameter stenosis 50% and one of the following:
Positive history of recurrent angina pectoris, presumably related to target vessel
Objective signs of ischemia at rest [ECG changes] or during exercise test [or equivalent], presumably related to target vessel
Abnormal results of any invasive functional diagnostic test (eg, coronary flow velocity reserve, FFR 0.80); IVUS minimum cross-sectional area 4 mm ² (and 6.0 mm ² for left main stem) has been found to correlate with abnormal FFR and need for subsequent TLR
TLR with diameter stenosis 70% even in absence of the above ischemic signs or symptoms
<small>ECG = electrocardiography; FFR = fractional flow reserve; IVUS = intravascular ultrasound; MI = myocardial infarction; TIMI = Thrombolysis In Myocardial Infarction; TLR = target lesion revascularization. Adapted from Dangas GD, Claessen BE, Caixeta A, et al. In-stent restenosis in the drug-eluting stent era. <i>J Am Coll Cardiol</i>. 2010;56:1897-1907.</small>

In-Stent Restenosis Causes and Implications for Treatment

The patient and procedural factors that are associated with increased risk of ISR are well characterized and have been reviewed in detail.^{1,19,20} Patient characteristics that increase ISR risk include diabetes, chronic kidney disease, multivessel coronary artery disease, age, and female gender.²¹ Lesion characteristics associated with ISR include complex lesions (B2/C, calcified stenoses, chronic total occlusion), longer lesion length, smaller artery diameter, bypass grafts, left anterior descending coronary artery location, and ostial stenoses.²²⁻²⁴

The biological factors that contribute to ISR are related to variable sensitivity to DES drugs²⁵ and/or potential

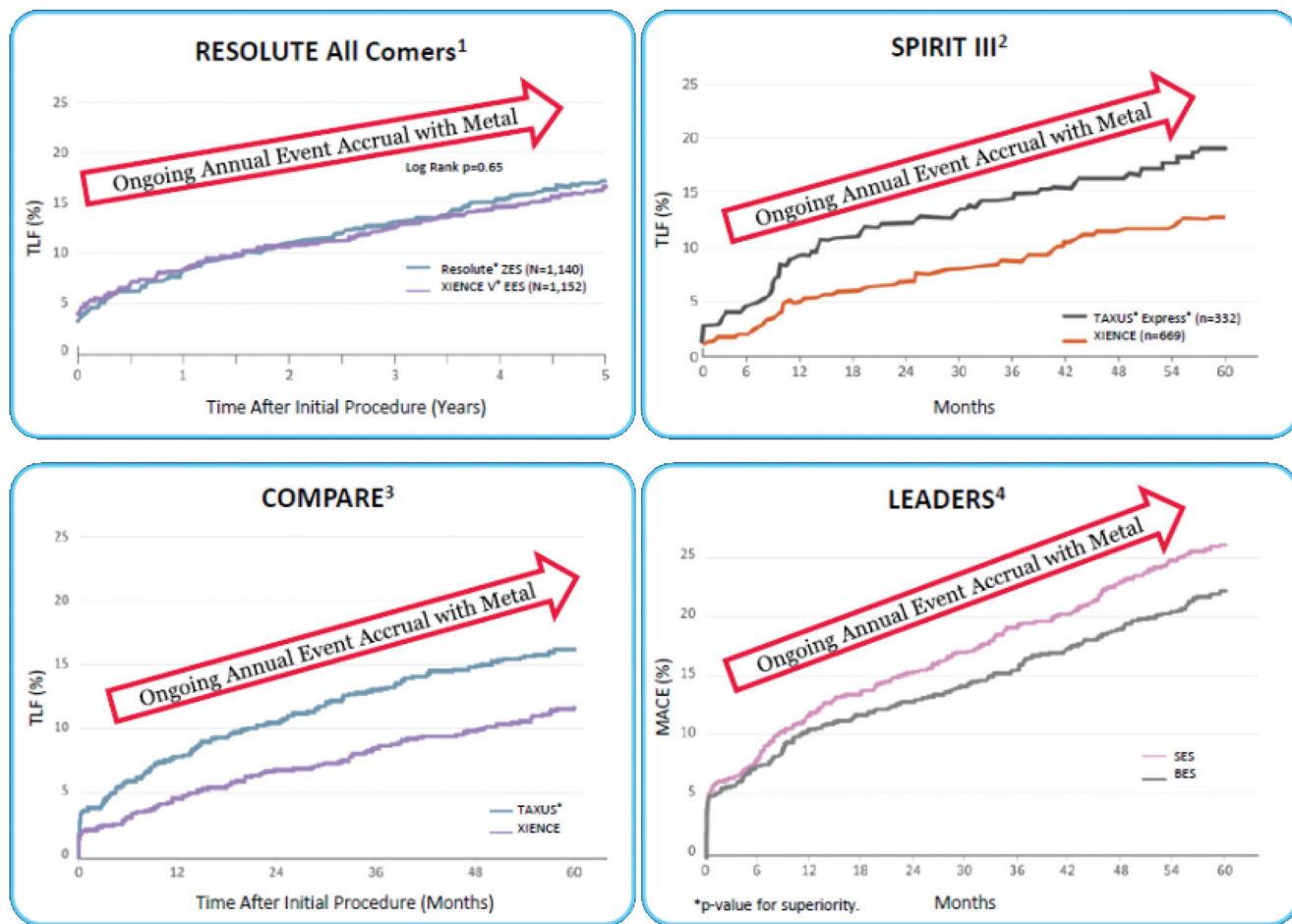


FIGURE 1. Five-year target lesion revascularization for second generation DES. Windecker S. RESOLUTE all Comers 5-year EuroPCR 2014; Gada H, et al SPIRIT III 5 year. JACC Cardiovasc Interv. 2013;1263-1266; Smits P. COMPARE 5-year TCT 2013; Serruys PW. LEADERS 5-year. TCT 2012; von Birgelen C, et al. TCT-572 Final 5-year Outcome After Implantation of Zotarolimus-Eluting RESOLUTE, J Am Coll Card. 2015;66(15_SJ

hypersensitivity to the stent, polymer, or drug component of the DES.²⁶ With newer biocompatible DES polymers and biodegradable polymers, the potential for hypersensitivity may be diminished compared to initial DES platforms. The technical and mechanical factors that contribute to DES failure include geographic miss, under-expansion, and stent fracture (Figures 4, 5C and D). Geographic miss occurs when the stent does not fully cover the injured or diseased segment. Under-expansion occurs more frequently in calcified stenoses and is seen more frequently with early DES failure within 1 year from implantation.²⁷ ISR in the BMS era was classically considered to occur from neointimal hyperplasia consisting of smooth muscle cells and extracellular matrix and compared to DES, BMS ISR tends to be more diffuse. More recently, it has become well established that in-stent neoatherosclerosis is an important mechanism of stent failure that may occur more often with DES compared to BMS.²⁸ Neoatherosclerosis in-stent resembles classic atheroma with lipid deposition, foam cell macrophage infiltration, and in later stages marked calcification (Figures 5A and B).²⁸

In-stent neoatherosclerotic thin cap fibroatheroma (TCFA) has been described, and rupture of in-stent TCFA are a potential source of very late stent thrombosis. Calcific neoatherosclerosis is particularly problematic for treatment because the calcific tissue is constrained by the stent, which makes it challenging to achieve expansion when treating the ISR segment. In some cases, calcific neoatherosclerosis requires debulking with atherectomy to enable maximal expansion during PCI of ISR lesions.²⁹

Diagnosis of In-Stent Restenosis: Obligate Intravascular Imaging

In treating patients with ISR, diagnosing the cause of stent failure is critical to determining the most appropriate treatment. It is essential to understand the mechanism of stent failure because the mechanism of failure will directly impact the therapeutic decisions and devices needed to manage the ISR segment (Table 2). Angiography inadequately assesses ISR because of limited resolution and inherent deficiency in quantifying vessel size, stent size, stent expansion,

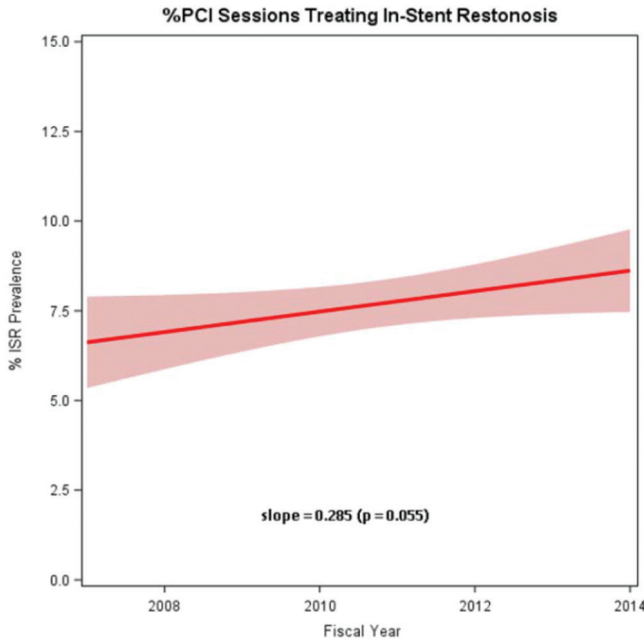


FIGURE 2. Incidence of coronary in-stent restenosis: Insights from the National VA CART Program.¹⁰

number of stent layers, in-stent calcific neoatherosclerosis, and extra-stent calcific disease. In contrast to angiography, intravascular ultrasound (IVUS) and optical coherence tomography (OCT) provide detailed assessment of the native artery and stented segment and readily identify the precise mechanism(s) of stent failure (Table 2). We firmly believe that all stent failures should be evaluated by intravascular imaging to diagnose the cause of in-stent restenosis, to inform therapeutic strategy, and to confirm effective treatment post PCI. The US and European PCI guidelines both support the use of intravascular imaging in the diagnosis and treatment of stent failure (Class IIa recommendation, level of evidence C).^{30,31} Importantly, randomized studies clearly show that when treating de novo non-ISR stenoses, intravascular imaging reduces target lesion failure and ISR by 50%,^{32,33} and over time we anticipate that increased adoption of IVUS and OCT during initial PCI will help to prevent the steady increase in ISR that is occurring in the US. This is especially important in light of recent intravascular imaging studies that demonstrate that (1) suboptimal stent deployment is common—occurring in 31% to 58% of patients³³⁻³⁵ and (2) that suboptimal stent deployment confers an increased risk of adverse events.³⁵ Emerging data from several registry studies has recently demonstrated that use of intravascular imaging during PCI not only reduces stent failure and TLF, but is also associated with a reduction in cardiovascular mortality.^{36,37}

In utilizing intravascular imaging to diagnose and treat ISR, the goal is to determine the reference segment size, lesion length, site of ISR (in-stent vs edge), nature of ISR (diffuse vs. focal), predominance of neointima vs. neoatherosclerosis,

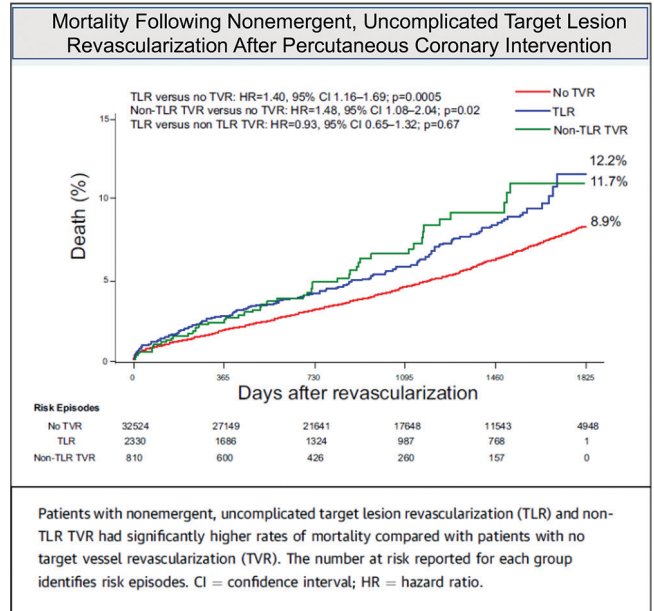


FIGURE 3. Mortality following nonemergent, uncomplicated target lesion revascularization after percutaneous coronary intervention.

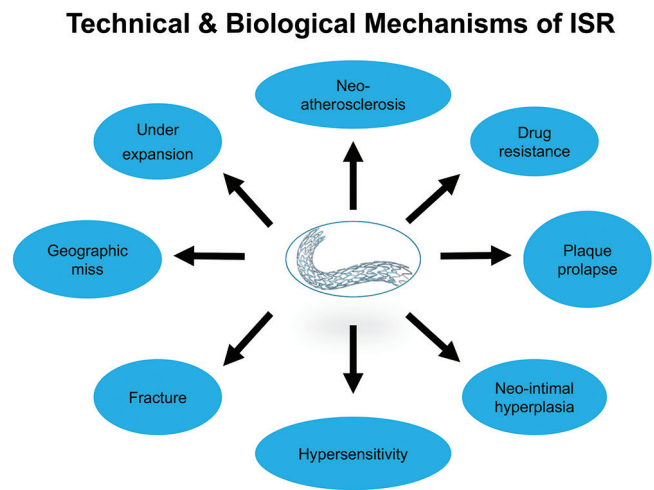


FIGURE 4. Mortality following nonemergent, uncomplicated target lesion revascularization after percutaneous coronary intervention.¹¹

number of stent layers, prior stent expansion and apposition, presence/absence of stent fracture, and presence/absence of intra- and/or extra stent calcium. As outlined above, ISR treatments have much higher TLF rates compared to PCI of de novo stenoses, and we thus focus on utilizing an intravascular imaging-based strategy to maximize the likelihood that the ISR PCI will be durable. The strongest modifiable predictors of non-ISR stent failure are (1) under-expansion, (2) severe inflow and outflow disease proximal to or distal to the stent, and (3) presence of major dissection (> 3 mm or involving the media).^{33,35} After identifying the causal mechanism of ISR,

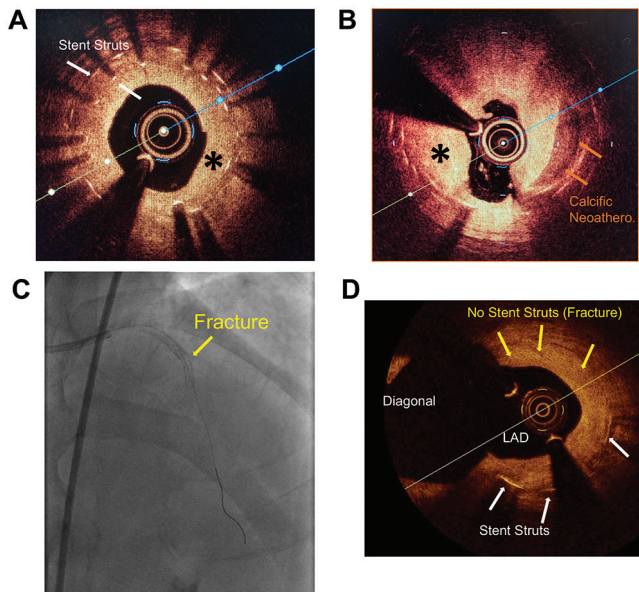


FIGURE 5. Intravascular imaging of ISR tissue and stent fracture. (A) OCT image of multilayer ISR with neointima tissue and onion skin layer of neointima between two stent layers [white arrows denote stent struts, * denotes neointima tissue] (B) OCT image of calcific neoatherosclerosis [in-stent] admixed with neointimal tissue [red arrows denote calcific neoatherosclerosis, * denotes neointima tissue]. Angiogram (C) and OCT image (D) of stent fracture at the flexion point of an LAD and diagonal bifurcation with severe ISR [white arrows denote stent struts, yellow arrows denote region with no stent where stent has fractured at the bifurcation].

we strongly advocate for an algorithmic approach to vessel preparation and treatment that is focused on (1) debulking the ISR tissue to facilitate expansion and maximize final stent area, (2) aggressively treating stent under-expansion if present, and (3) treating severe inflow and outflow disease (see ISR treatment algorithm, article two in this series by Dr. George Dangas). Multiple studies demonstrate that suboptimal minimal stent area (MSA) is the major predictor of stent failure, and an IVUS optimized MSA of $> 5.0 \text{ mm}^2$ ³³ or OCT optimized MSA of $> 4.5 \text{ mm}^2$ ³⁵ is often defined as the minimum goal for image optimized PCI. A more progressive approach to image-guided PCI that integrates reference vessel size is becoming the preferred strategy to preventing TLF in modern practice. Using this strategy, the target is to achieve an MSA at initial stent implantation that is $> 90\%$ of the closest proximal or distal reference segment.

Image-Guided Contemporary Treatment of In-Stent Restenosis

In a contemporary approach to image-guided ISR treatment optimization, we aim to treat the modifiable entities that predict stent failure. The specific goals are to ensure (1) final stent expansion/lumen area is $> 90\%$ of the proximal and distal reference segment, as demonstrated by IVUS or OCT, (2) there are no inflow or outflow obstructions within

Table 2. Intravascular imaging is critical to guiding ISR intervention.

ISR Mechanism	Potential Treatments
Unstented/gap segment	BA, DES
Severe neointimal hyperplasia	BA, laser, DES
Stent fracture	BA, DES, brachytherapy
Undersized	BA high pressure, scoring balloon, larger DES
Underexpansion	BA high pressure inflation, scoring balloon, laser, atherectomy, DES
> 2 layers of stent	Laser, brachytherapy, outside US - DCB

*BA = balloon angioplasty; DES = drug-eluting stent; DCB = drug-coated balloon

Table 3. Image-guided ISR treatment optimization.

- Final stent expansion/lumen area $> 90\%$ of the proximal and distal reference segment [demonstrated by IVUS or OCT]
- No inflow or outflow obstructions within 5mm of the proximal or distal stent edge [defined MLA $< 5.0 \text{ mm}^2$ by IVUS or MLA $< 4.5 \text{ mm}^2$ by OCT]
- No major edge dissections
[defined as > 60 degree, $> 3 \text{ mm}$ in length, or penetrating the media]

5 mm of the proximal or distal stent edge that has a minimal lumen area (MLA) $< 5.0 \text{ mm}^2$ by IVUS or MLA $< 4.5 \text{ mm}^2$ by OCT and, (3) there are no major edge dissections defined as > 60 degree, $> 3 \text{ mm}$ in length, or penetrating the media (Table 3). If there is significant in-stent under expansion, it is critical to increase expansion by algorithmically applying high-pressure balloons, scoring balloons, and atherectomy technologies until the stent expands completely. It is particularly important that the initial ISR stent expands well prior to implantation of a new stent because, as discussed later in this ISR article series, multilayer (> 2 stents) under-expanded ISR is a particularly difficult problem to treat.^{38,39} If intravascular imaging shows significant peri-stent inflow or outflow obstruction or an important edge dissection, then we treat with standard PCI technique often by placing an additional stent.

In treating ISR, it is critical to identify the presence of stent under expansion and multilayer ISR with intravascular imaging. In a series of “recalcitrant” ISR cases where patients with two layers of DES were treated with a third DES layer, IVUS demonstrated that two layer DES under expansion was common (average expansion, 64.5%) and severe calcification behind the stents was seen in all cases of under expanded multilayer DES ISR (Figure 6).⁴⁰ After reintervention in this ISR patient series, most stents remained under

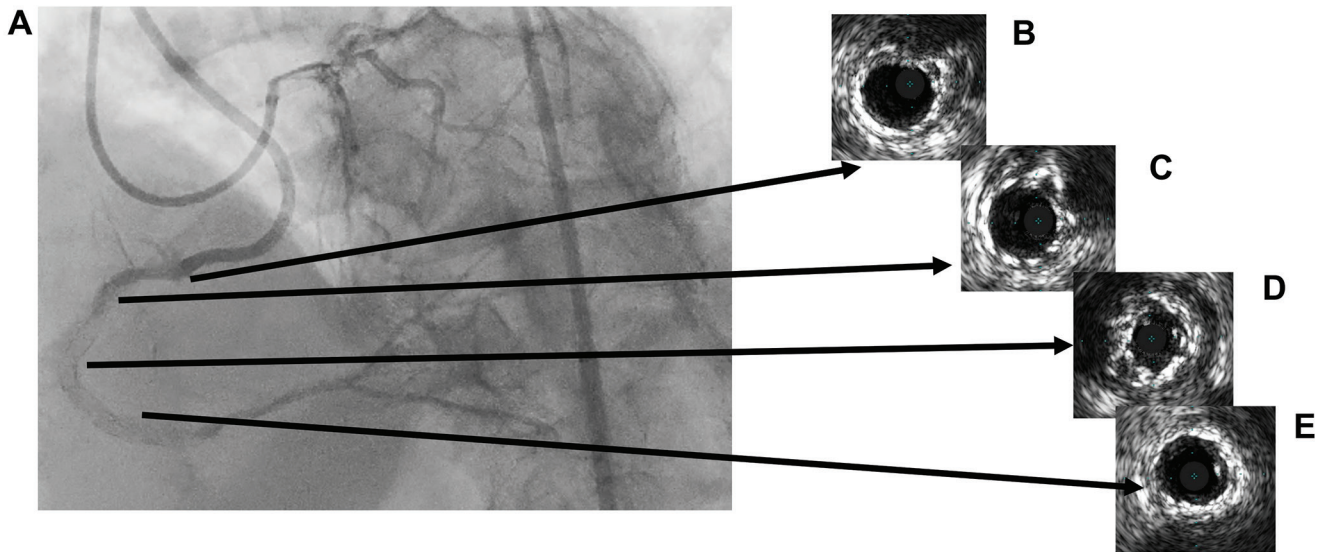


FIGURE 6. Multilayer DES ISR Chronic Total Occlusion. [A] Dual injection angiography showing mid RCA chronic total occlusion [CTO] in multilayer DES ISR segment. [B-E vs C-E] Corresponding IVUS images showing multilayer stent under expansion in the ISR CTO region.

expanded (mean stent expansion, 67%).⁴⁰ In most cases, mechanical problems contribute to the development of DES ISR. With ISR interventions now accounting for > 10% of all PCIs in the US, and with the general experience that under expansion contributes to the majority of multilayer DES ISR, there is a tremendous opportunity to improve on PCI technique by optimizing the first stent implant with IVUS or OCT and to utilize atherectomy or other plaque modification techniques to ensure adequate stent expansion. It is well accepted that angiography underestimates the severity of calcium⁴¹ and therefore, increased utilization of IVUS or OCT for pre-stent planning has the strong potential to identify situations where plaque modification will be required to facilitate maximal stent expansion. Emerging data suggest that in cases where intravascular imaging identifies an arc of calcium > 270 degrees or greater than 0.67 mm in thickness, atherectomy vessel preparation should be considered to optimize lesion and stent expansion.⁴²

ISR interventions have failure rates that are higher than initial stent implantations. Thus, in an “ounce of prevention is worth a pound of cure” approach, the goal of initial PCI should be to maximize stent expansion to prevent the cycle of ISR reinterventions which are difficult to treat and have suboptimal long-term patency. Recurrent ISR is a major therapeutic dilemma. In the US, ISR is typically treated with reimplantation of another stent. Multiple layers of stents however compound the ISR problem by creating an “onion skin” layer of stent on neointima, which crowds the artery lumen, hinders complete expansion, and adversely impacts the ability to achieve an optimized final MSA (Figure 5). An artery encased in a multilayer stent is difficult to expand, and this stent compliance problem is further compounded

by the presence of peri-stent calcium or intrastent neoatherosclerotic calcium that likely hindered proper expansion during placement of the first or second stent. The function of DES is to provide scaffolding to prevent recoil and cover dissections and to deliver antiproliferative drugs that inhibit neointimal formation. In treating ISR, the main purpose of a second stent implant is to deliver antiproliferative drugs, and in many cases, the additional layer of stent further crowds the lumen with minimal benefit of additional scaffolding. In the complex multilayer ISR scenario, drug-eluting balloons provide an attractive opportunity to deliver antiproliferative drugs without adding an additional layer of stent. The 1-year DEB treatment outcomes for two- and three-layer stent treatment are however suboptimal, with MACE rates of 16.1% and 43.1%, respectively.¹⁸ The challenges in treating multilayer ISR has led to a resurgence in coronary artery brachytherapy therapy for ISR in several referral centers. The coronary artery brachytherapy system available in the US (Novoste Beta-Cath) utilizes a strontium-90 source to deliver beta radiation to the ISR stenosis to inhibit neointimal proliferation without the need for placement of an additional stent. Two recent series evaluated the efficacy of coronary brachytherapy for recalcitrant multilayer ISR where in the best case, multilayer DES ISR brachytherapy TLR rates were 3.3% at 6 months, 12.1% at 1 year, 19.1% at 2 years, and 20.7% at 3 years.^{43,44} In an effort to improve durability, we currently utilize an intravascular imaging guided approach with liberal use of atherectomy in all ISR and multilayer ISR brachytherapy cases. Contemporary, imaged-guided ISR treatment currently employs an algorithmic approach to vessel preparation and treatment that often utilizes scoring and cutting balloons, laser atherectomy, rotational or

orbital atherectomy, brachytherapy, and outside the US, lithotripsy balloons and DEBs. An algorithmic approach to ISR treatment optimization is essential to improving outcomes in this difficult patient subset. Utility of specific devices and an ISR optimization algorithm will be the focus of subsequent articles in this series.

References

- Dangas GD, Claessen BE, Caixeta A, et al. In-stent restenosis in the drug-eluting stent era. *J Am Coll Cardiol*. 2010;56:1897-1907.
- Mehran R, Dangas G, Abizaid AS, et al. Angiographic patterns of in-stent restenosis: Classification and implications for long-term outcome. *Circulation*. 1999;100(18):1872-1878.
- Colombo A, Jabbour R. There are no current indications to use a bare-metal stent: Pro. *J Am Coll Cardiol*. 2016.
- Colombo A, Giannini F, Briguori C. Should we still have bare-metal stents available in our catheterization laboratory? *J Am Coll Cardiol*. 2017;70(5):607-619.
- Bangalore S, Kumar S, Fusaro M, et al. Short- and long-term outcomes with drug-eluting and bare-metal coronary stents: A mixed-treatment comparison analysis of 117 762 patient-years of follow-up from randomized trials. *Circulation*. 2012;125(23):2873-2891.
- Mahmoud AN, Shah NH, Elgendy IY, et al. Safety and efficacy of second-generation drug-eluting stents compared with bare-metal stents: An updated meta-analysis and regression of 9 randomized clinical trials. *Clin Cardiol*. 2018;41(1):151-158.
- Nakatsuma K, Shiomi H, Natsuaki M, et al. Second-generation versus first-generation drug-eluting stents in patients with and without diabetes mellitus: pooled analysis from the RESET and NEXT trials. *Cardiovasc Interv Ther*. 2018;33(2):125-134.
- Iqbal J, Serruys PW, Silber S, et al. Comparison of zotarolimus- and everolimus-eluting coronary stents: final 5-year report of the RESOLUTE all-comers trial. *Circ Cardiovasc Interv*. 2015;8(6):e002230.
- Moussa I, Stone G, Teirstein P, et al. TCT-117 the burden of restenosis after coronary stent implantation in the United States: temporal trends, clinical presentation, treatment strategies, and in-hospital outcomes. *J Am Coll Cardiol*. 2018;72(13):B50-B51.
- Waldo SW, O'Donnell CI, Prouse A, et al. Incidence, procedural management, and clinical outcomes of coronary in-stent restenosis: Insights from the National VA CART Program. *Catheter Cardiovasc Interv*. 2018;91(3):425-433.
- Palmerini T, Della Riva D, Biondi-Zoccai G, et al. Mortality following nonemergent, uncomplicated target lesion revascularization after percutaneous coronary intervention: an individual patient data pooled analysis of 21 randomized trials and 32,524 patients. *JACC Cardiovasc Interv*. 2018;11(9):892-902.
- Ko YG, Kim JS, Kim BK, et al. Efficacy of drug-eluting stents for treating in-stent restenosis of drug-eluting stents [from the Korean DES ISR multicenter registry study [KISS]]. *Am J Cardiol*. 2012;109(5):607-613.
- Ota H, Mahmoudi M, Kitabata H, et al. Safety and efficacy of limus-eluting stents and balloon angioplasty for sirolimus-eluting in-stent restenosis. *Cardiovasc Revasc Med*. 2015;16(2):84-89.
- Maluenda G, Ben-Dor I, Gaglila MA Jr, et al. Clinical outcomes and treatment after drug-eluting stent failure: the absence of traditional risk factors for in-stent restenosis. *Circ Cardiovasc Interv*. 2012;5(1):12-19.
- Kubo S, Kadota K, Otsuru S, et al. Optimal treatment of recurrent restenosis lesions after drug-eluting stent implantation for in-stent restenosis lesions. *EuroIntervention*. 2013;9(7):788-796.
- Rigatelli G, Cardaioli P, Dell'Avvocata F, et al. Management of distal/bifurcation left main restenosis after drug eluting stents implantation: single center experience. *Cardiovasc Revasc Med*. 2014;15(2):76-79.
- Latib A, Mussardo M, Ielasi A, et al. Long-term outcomes after the percutaneous treatment of drug-eluting stent restenosis. *JACC Cardiovasc Interv*. 2011;4(2):155-164.
- Yabushita H, Kawamoto H, Fujino Y, et al. Clinical outcomes of drug-eluting balloon for in-stent restenosis based on the number of metallic layers. *Circ Cardiovasc Interv*. 2018;11(8):e005935.
- Alfonso F, Byrne RA, Rivero F, Kastrati A. Current treatment of in-stent restenosis. *J Am Coll Cardiol*. 2014;63(24):2659-2673.
- Lee MS, Banka G. In-stent restenosis. *Interv Cardiol Clin*. 2016;5(2):211-220.
- Bossi I, Klersy C, Black AJ, et al. In-stent restenosis: long-term outcome and predictors of subsequent target lesion revascularization after repeat balloon angioplasty. *J Am Coll Cardiol*. 2000;35(6):1569-1576.
- Zahn R, Hamm CW, Schneider S, et al. Incidence and predictors of target vessel revascularization and clinical event rates of the sirolimus-eluting coronary stent [results from the prospective multicenter German Cypher Stent Registry]. *Am J Cardiol*. 2005;95(11):1302-1308.
- Costa MA, Angiolillo DJ, Tannenbaum M, et al. Impact of stent deployment procedural factors on long-term effectiveness and safety of sirolimus-eluting stents [final results of the multicenter prospective STLLR trial]. *Am J Cardiol*. 2008;101(12):1704-1711.
- Kobayashi Y, De Gregorio J, Kobayashi N, et al. Stented segment length as an independent predictor of restenosis. *J Am Coll Cardiol*. 1999;34(3):651-659.
- Huang S, Houghton PJ. Mechanisms of resistance to rapamycins. *Drug Resist Updat*. 2001;4(6):378-391.
- Nebeker JR, Virmani R, Bennett CL, et al. Hypersensitivity cases associated with drug-eluting coronary stents: a review of available cases from the Research on Adverse Drug Events and Reports [RADAR] project. *J Am Coll Cardiol*. 2006;47(1):175-181.
- Song L, Mintz GS, Yin D, et al. Characteristics of early versus late in-stent restenosis in second-generation drug-eluting stents: an optical coherence tomography study. *EuroIntervention*. 2017;13(3):294-302.
- Nakazawa G, Otsuka F, Nakano M, et al. The pathology of neoatherosclerosis in human coronary implants bare-metal and drug-eluting stents. *J Am Coll Cardiol*. 2011;57(11):1314-1322.
- Chen G, Zrenner B, Pyxaras SA. Combined rotational atherectomy and intravascular lithotripsy for the treatment of severely calcified in-stent neoatherosclerosis: A mini-review. *Cardiovasc Revasc Med*. 2018;S1553-8389(18):30446-30449.
- Neumann FJ, Sousa-Uva M. 'Ten commandments' for the 2018 ESC/EACTS guidelines on myocardial revascularization. *Eur Heart J*. 2019;40(2):87-165.
- Levine GN, Bates ER, Blankenship JC, et al. 2011 ACCF/AHA/SCAI guideline for percutaneous coronary intervention. A report of the American College of Cardiology Foundation/American Heart Association Task Force on Practice Guidelines and the Society for Cardiovascular Angiography and Interventions. *J Am Coll Cardiol*. 2011;58(24):e44-e122.
- Hong SJ, Kim BK, Shin DH, et al. Effect of Intravascular ultrasound-guided vs angiography-guided everolimus-eluting stent implantation: the IVUS-XPL Randomized Clinical Trial. *JAMA*. 2015;314(20):2155-2163.
- Zhang J, Gao X, Kan J, et al. Intravascular ultrasound versus angiography-guided drug-eluting stent implantation: The ULTIMATE Trial. *J Am Coll Cardiol*. 2018;72(24):3126-3137.
- Jensen LO, Vikman S, Antonsen L, et al. Intravascular ultrasound assessment of minimum lumen area and intimal hyperplasia in in-stent restenosis after drug-eluting or bare-metal stent implantation. The Nordic Intravascular Ultrasound Study [NIVUS]. *Cardiovasc Revasc Med*. 2017;18(8):577-582.
- Prati F, Romagnoli E, Burzotta F, et al. Clinical impact of OCT findings during PCI: The CLI-OPCI II Study. *JACC Cardiovasc Imaging*. 2015;8(11):1297-1305.
- Jones DA, Rathod KS, Koganti S, et al. Angiography alone versus angiography plus optical coherence tomography to guide percutaneous coronary intervention: outcomes from the Pan-London PCI cohort. *JACC Cardiovasc Interv*. 2018;11(14):1313-1321.
- Choi KH, Song YB, Lee JM, et al. Impact of intravascular ultrasound-guided percutaneous coronary intervention on long-term clinical outcomes in patients undergoing complex procedures. *JACC Cardiovasc Interv*. 2019;12(7):607-620.
- Alfonso F, Cuesta J. The therapeutic dilemma of recurrent in-stent restenosis. *Circ Cardiovasc Interv*. 2018;11(8):e007109.
- Alfonso F, Scheller B. Management of recurrent in-stent restenosis: onion skin full metal jacket? *EuroIntervention*. 2013;9(7):781-785.
- Alfonso F, García J, Pérez-Vizcayno MJ, et al. New stent implantation for recurrences after stenting for in-stent restenosis: implications of a third metal layer in human coronary arteries. *J Am Coll Cardiol*. 2009;54(11):1036-1038.
- Mintz GS, Popma JJ, Pichard AD, et al. Patterns of calcification in coronary artery disease. A statistical analysis of intravascular ultrasound and coronary angiography in 1155 lesions. *Circulation*. 1995;91(7):1959-1965.
- Maejima N, Hibi K, Saka K, et al. Relationship between thickness of calcium on optical coherence tomography and crack formation after balloon dilatation in calcified plaque requiring rotational atherectomy. *Circ J*. 2016;80(6):1413-1419.
- Mangione FM, Jatene T, Badr Eslam R, et al. Usefulness of intracoronary brachytherapy for patients with resistant drug-eluting stent restenosis. *Am J Cardiol*. 2017;120(3):369-373.
- Negi SI, Torguson R, Gai J, et al. Intracoronary brachytherapy for recurrent drug-eluting stent failure. *JACC: Cardiovasc Interv*. 2016;9(12):1259-1265.

An Algorithmic Approach to the Treatment of Coronary In-Stent Restenosis

Bimmer E. Claessen, MD, PhD; Annapoorna S. Kini, MD; Roxana Mehran, MD; Samin K. Sharma, MD, FSCAI, FACC; and George D. Dangas, MD, PhD

Since the early days of percutaneous coronary intervention (PCI), restenosis has been one of the most frequent and severe complications.¹ The development of bare metal stents (BMS),² and subsequently of drug-eluting stents (DES),³ has helped to reduce the incidence of restenosis, however patients undergoing stent implantation remain at significant risk for in-stent restenosis (ISR). Even with current-generation DES, ISR may occur after 5% to 20% of cases.⁴ In the United States (US), a relatively modest number of treatment options are approved for ISR lesions by the US Food and Drug Administration (FDA), including the currently obsolete first-generation TAXUS paclitaxel-eluting stent, balloon angioplasty alone, scoring-balloon angioplasty, intravascular brachytherapy, and excimer laser coronary atherectomy (ELCA). This is reflected by the current AHA/ACC/SCAI guideline for PCI, which states a class IIb (may be considered) recommendation with level of evidence C for the treatment of DES ISR reading, “May be considered for repeat PCI with balloon angioplasty, BMS, or DES containing the same drug or an alternative drug if anatomic factors are appropriate and the patient is able to comply with and tolerate dual antiplatelet therapy (DAPT).”⁵ The paclitaxel-coated balloon types are frequently used for this indication outside of the US but is not available in the US,⁶ but involved in a broad controversy regarding their peripheral arterial applications.⁷ Currently, DES implantation in ISR lesions, which holds a Class I level of evidence A indication in the European 2018 ESC/EACTS Guidelines on myocardial revascularization, has not been incorporated in the AHA/ACC/SCAI guidelines.⁸ Hence, the most widely used treatment option for ISR in the US is balloon angioplasty, often followed by the off-label implantation of another DES.⁹ Recurrent ISR can be a common problem in these subjects, and adding layer upon layer of stent struts in the restenotic lesion is not an attractive treatment option. Therefore, identification of the mechanism causing restenosis using intracoronary imaging, and optimization of the treatment of the restenotic lesion, are of paramount importance. This review introduces a treatment algorithm that will facilitate standardized classification of the pattern and mechanism of ISR with recommendations for optimal treatment according to various clinical scenarios. A recently introduced etiology-oriented ISR classification by

Waksman et al largely utilizes intravascular imaging to identify and classify different stages of ISR.¹⁰

Rationale of an Imaging-Based Treatment Algorithm for ISR

Intravascular ultrasound to guide treatment

Both the current European and the North American guidelines state a Class IIa, level of evidence C indication for the use of IVUS to determine the mechanism of stent restenosis.^{11,12} The use of IVUS can identify the presence of any stent- or lesion-related mechanical problems that may lead to restenosis, such as stent under-expansion (due to the presence of extensive peri-stent calcium or not), focal edge restenosis, stent fracture, or the presence of a stent gap. Furthermore, the extent of neointimal hyperplasia can be quantified using IVUS. The importance of identifying mechanical problems is underscored by the findings of Goto et al who analyzed 298 ISR lesions and reported that restenotic DES as compared to BMS were characterized by less neointimal hyperplasia, smaller stent areas, longer stent lengths, and more stent fractures.¹³ As outlined in the treatment algorithm, each mechanical complication has its own specific suggested treatment aimed at correcting the original problem. Optical coherence tomography (OCT) imaging may be an alternative to IVUS in many ISR cases. OCT will allow for improved spatial resolution at the cost of limited tissue penetration. This trade-off will lead to improved imaging of the (neo-)intima but reduced image quality of deeper layers of the coronary artery.

Hence, intravascular imaging and accurate lesion characterization better defines not only the pattern but also the mechanism involved in the specific ISR case. In setting up a center of excellence for ISR treatment, attention should be paid to the detailed evaluation and a deep case understanding before treatment is offered. Therefore, a systematic algorithm for ISR makes a lot of sense.

Role of scoring and cutting balloons and atherectomy

An important objective in treating patients with ISR is obtaining as much acute lumen gain as possible by trying to maximize the immediate post-procedural minimal luminal area. The use of specialty balloons incorporating cutting or scoring elements has been shown to reduce balloon slippage and to result in superior acute angiographic outcomes as compared with conventional balloons.^{14,15} A combination of both cutting- or scoring-balloon angioplasty

From the Zena and Michael A. Wiener Cardiovascular Institute, Icahn School of Medicine at Mount Sinai, New York City, New York.
Author for correspondence: George D. Dangas, MD, PhD, The Icahn School of Medicine at Mount Sinai, New York, NY 10029. Email: george.dangas@mountsinai.org

Table 1. Observational studies investigating excimer laser coronary atherectomy for the treatment of in-stent restenosis

Study	Year	Treatment Arms (N)	ISR Type	Mortality	Repeat Revascularization Rates	Other Outcomes
Mehran et al ²⁰	1997	ELCA+PTCA (N = 54) PTCA (N = 54)	BMS	6 month: 2% 6 month: 2%	6 month: 21% 6 month: 38%	Greater lumen gain and greater cross-sectional area by IVUS analysis in ELCA group
Koster et al ²¹	1999	ELCA+PTCA (N = 440)	BMS	In-hospital: 1.6%	In-hospital: 0.9%	n/a
Koster et al ²²	2000	ELCA+PTCA (N = 96)	BMS	6 month: 1%	6 month: 31%	n/a
Mehran et al ²³	2000	ELCA+PTCA (N = 119) RA+PTCA (N = 130)	BMS	1 year: 8% 1 year: 5%	1 year: 26% 1 year: 28%	Ablation efficiency was higher with RA, but 1-year clinical results were similar
Hirose et al ²⁴	2016	ELCA+SCB(12) SCB alone(11)	DES	6 month: 0% 6 month: 0%	6 month: 16.7% 6 month: 45.5%	Angiographic late lumen loss and diameter stenosis percent at 6-month angiographic follow-up significantly lower with in ELCA group
Ambrosini et al ²⁵	2017	ELCA+DEB (N = 80)	Not reported	6 month: 0%	6 month: 5%	
Ichimoto et al ²⁶	2018	ELCA+DES (N = 23) DES only (N = 58)	DES	2.5 year: 0% 2.5 year: 0%	2.5 year: 21.7% 2.5 year: 25.9%	n/a
Hashimoto et al ²⁷	2019	ELCA, DEB, OCT (N = 53)	BMS and DES	12 month: 0%	12 month: 26.4%	ELCA less effective in layered-type ISR on OCT analysis

BMS = bare metal stent; DEB = drug-eluting balloon; DES = drug-eluting stent; ELCA = excimer laser coronary atherectomy; ISR = in-stent restenosis; IVUS = intravascular ultrasound; OCT = optical coherence tomography; PTCA = percutaneous transluminal coronary angioplasty; RA = rotational atherectomy; SCB = scoring balloon.

and atherectomy (either rotational or excimer laser coronary atherectomy [ELCA]) will theoretically lead to optimized ablation and modification of any neointimal tissue. Table 1 shows an overview of baseline characteristics and clinical outcomes from published studies investigating the use of ELCA for ISR.

A Walk Through the iLASER Algorithm

Identifying patients who may benefit from coronary artery bypass graft surgery or intravascular brachytherapy

The patients presenting with ISR may still develop it within an old BMS. The treatment algorithm is shown in Figure 1 and includes several important steps. The first step encompasses the identification of clinical scenarios where patients may be better treated with non-percutaneous or non-conventional methods such as coronary artery bypass graft surgery (CABG) or intravascular brachytherapy (IVBT). For example in patients with recurrent ISR, rates of repeat revascularization have been reported to exceed 50% within two years.¹⁶ Furthermore, the angiographic pattern of ISR according to the classification holds important prognostic implications.¹⁷ In the original publication, patients were predominantly treated with repeat BMS implantation, often after rotational atherectomy (RA) or excimer laser coronary atherectomy (ELCA); 1 year target lesion revascularization

rates were 19.1% for focal ISR (type 1), 34.5% for proliferative ISR (type 2), 50.0% for proliferative ISR (type 3), and 83.4% for total occlusion ISR (type 4). This study reported significantly better outcomes after ISR if a patient was treated with CABG as compared to PCI. Constantini et al reported 6-month target lesion revascularization rates after treatment of ISR with IVBT in a cohort of 295 patients, the majority of whom had \geq two prior interventions.¹⁸ This study showed relatively favorable re-intervention rates in patients with type 3 and type 4 ISR of 30.2% and 8.3%, respectively.

Identification of mechanical/technical issues using intracoronary imaging and tailored treatment

After performing intracoronary imaging (IVUS or OCT) in the ISR lesion, the presence or absence of any mechanical/technical issues can be determined. For example, if stent underexpansion due to significant peri-stent calcium ($> 90^\circ$) is diagnosed, we recommend ELCA, followed by high-pressure scoring balloon inflation. ELCA has been associated with calcium modification, even in ISR lesions, and may therefore be the preferred mode of atherectomy in this case.¹⁹ If, even after ELCA, the (scoring- or cutting-) balloon is unable to dilate completely, CABG may be preferred, as this suggests that the underlying problem of under-expansion is insufficiently

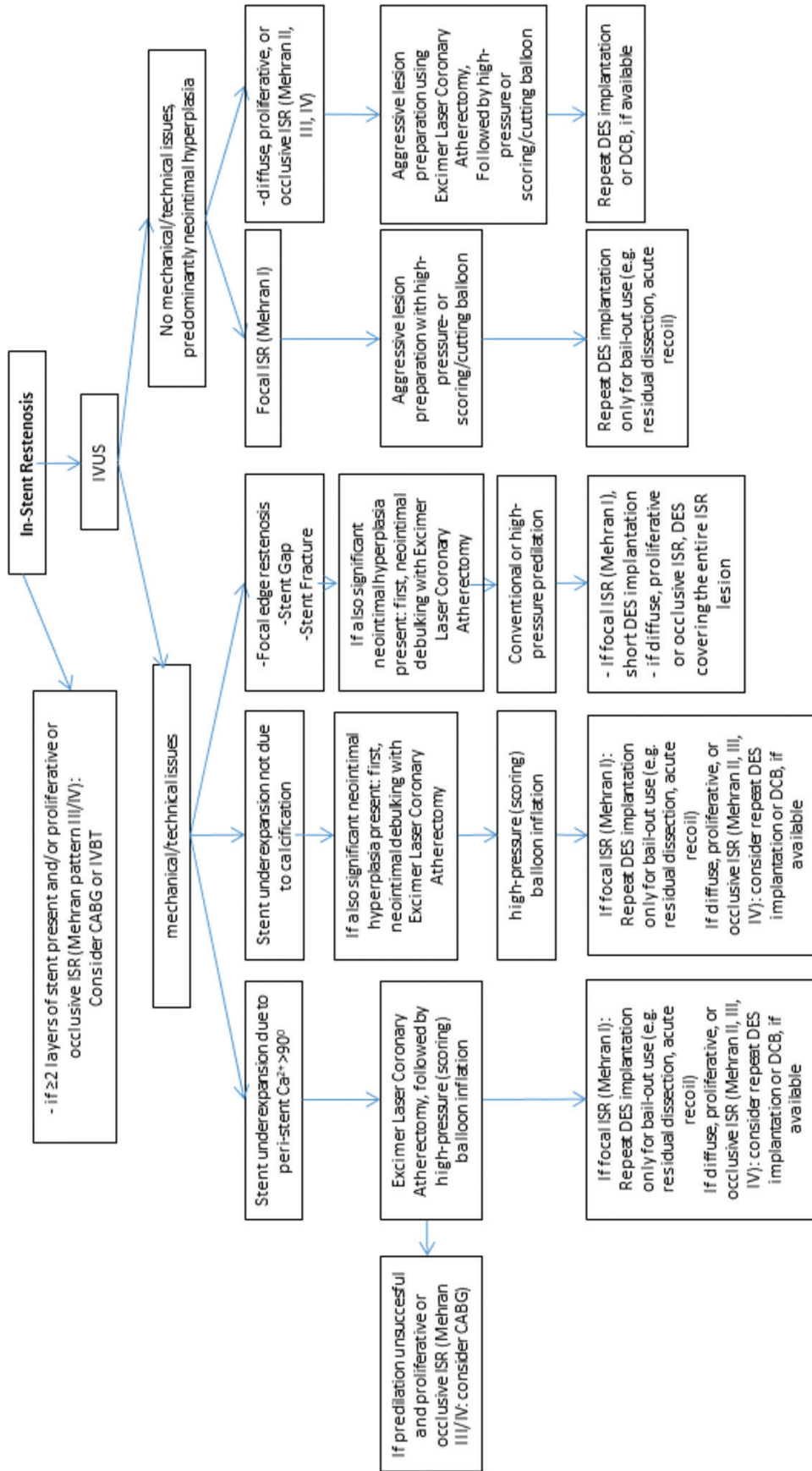


FIGURE 1. IVUS-based algorithm for the treatment of in-stent restenosis. IVUS = intravascular ultrasound; CABG = coronary artery bypass graft surgery; DCB = drug-coated balloon; DES = drug-eluting stent; ISR = in-stent restenosis; IVBT = intravascular brachytherapy; IVUS= intravascular ultrasound

addressed. If ELCA and cutting-/scoring-balloon angioplasty are successful, the decision to treat with additional DES implantation can be made based on the pattern of ISR. As focal ISR has a relatively good prognosis, DES implantation would only be recommended for bailout use, for example, in case of residual dissection. For diffuse, proliferative, or occlusive ISR, which are associated with higher rates of ISR, we recommend routine use of repeat DES implantation or DCB use (if available).

If stent underexpansion not due to calcification is diagnosed, we recommend the use of ELCA only if significant neointimal hyperplasia was also found to be present on IVUS imaging. If there was no or minimal neointimal hyperplasia, high-pressure (scoring) balloon inflation will be sufficient to dilate the lesion. Recommendations for additional stent implantation are similar to the prior scenario of stent under-expansion due to peri-stent calcium.

If focal edge restenosis, stent gap, or stent fracture is identified, we again recommend lesion debulking with ELCA only if significant neointimal hyperplasia is present. We always recommend conventional or high-pressure balloon predilation at the site of the mechanical complication, followed by a short repeat DES implantation in case of focal ISR or a long DES covering the entire lesion in case of diffuse, proliferative, or occlusive ISR.

If IVUS shows no mechanical/technical issues, and ISR is predominantly due to neointimal hyperplasia, treatment is dependent on the pattern of ISR. For focal ISR, aggressive lesion preparation, using a high-pressure or scoring/cutting balloon followed by DES implantation only for bailout use will be sufficient. On the other hand, for diffuse, proliferative, or occlusive ISR, we recommend atherectomy followed by scoring/cutting balloon angioplasty for optimal lesion debulking, followed by repeat DES implantation or DCB angioplasty, if available.

Conclusion

ISR remains a relatively frequent adverse outcome after PCI, even in the modern era of DES, and rates of repeat restenosis remain unacceptably high. A systematic treatment approach aimed at optimizing the acute and long-term results of PCI of ISR lesions using current best practices may be one important step towards improved outcomes. In order to optimize percutaneous treatment of ISR, a systematic approach as outlined in the iLASER algorithm is of paramount importance. This algorithm includes the assessment of the pattern of ISR, the use of intravascular imaging to determine the mechanism of ISR, optimal lesion preparation using scoring balloons and/or ELCA, and finally, repeat DES implantation if deemed necessary or DCB angioplasty if available. In the near future, the iLASER registry will provide insight into clinical outcomes and angiographic and IVUS follow-up of treatment of ISR using the iLASER algorithm.

References

- Dangas G, Fuster V. Management of restenosis after coronary intervention. *Am Heart J* 1996;132:428-436.
- Fischman DL, Leon MB, Baim DS, et al. A randomized comparison of coronary-stent placement and balloon angioplasty in the treatment of coronary artery disease. Stent Restenosis Study Investigators. *N Engl J Med*. 1994;331:496-501.
- Kirtane AJ, Gupta A, Iyengar S, et al. Safety and efficacy of drug-eluting and bare-metal stents: Comprehensive meta-analysis of randomized trials and observational studies. *Circulation*. 2009;119:3198-3206.
- Dangas GD, Claessen BE, Caixeta A, Sanidas EA, et al. In-stent restenosis in the drug-eluting stent era. *J Am Coll Cardiol*. 2010;56:1897-1907.
- Levine GN, Bates ER, Blankenship JC, et al. 2011 ACCF/AHA/SCAI Guideline for Percutaneous Coronary Intervention. A report of the American College of Cardiology Foundation/American Heart Association Task Force on Practice Guidelines and the Society for Cardiovascular Angiography and Interventions. *J Am Coll Cardiol*. 2011;58:e44-e122.
- Baan J Jr, Claessen BE, Dijk KB, et al. A randomized comparison of paclitaxel-eluting balloon versus everolimus-eluting stent for the treatment of any in-stent restenosis: The DARE trial. *JACC Cardiovasc Interv*. 2018;11:275-283.
- Katsanos K, Spiliopoulos S, Kitrou P, et al. Risk of death following application of paclitaxel-coated balloons and stents in the femoropopliteal artery of the leg: A systematic review and meta-analysis of randomized controlled trials. *J Am Heart Assoc*. 2018;7:e011245.
- Neumann FJ, Sousa-Uva M, Ahlsson A, et al. 2018 ESC/EACTS guidelines on myocardial revascularization. *EuroIntervention*. 2019 Feb 20;14(14):1435-1534.
- Alfonso F, Byrne RA, Rivero F, Kastrati A. Current treatment of in-stent restenosis. *J Am Coll Cardiol*. 2014;63:2659-2673.
- Waksman R, Iantorno M. Refractory In-stent restenosis: Improving outcomes by standardizing our approach. *Curr Cardiol Rep*. 2018;20:140.
- Neumann FJ, Sousa-Uva M, Ahlsson A, et al. 2018 ESC/EACTS guidelines on myocardial revascularization. *Eur Heart J*. 2019;40:87-165.
- Levine GN, Bates ER, Blankenship JC, et al. 2011 ACCF/AHA/SCAI guideline for percutaneous coronary intervention: a report of the American College of Cardiology Foundation/American Heart Association Task Force on Practice Guidelines and the Society for Cardiovascular Angiography and Interventions. *Catheter Cardiovasc Interv*. 2013;82:E266-E355.
- Goto K, Zhao Z, Matsumura M, et al. Mechanisms and Patterns of intravascular ultrasound in-stent restenosis among bare metal stents and first- and second-generation drug-eluting stents. *Am J Cardiol*. 2015;116:1351-1357.
- Albiero R, Silber S, Di Mario C, et al. Cutting balloon versus conventional balloon angioplasty for the treatment of in-stent restenosis: Results of the restenosis cutting balloon evaluation trial [RESCUT]. *J Am Coll Cardiol*. 2004;43:943-949.
- Park SJ, Kim KH, Oh IY, et al. Comparison of plain balloon and cutting balloon angioplasty for the treatment of restenosis with drug-eluting stents vs bare metal stents. *Circ J*. 2010;74:1837-1845.
- Theodoropoulos K, Mennuni MG, Dangas GD, et al. Resistant in-stent restenosis in the drug eluting stent era. *Catheter Cardiovasc Interv*. 2016;88:777-785.
- Mehran R, Dangas G, Abizaid AS, et al. Angiographic patterns of in-stent restenosis: Classification and implications for long-term outcome. *Circulation*. 1999;100:1872-1878.
- Costantini CO, Lansky AJ, Mintz GS, et al. Usefulness of the angiographic pattern of in-stent restenosis in predicting the success of gamma vascular brachytherapy. *Am J Cardiol*. 2003;92:1214-1217.
- Lee T, Shlofmitz RA, Song L, et al. The effectiveness of excimer laser angioplasty to treat coronary in-stent restenosis with peri-stent calcium as assessed by optical coherence tomography. *EuroIntervention*. 2019;15:e279-e288.
- Mehran R, Mintz GS, Satler LF, et al. Treatment of in-stent restenosis with excimer laser coronary angioplasty: Mechanisms and results compared with PTCA alone. *Circulation*. 1997;96:2183-2189.
- Koster R, Hamm CW, Seabra-Gomes R, et al. Laser angioplasty of restenosed coronary stents: Results of a multicenter surveillance trial. The Laser Angioplasty of Restenosed Stents [LARS] Investigators. *J Am Coll Cardiol*. 1999;34:25-32.
- Koster R, Kahler J, Terres W, et al. Six-month clinical and angiographic outcome after successful excimer laser angioplasty for in-stent restenosis. *J Am Coll Cardiol*. 2000;36:69-74.
- Mehran R, Dangas G, Mintz GS, et al. Treatment of in-stent restenosis with excimer laser coronary angioplasty versus rotational atherectomy: comparative mechanisms and results. *Circulation* 2000;101:2484-2489.
- Hirose S, Ashikaga T, Hatano Y, et al. Treatment of in-stent restenosis with excimer laser coronary angioplasty: Benefits over scoring balloon angioplasty alone. *Lasers Med Sci*. 2016;31:1691-1696.
- Ambrosini V, Golino L, Niccoli Gm, et al. The combined use of drug-eluting balloon and excimer laser for coronary artery restenosis in-stent treatment: The DERIST study. *Cardiovasc Revasc Med*. 2017;18:165-168.
- Ichimoto E, Kadohira T, Nakayama T, De Gregorio J. Long-term clinical outcomes after treatment with excimer laser coronary atherectomy for in-stent restenosis of drug-eluting stent. *Int Heart J*. 2018;59:14-20.
- Hashimoto S, Takahashi A, Mizuguchi Y, et al. The impact of tissue characterization for in-stent restenosis with optical coherence tomography during excimer laser coronary angioplasty. *Cardiovasc Interv Ther*. 2019;34:171-177.

In-Stent Restenosis: Tools and Techniques

Jasvinder Singh, MD, FACC; and Adam Shpigel, MD

The mechanisms of in-stent restenosis (ISR) are varied, with the most common causes including neointimal hyperplasia, neoatherosclerosis within the stent, stent underexpansion, and stent fracture. Each of these etiologies requires a distinct therapeutic strategy in order to treat the immediate clinical presentation and prevent future recurrence. In this portion of the supplement, the tools and techniques for treatment of in-stent restenosis will be examined, offering the interventionalist a broad armamentarium for the treatment of this common phenomenon.

Intravascular Ultrasound

The use of intracoronary imaging is integral to the treatment of in-stent restenosis for several reasons. Our lab makes frequent use of intravascular ultrasound (IVUS) for this purpose, the Eagle Eye Platinum digital IVUS catheter (Philips), in particular. This is necessary for establishing the etiology of the ISR, establishing the size of the vessel, and determining a treatment strategy. Following treatment of the lesion, either by angioplasty or stenting, we perform repeat IVUS to establish adequacy of treatment and appropriate stent expansion and apposition.

Specialty Balloons

In our practice, we make extensive use of specialty balloon angioplasty for the treatment of in-stent restenosis. These balloons can be used for controlled high-pressure inflation for dilation of an underexpanded stent. Additionally, these balloons can be inflated at high pressure in the setting of neointimal hyperplasia or neoatherosclerosis. Depending on the circumstance, we will sometimes use specialty balloon angioplasty as a standalone technique, particularly if the angiographic result is adequate or in vessel segments that have already been stented multiple times. In other cases, these balloons are used for predilation prior to placement of an additional drug-eluting stent. The two balloons that we commonly use in clinical practice are the AngioSculpt PTCA balloon (Philips) (Figure 1) and the Chocolate balloon (Teleflex) (Figure 2).

AngioSculpt PTCA Balloon

The AngioSculpt PTCA balloon is a specialty scoring balloon often used in the treatment of in-stent restenosis, particularly when caused by neointimal hyperplasia. The defining feature of the AngioSculpt PTCA balloon is the presence of three nitinol scoring edges running down the length of the balloon. These scoring edges are rectangular in cross section and are designed to lock into fibrous tissue or atherosclerotic plaque. These edges limit the incidence




FIGURE 1. The AngioSculpt PTCA scoring balloon catheter.

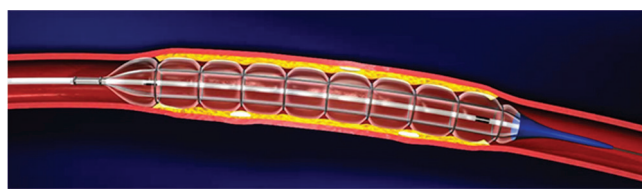


FIGURE 2. The Chocolate balloon.

of device slippage or “watermelon seeding,” even within highly fibrotic tissue within a stent. Additionally, the leading edges of the scoring elements exert a force of up to 15 to 25 times that of a conventional angioplasty balloon at the point of contact. The coronary AngioSculpt PTCA balloon is available in diameters from 2 to 3.5 mm and in a variety of lengths. The newest iteration of the AngioSculpt PTCA balloon has smooth transitions, substantially improving deliverability. All sizes are compatible with a 6-F guide catheter. In our practice, the AngioSculpt PTCA balloon should be inflated slowly, at approximately one atmosphere every 5 seconds, to optimize the engagement of the atherotomes and provide the most effective angioplasty. In our experience, the AngioSculpt PTCA balloon is a very useful tool in the treatment of in-stent restenosis, both as a standalone treatment and for lesion dilation prior to placement of a stent.

Chocolate Balloon

The Chocolate balloon is a unique angioplasty balloon design which we use extensively in settings of in-stent restenosis caused by neointimal hyperplasia and stent underexpansion.

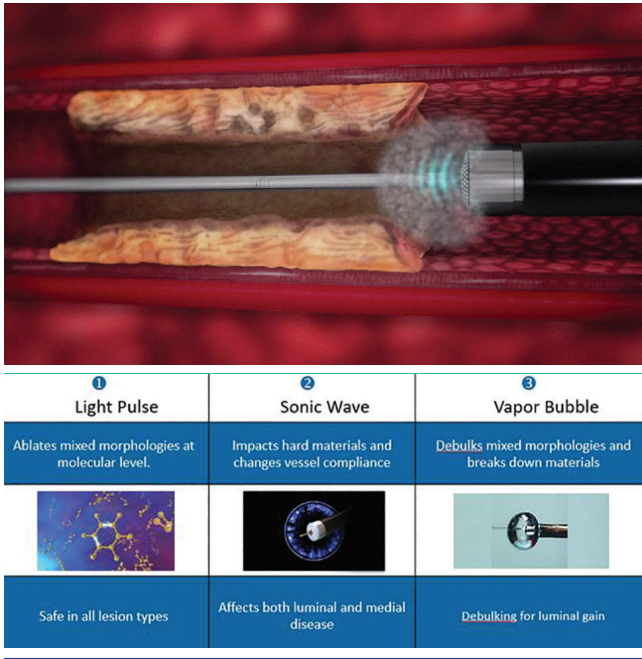


FIGURE 3. Laser atherectomy.

The unique structure of the Chocolate balloon consists of a nitinol constraining structure surrounding the balloon. As evident from the figure, this creates a series of alternating pillows and grooves. These are designed to provide predictable and uniform dilatation while minimizing the risk of dissection. Conventional angioplasty applies radial, longitudinal, and torsional force during expansion, which can cause trauma to the vascular wall and possible dissection. By its design, the Chocolate balloon can ameliorate these traumatic forces while still providing robust vessel dilatation and lesion modification. Sizes from 2 to 3.5 mm are available in a variety of lengths, with the 2- and 2.5-mm sizes 5-Fr compatible, and the larger sizes 6-Fr compatible.

Noncompliant Balloons

Noncompliant coronary balloons are widely used in the predilatation of restenotic lesions, especially in the setting of prior stent underexpansion. We use the NC Emerge and Sapphire balloons predominantly in our cath lab. These lesions often require high-pressure inflations in the setting of prior stent underexpansion.

Laser Atherectomy

Laser atherectomy has emerged as an invaluable tool for treatment of in-stent restenosis. Neointimal hyperplasia is particularly well treated by laser atherectomy (Figure 3). In our lab, laser atherectomy is frequently used for the treatment of in-stent restenosis, particularly in the setting of multiple layers of stent or a heavily fibrotic segment of disease.

Coronary lasers are classified as excimer lasers, using a gas mixture as a medium to generate high-energy ultraviolet

light. There are three mechanisms by which the laser operates to ablate fibrous tissue and plaque. The light pulse mechanism is that by which the energy from the laser breaks carbon-carbon bonds in the fibrous tissue, thus ablating it. The sonic wave mechanism is that by which pulsed waves are generated by the laser “cracking” hard materials and changing vessel compliance. The sonic waves affect both luminal and medial disease. The third mechanism action is driven by the vapor bubble at the distal tip of the catheter. When this vapor bubble expands and bursts, it addresses mixed lesion morphologies and debulks for luminal gain. The small size of the released particles generally does not obstruct the distal circulation.

The ELCA (excimer laser coronary atherectomy) catheter and CVX-300 laser system (Philips) is used frequently in our cath lab. This laser uses XeCl as the gas medium for production of the laser. The catheter comes in various diameters, and there are different guidelines for selecting a size for a given vessel. In our practice, the 0.9-mm laser is the most frequently used in the coronary circulation. The size of the vapor bubble is approximately 2.5 times the diameter of the catheter. The 0.9-mm laser is 6-Fr guide compatible and has a short mono-rail segment. Prior to use, the laser must be calibrated per manufacturer instructions.

The laser’s fluence and rate must be chosen prior to atherectomy. Fluence is the energy of the laser and rate is the number of pulses per second. We frequently use a fluence of about 45 and rate of 45, but these can be adjusted according to clinical circumstance, up to a fluence of 80 and a rate of 80.

Importantly, the rate of laser advance must be very slow. The recommended speed is approximately 1 mm per second. If the laser is advanced too quickly, it is unlikely to have time to properly modify the lesion. Several runs may be undertaken at the operator’s discretion.

Other Atherectomy

There are occasional reports of rotational atherectomy being used for treatment of in-stent restenosis. This is associated with risks including damage to the stent, embolization of metallic debris, and damage to the rotational atherectomy system. This should only be considered as a salvage approach and only by operators experienced in the use of rotational atherectomy for other lesion types.

The use of orbital atherectomy in in-stent restenosis is listed as a contraindication per manufacturer guidelines and has not been widely attempted given concern for damage to the stent or orbital atherectomy system.

Miscellaneous Tools and Techniques

Delivery of balloons and stents can be difficult across previously placed stents. When difficulty delivering equipment is encountered, a number of approaches can be taken. Angioplasty of a stented segment, when possible, often improves delivery of subsequent equipment, especially if the previously placed stent is underexpanded.

In some cases, difficulty with advancing balloons or stents can be attributable to unfavorable wire bias. In these cases, because of the orientation of the wire within the vessel, the leading edge of the balloon or stent that is being delivered may be obstructed by a previously placed stent. It can be helpful to place another coronary wire, a “buddy wire,” alongside the initially placed wire, in these cases. This may straighten the vessel and potentially offer more favorable wire bias for advancing equipment. If a stent is being placed, it is imperative to remember to remove the other wire prior to stent deployment, otherwise the wire will be trapped between two layers of stents and may be very difficult to remove.

If we are having difficulty advancing equipment in the setting of previously placed stents, we will frequently reach for a guide extender, such as the Guidezilla (Boston Scientific) or the Guideliner (Teleflex) (Figure 4). The Guideliner is shown in the figure for illustration. These can be advanced to, or even distal to, the area causing delivery difficulty. If there is difficulty advancing the guide extender, we frequently make use of the inchworm technique, in which a balloon is advanced immediately distal to the guide extender and inflated. The balloon is then deflated, and during deflation, forward pressure is applied to the guide extender in an effort to slide the extender over the balloon. If a stent is to be placed, we will often leave the guide extender distal to the lesion, place the stent in approximately the right position, and then withdraw the guide extender so that the stent may be deployed.

The Wiggle Wire (Figure 5) is an interesting piece of technology which we have increasingly started to use in the setting of difficult delivery. The Wiggle Wire has a shaped distal segment starting 6 cm proximal to the tip and consisting of three “waves” with an amplitude of approximately 3 mm, as can be seen in the figure. These bends can improve deliverability by moving the balloon or stent to be delivered away from the wall of the vessel and the previously placed stent. We generally reserve use of the Wiggle Wire for delivery difficulty despite use of the previously noted techniques.

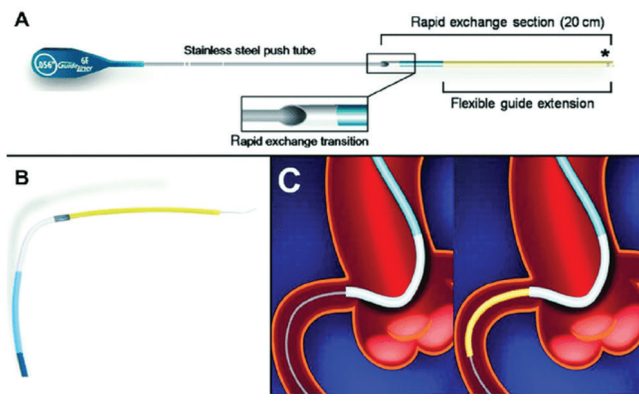


FIGURE 4. The Guideliner device.




FIGURE 5. The Wiggle Wire device.

Conclusion

While the rate of in-stent restenosis has dropped dramatically in the era of drug-eluting stents, it remains an important clinical entity with which the interventional cardiologist must be familiar. We cannot overstate the importance of intracoronary imaging in identifying the etiology and correctly addressing the likely cause. We now have a plethora of tools for managing in-stent restenosis including specialty balloons, noncompliant angioplasty balloons, and laser atherectomy, and several ways to overcome the difficulty in delivering these devices. While in-stent restenosis can be challenging to treat, our variety of tools and techniques will, in the hands of a thoughtful operator, result in procedural success.

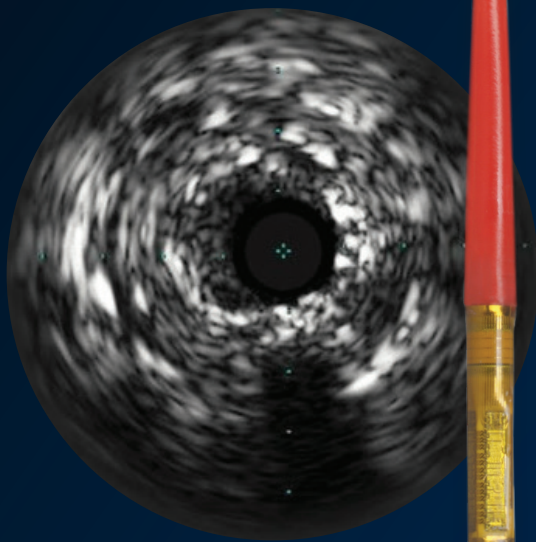
PHILIPS

Image Guided Therapy

Coronary Vascular

Defeat ISR

Treat in-stent restenosis (ISR) using IVUS guidance and the only scoring balloon and atherectomy catheter indicated for ISR.



Eagle Eye Platinum
digital IVUS catheter



ELCA laser
atherectomy catheter



AngioSculpt PTCA
scoring balloon catheter

See clearly.
Treat optimally.

Refer to full device labeling and instructions for important safety information.
Caution: Federal law restricts these devices to sale by or on the order of a physician.

©2019 Koninklijke Philips N.V. All rights reserved. Some or all products manufactured by Spectranetics, a Philips company. Approved for external distribution. D052424-00 092019