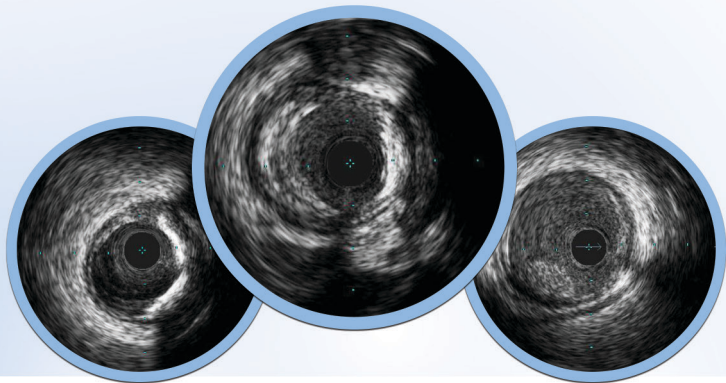
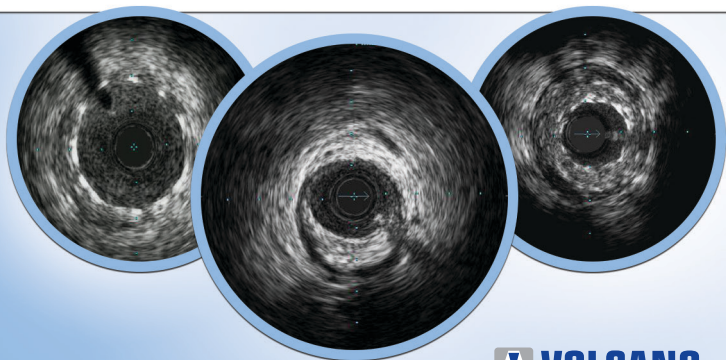


Revolution[®]

Catheter



Rotational IVUS Image Interpretation Pocket Guide

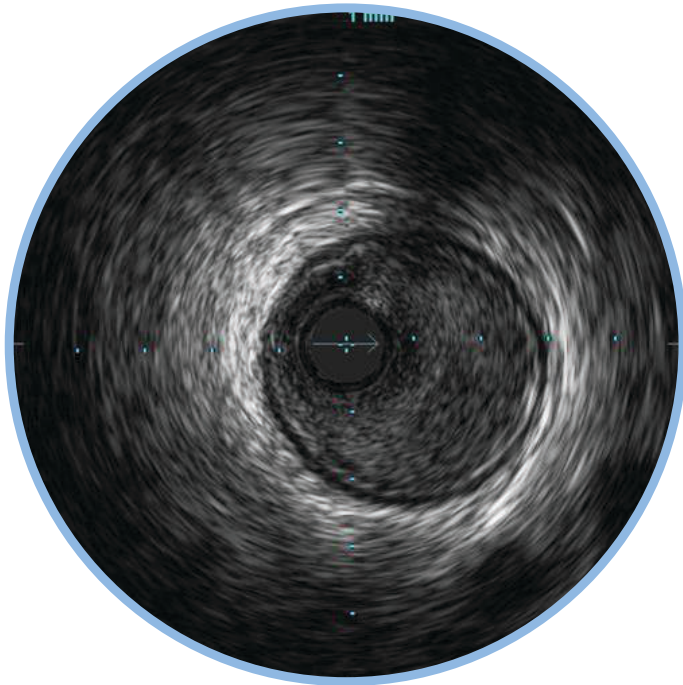


CONTENTS

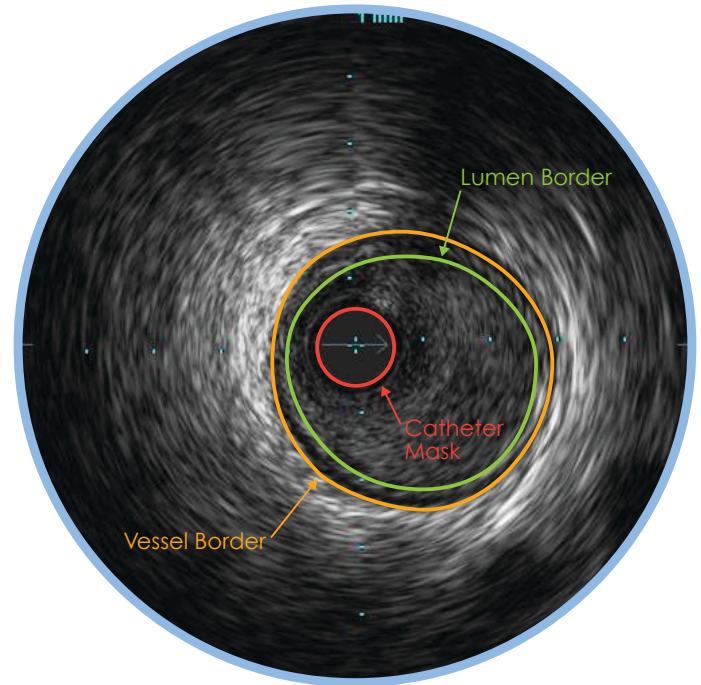
- 4** Normal Vessel
- 6** Concentric Mixed Plaque
- 8** Eccentric Mixed Plaque
- 10** Fibrous Plaque
- 12** Plaque with Calcium
- 14** Under Expanded Stent
- 16** Stent with Complete Apposition
- 18** Stent with Malapposition
- 20** Vessel Branches Merging
- 22** Vein Graft Dissection
- 24** Intra Luminal Thrombus
- 26** Hi-Q™ Imaging Options

NORMAL VESSEL

- ▶ In a normal vessel, the lumen border is almost indistinguishable from the vessel border. While IVUS allows visualization of vessel and lumen, angiograms only provide a shadow of the lumen. In patients with diffuse disease, relying on the angiogram alone can potentially lead to underestimation of stenosis.

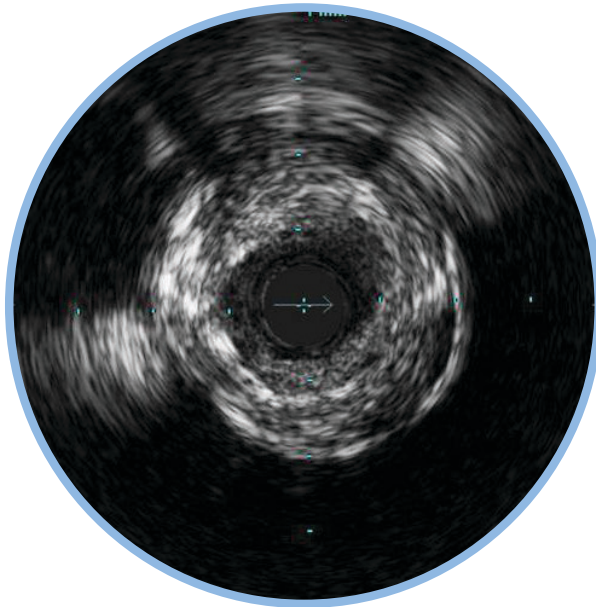


- ▶ The lumen border is drawn inside the intima or plaque.
- ▶ The intimal layer is normally not seen unless it has begun to thicken.
- ▶ The catheter mask (red area) indicates the location of the ultrasound transducer.
- ▶ The media is the dark band between the adventitia and the intima.

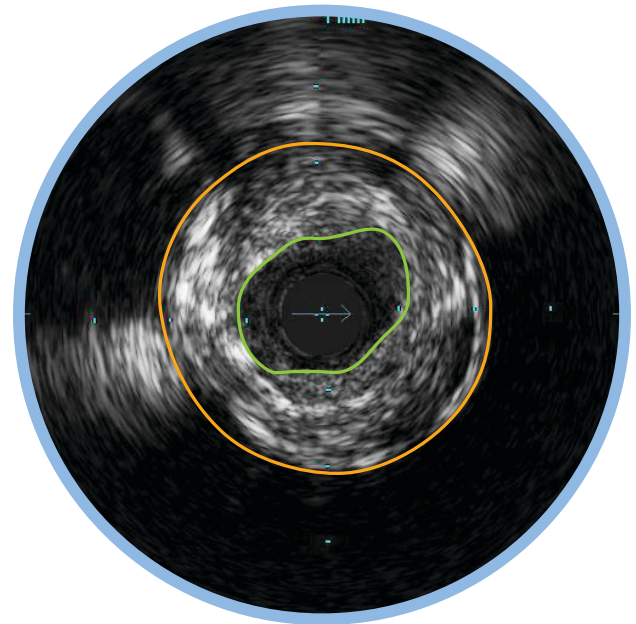


CONCENTRIC MIXED PLAQUE

- ▶ Concentric plaques are distributed circumferentially in the vessel.
- ▶ Concentric plaques tend to occur in areas of negative remodeling; use of angiography alone could result in too large a stent diameter.
- ▶ Mixed plaque is a combination of tissues of varying echogenicity. The distribution of light and dark may be distinct, or light and dark variations may be intermingled as shown here.



- ▶ Minimum Lumen Area (MLA) can define a threshold for a significant stenosis to determine the need for catheter-based or surgical intervention.
 - MLA $< 4 \text{ mm}^2$ in LAD, LCX, and RCA vessels $> 3 \text{ mm}$ in diameter correlates with physiological significance¹
 - MLA $< 6 \text{ mm}^2$ in left main correlates with FFR < 0.75 indicating physiological significance^{1,2,3}

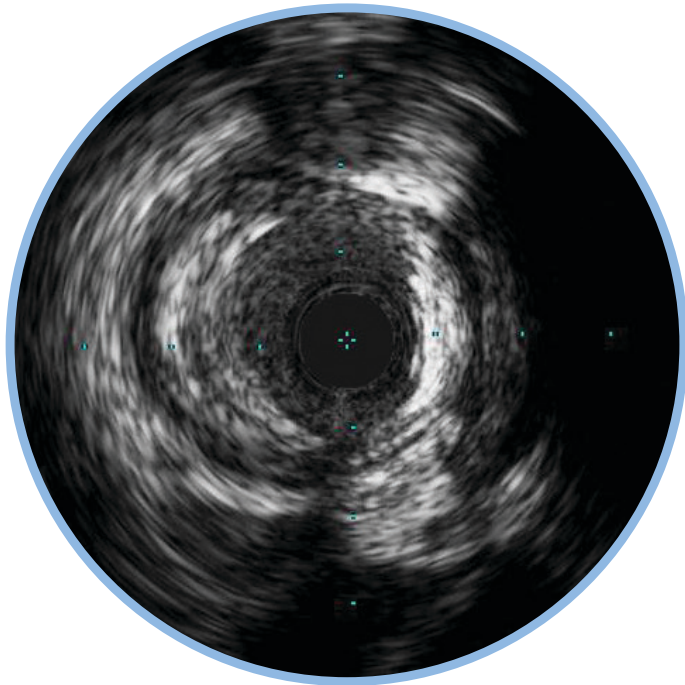


1. Jasti, et al. Correlations between fractional flow reserve and intravascular ultrasound in patients with an ambiguous left main coronary artery stenosis *Circulation*, 2004;110:2831-2836.
2. Jose M. de la Torre Hernandez et al. Prospective Application of Pre-Defined Intravascular Ultrasound Criteria for Assessment of

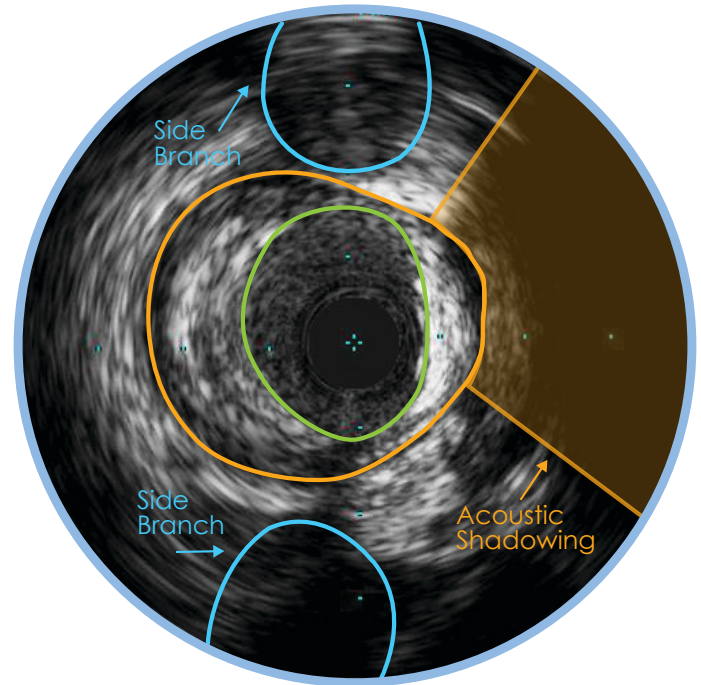
Intermediate Left Main Coronary Artery Lesions: Results From the Multicenter LITRO Study, *J Am Coll Cardiol*, 2011 58: 351-358.
3. Levine et al. 2011 ACCF/AHA/SCAI Guideline for Percutaneous Coronary Intervention. *J Am Coll Cardiol*, 2011; 58:44-122.

ECCENTRIC MIXED PLAQUE

- ▶ Eccentric plaques are distributed non-circumferentially in the vessel; this makes the assessment of disease by angiography especially prone to underestimation or overestimation depending on the angle of view.

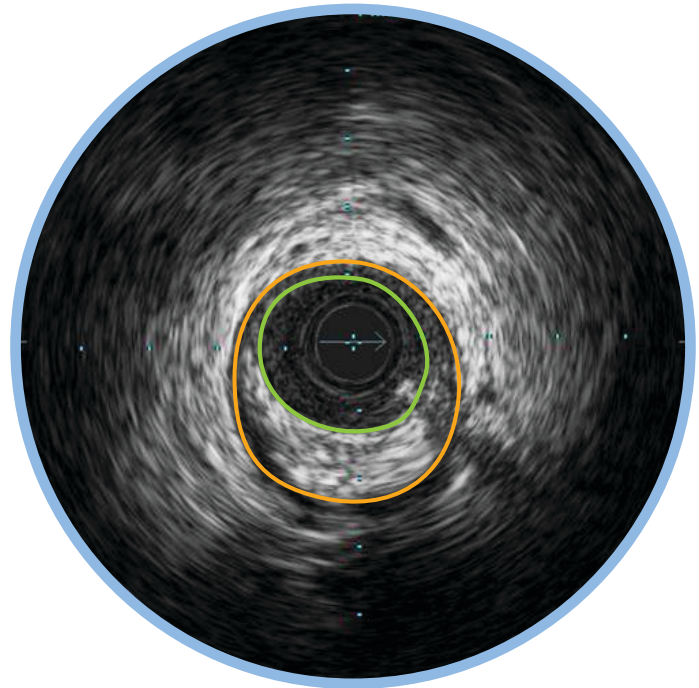
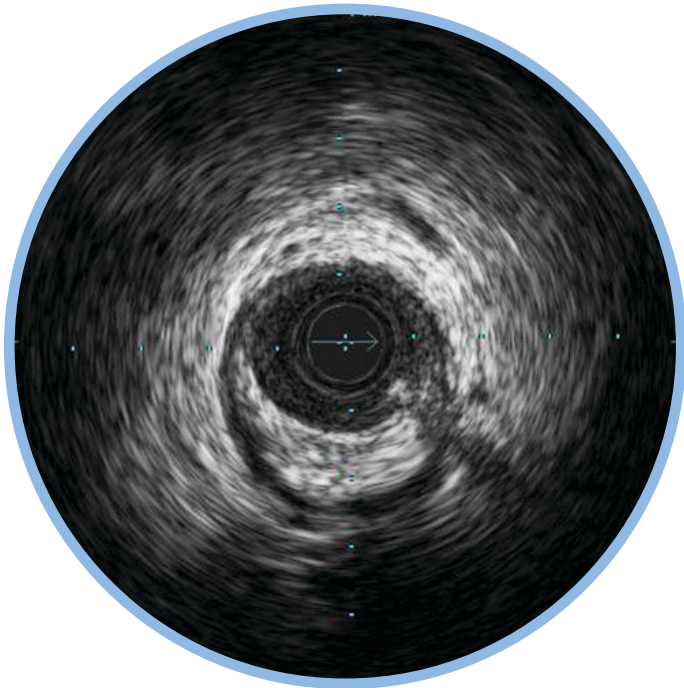


- ▶ Calcium is indicated by very bright areas with acoustic shadowing that blocks out the image behind. This shadowing occurs because the high density of calcium dampens the ultrasound echo.
- ▶ Nearby vessels on the periphery can be seen moving in and out of the field of view and can be used as landmarks.



FIBROUS PLAQUE

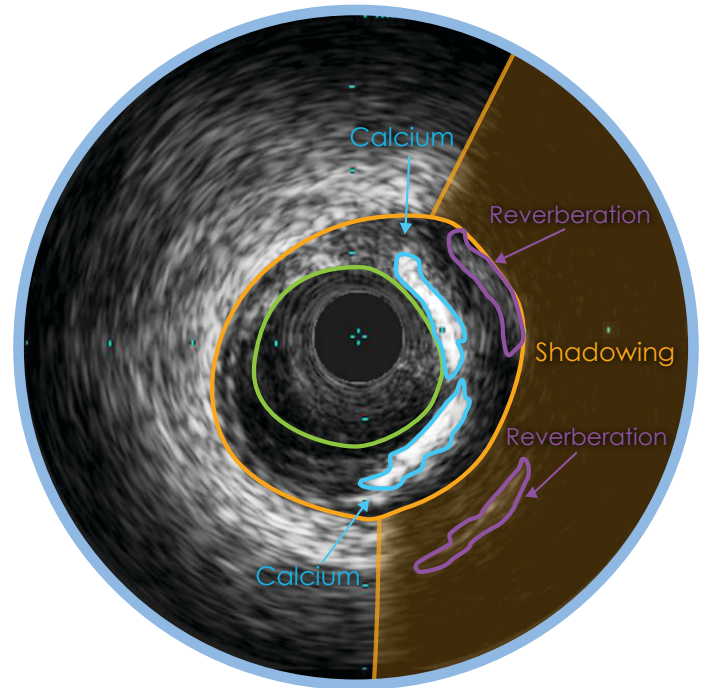
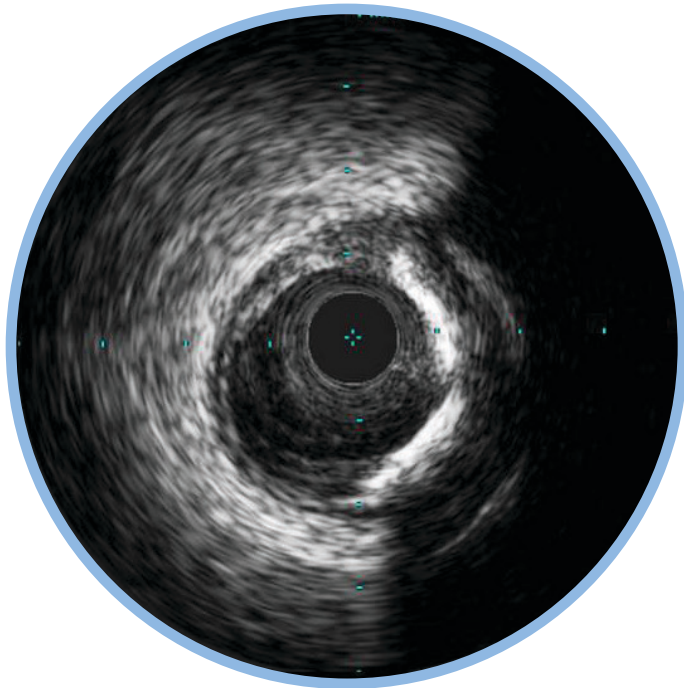
- ▶ These plaques have an intermediate echogenicity between soft (echolucent) atheromas and highly echogenic calcific plaques.
- ▶ Fibrous plaques exhibit little or no acoustic shadowing.



PLAQUE WITH CALCIUM

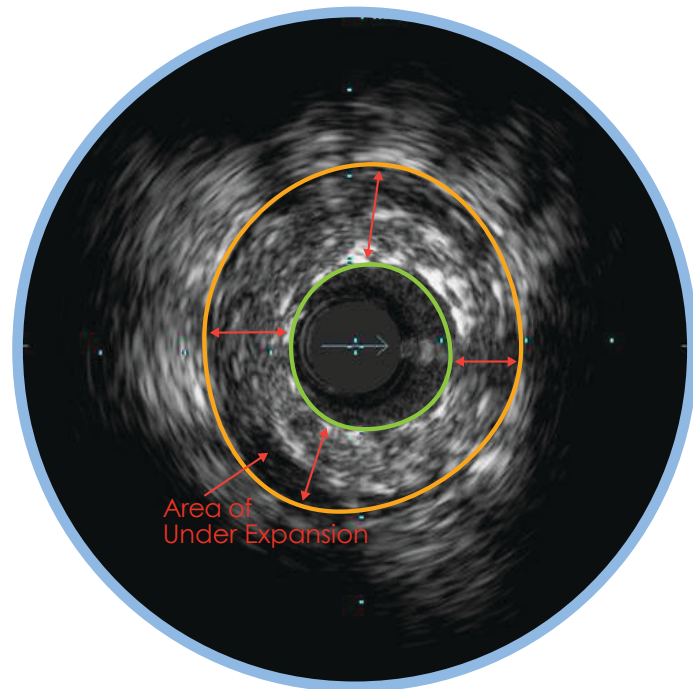
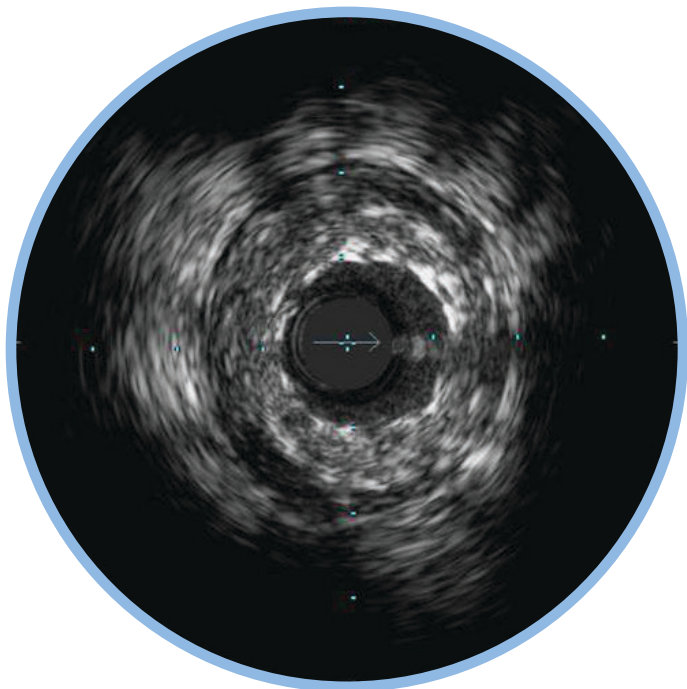
- ▶ There are two large bands of calcium in this plaque with acoustic shadowing arcs behind them.
- ▶ Calcium is indicated by very bright areas with acoustic shadowing that blocks out the image behind it. Reverberations may also be seen. This shadowing occurs because the high density of calcium prevents the ultrasound from passing through.

- ▶ Detection of calcium is a critical factor in determining the optimal PCI strategy.
- ▶ Study data comparing IVUS and angiographic based assessments of calcium reported that IVUS detected calcium significantly more often.*



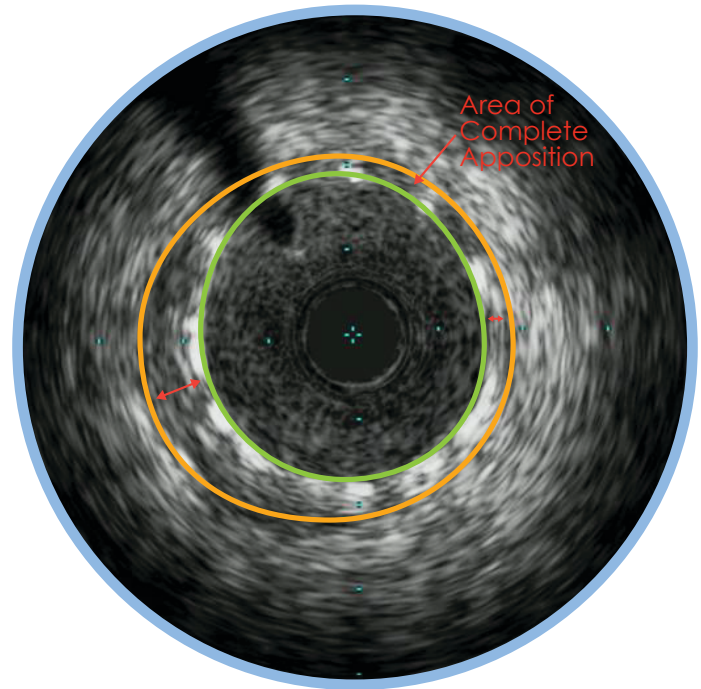
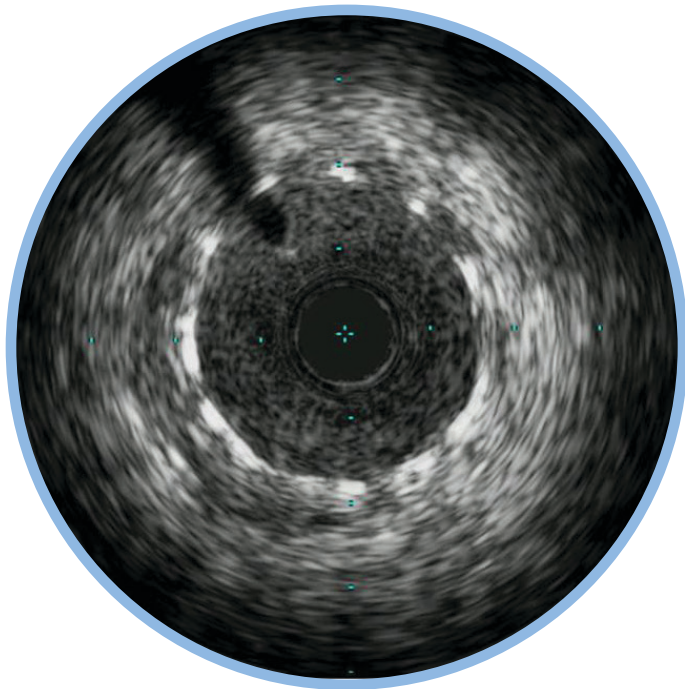
UNDER EXPANDED STENT

- ▶ Stent struts appear as bright marks spaced around the lumen (eleven struts seen here).
- ▶ Large presence of plaque behind stent struts may indicate under-expansion.
- ▶ Device size is an independent predictor of stent thrombosis*



STENT WITH COMPLETE APPOSITION

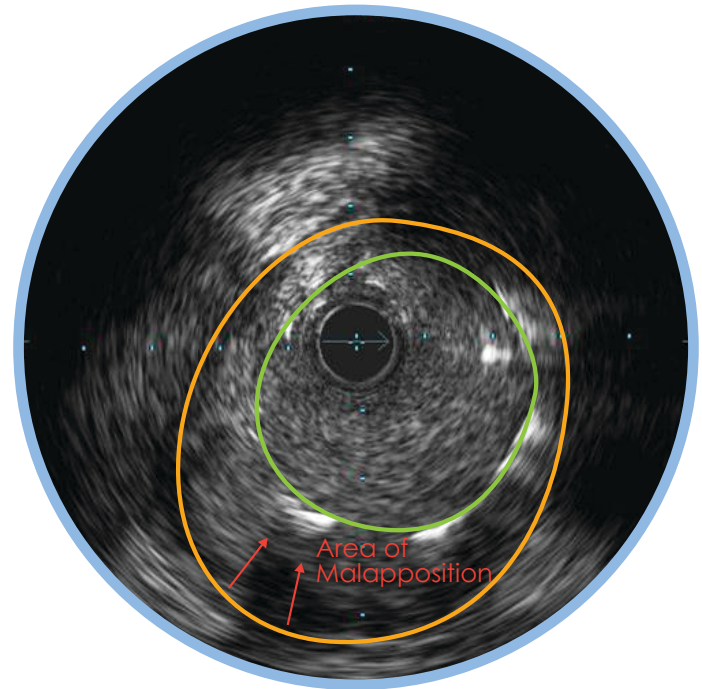
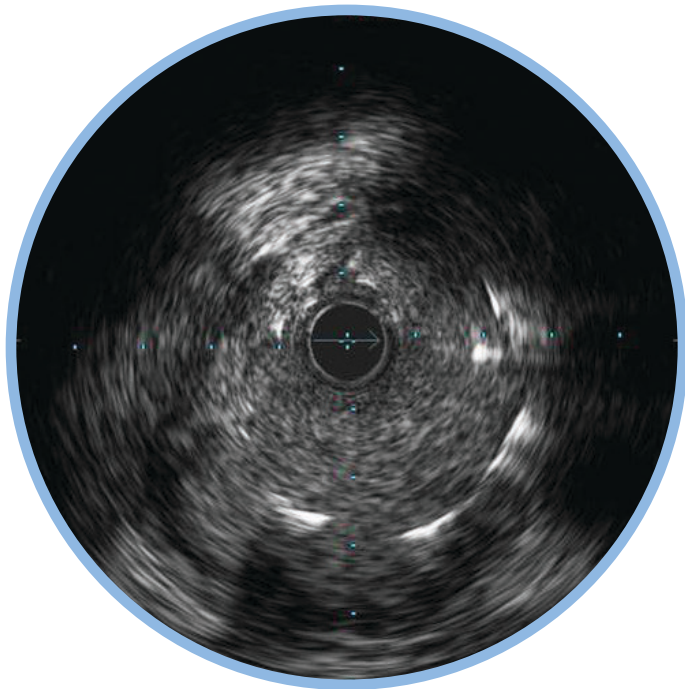
- ▶ Complete apposition is indicated by consistent stent strut contact with tissue.
- ▶ Complete apposition does not guarantee that a stent is not under-sized or under-expanded.



STENT WITH MALAPPOSITION

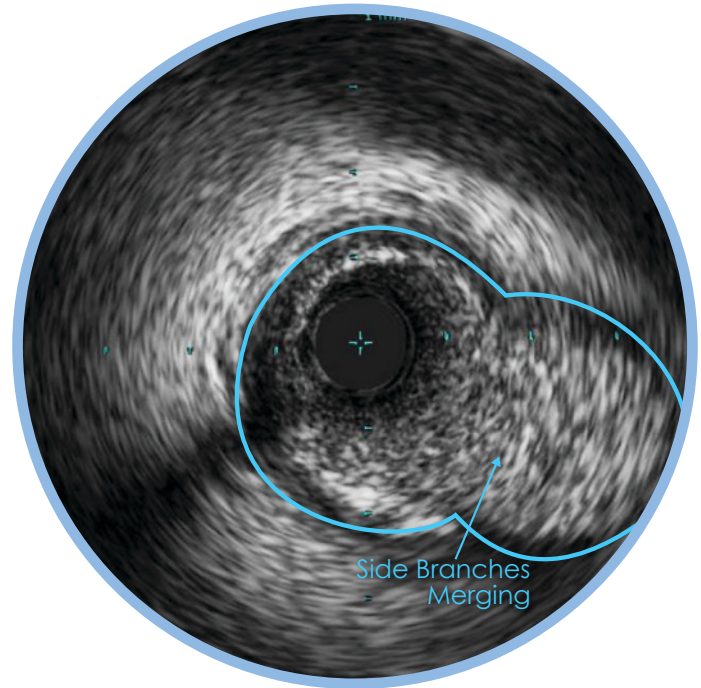
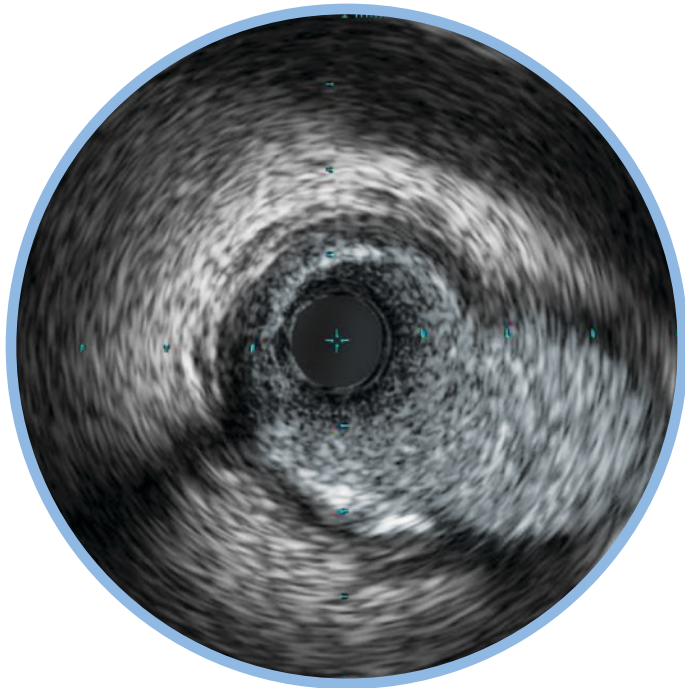
- ▶ Malapposition is indicated by blood visible behind stent struts.
- ▶ Blood may appear as a very faint speckle or black on grayscale IVUS.

- ▶ Stents may be completely or only partially malapposed depending on how much of the stent is in contact with the lumen wall.



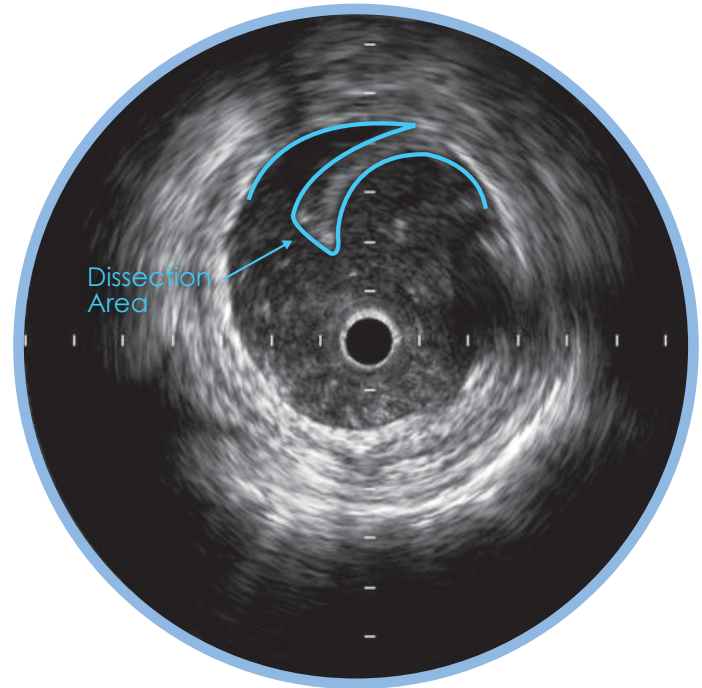
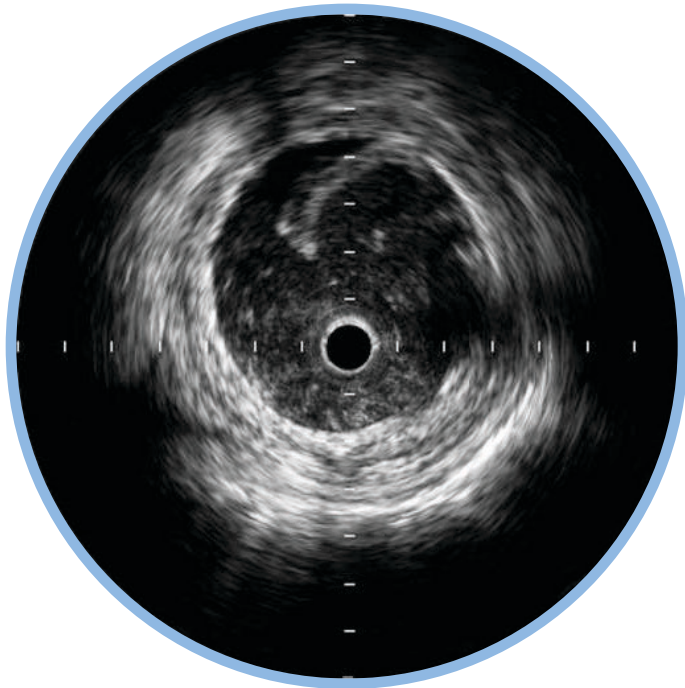
VESSEL BRANCHES MERGING

- ▶ Nearby side branches can act as landmarks.
- ▶ Side branches can be used to determine where or where not to stent within a vessel.



VEIN GRAFT DISSECTION

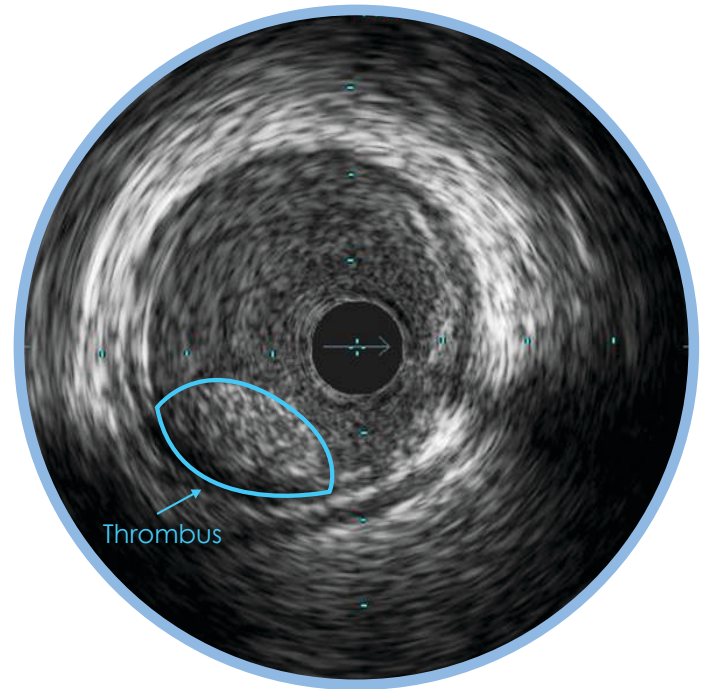
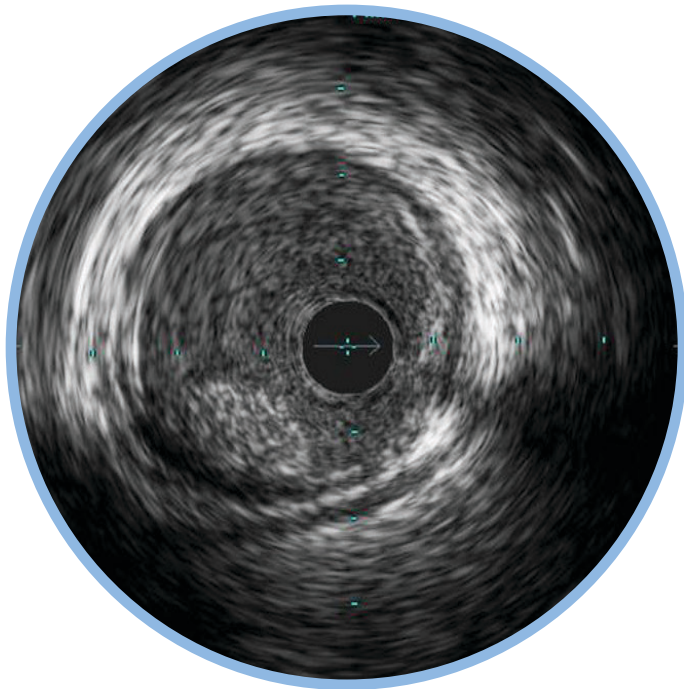
- ▶ A dissection, or tear in the vessel wall can be seen as a flap with blood flow behind it.
- ▶ Only the intimal layer is dissected.
- ▶ When detecting a dissection, the catheter may be flushed with contrast to reduce the blood speckle.



INTRA LUMINAL THROMBUS

- ▶ Thrombus is usually circular in appearance and non-stationary.
- ▶ When viewed during a pullback, thrombus first appears small in size becoming larger and then smaller again.

- ▶ When detecting a thrombus, the catheter may be flushed with contrast to highlight the contours.

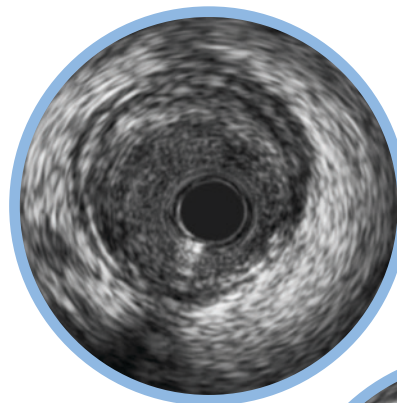


HI-Q™ IMAGING OPTIONS

Hi-Q™ Imaging¹ Allows You to Customize Your Image to Better Identify Lumen Features

Choose from three high quality², optimized imaging modes with different levels of darkness and fineness of blood speckle:

- ▶ May help differentiate between tissue and blood along the lumen border
- ▶ May help identify stent struts, dissection, or other lumen features

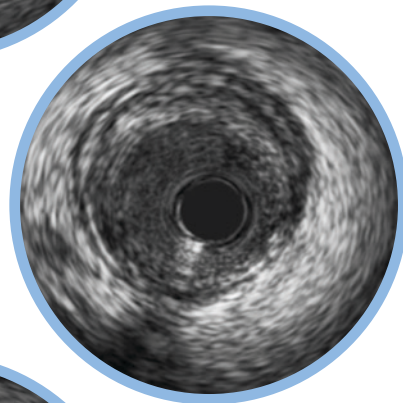


Hi-Q OFF

Imaging equivalent to systems with software versions prior to v.3.3.

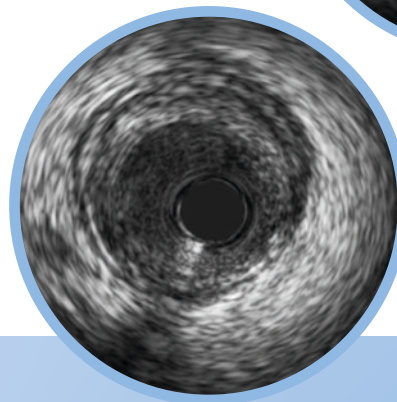
Hi-Q LEVEL 1

Imaging with a darker and finer blood speckle appearance than in the Off mode. Level is also the default mode¹ for new systems.



Hi-Q LEVEL 2

Imaging with an even darker and finer blood speckle appearance than in the Level 1 mode.



See What You've Been Missing With IVUS

Stent Sizing

Angiography

Must rely on "eyeball" estimate.

IVUS

Enables you to make lumen and reference vessel measurements that can be used when selecting stent size.

Stent Expansion and Apposition

Angiography

Cannot see the vessel wall to verify optimal placement.

IVUS

User-defined cross-sectional area measurements and views allow verification and documentation of stent placement.

Normal Vessels vs. Diffuse Disease

Angiography

Tends to underestimate degree of stenosis in diffuse disease¹ or with positive remodeling.

IVUS

Helps you distinguish normal from abnormal vessels and find the location of disease in patients with a normal angiogram.

Concentric and Eccentric Plaques

Angiography

Must rely on "eyeball" estimate. Assessment of eccentric plaque lesion size especially prone to error based on angle of view.

IVUS

Helps you get an accurate lumen area to determine lesion significance and stent size.

Calcium

Angiography

Less sensitive than IVUS for detecting calcium¹

IVUS

Makes the presence of calcium clear, helping to identify lesions that need pre-treatment.

Dissection

Angiography

Cannot determine where the dissection begins.

IVUS

Can be determined.

Thrombus

Angiography

Difficult to determine.

IVUS

Can be determined.

Side Branches Merging

Angiography

Cannot tell how diseased the vessels are.

IVUS

Helps to determine where to place or not place a stent as well as providing information on the disease state in the ostium and side branch.

1. Reference vessels are diseased 93% of the time. Mintz et al. Patterns of Calcification in Coronary Artery Disease A Statistical Analysis of Intravascular Ultrasound and Coronary Angiography in 1155 Lesions JACC 25: 7:1479-85, June 1995.

Volcano Corporation

Corporate Headquarters

3721 Valley Centre Drive, Suite 500

San Diego, CA 92130 USA

Phone: 800-228-4728

Fax: 858-720-0325

Volcano Corporation

Manufacturing Headquarters

2870 Kilgore Road

Rancho Cordova, CA 95670 USA

Phone: 800-228-4728

Fax: 916-638-8812

Volcano Europe SPRL/BVBA

Europe Headquarters

Excelsiorlaan 41

B-1930 Zaventem Belgium

Phone: +32-2-679-1076

Fax: +32-2-679-1079

Volcano Japan Co., Ltd

Japan Headquarters

Hamamatsucho Square 6F

1-30-5, Hamamatsucho,

Minato-ku, Tokyo 105-0013, Japan

Phone: +81-3-6430-9400

Fax: +81-3-6430-9401



PRECISION GUIDED THERAPY