



Percutaneous Revascularization of Left and Right Superficial Femoral Arteries (SFA) by Dr. Dippel

The opinions and clinical experiences presented herein are for informational purposes only. Dr. Dippel is a paid consultant for Philips Volcano. The results from these case study may not be predictive for all patients. Individual results may vary depending on a variety of patient-specific attributes and related factors.

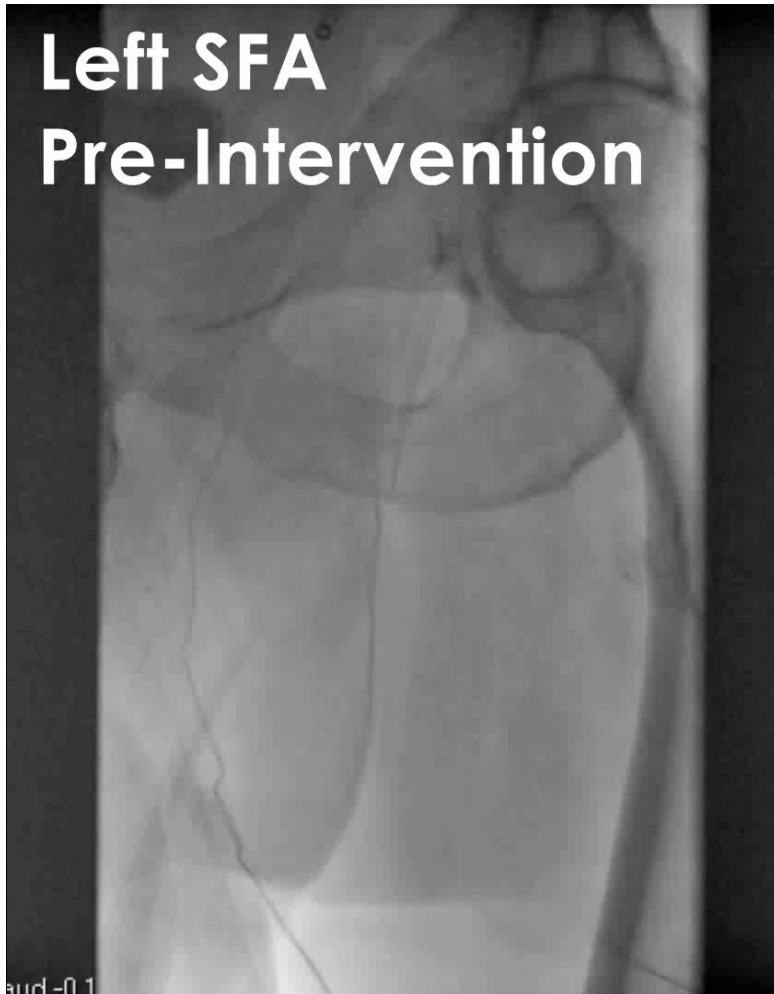
Patient Presentation

- 62 year old male
- Bilateral calf claudication
- Pre-intervention ABI values:
 - Left side = 0.61
 - Right side = 0.62
- Hypertension, hyperlipidemia, obesity

Treatment Strategy

- Peripheral angiogram with percutaneous revascularization for symptom relief
- Open total occlusions of SFA arteries utilizing laser atherectomy and peripheral vascular stenting if needed
- Staged intervention strategy
 - Left leg intervention followed by right leg intervention one month later

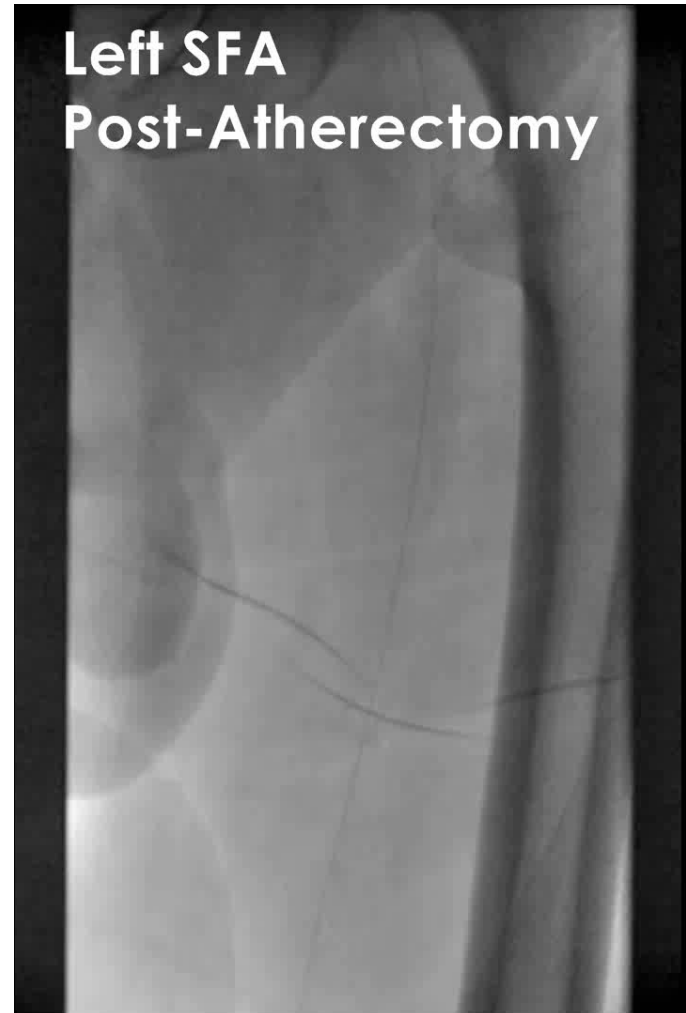Angiographic Observations



- Left and right SFAs totally occluded proximally
- SFAs reconstitute in the adductor canal via collaterals from the profundus

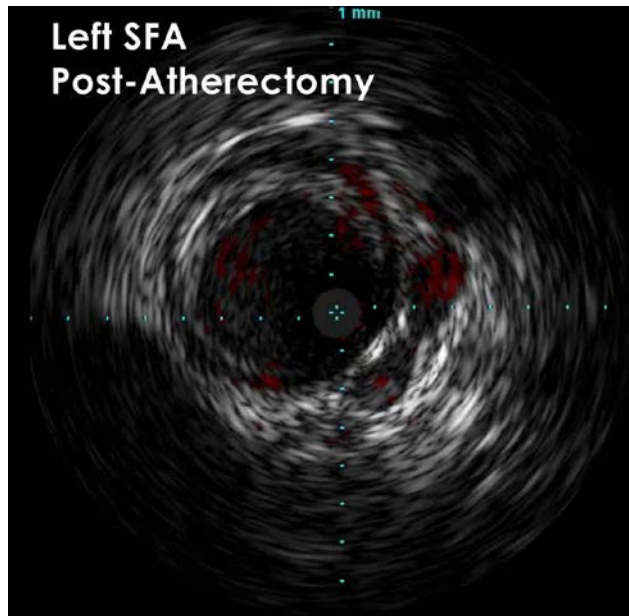
Angiographic Observations

- Atherectomy and balloon dilation were performed on left and right SFAs

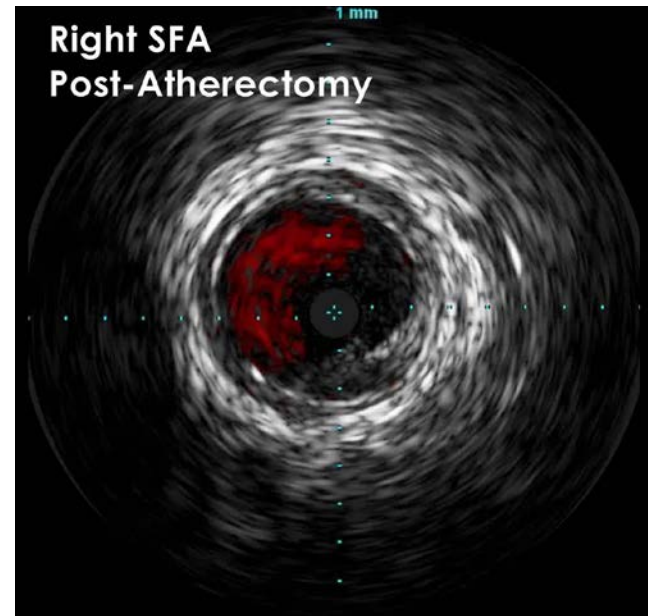

IVUS Observations

IVUS with ChromaFlo was used to assess the result post-atherectomy and balloon dilatation to help determine whether stenting was needed



IVUS performed on the left SFA showed localized dissection in the proximal and mid segments of the vessel, with acceptable results in other segments.



IVUS showed a significant dissection throughout the length of the right SFA.

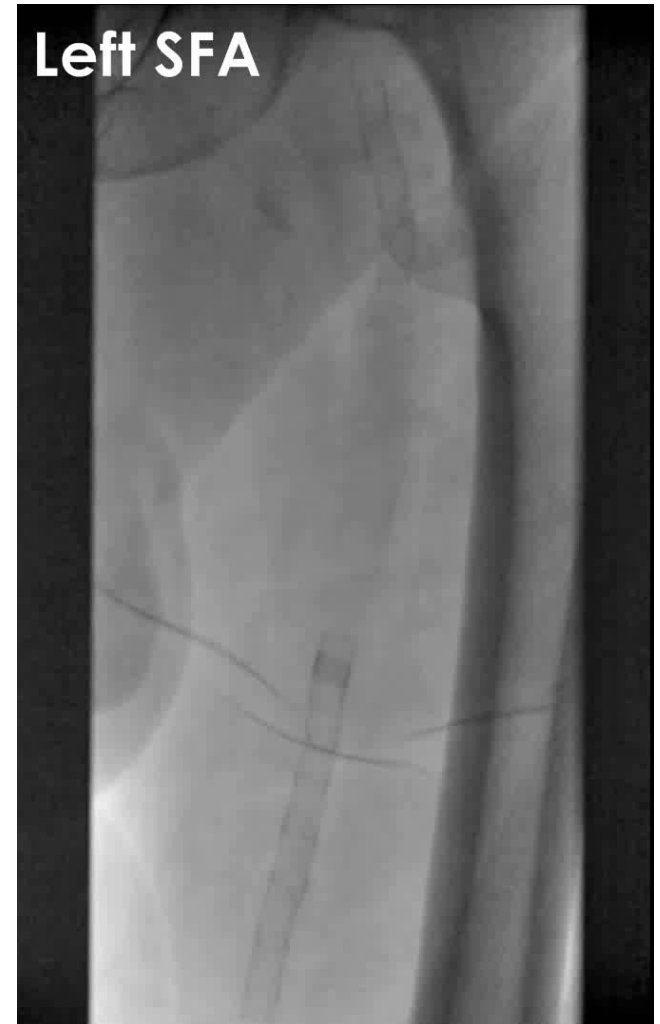A Philips Volcano Eagle Eye Platinum digital IVUS catheter was used in this case.

Treatment

- Spot stenting was performed on the left SFA so that the segments showing dissection were covered, and healthy vessel segments were left alone
- The entire right SFA required stenting due to the extensive wire dissection running through the length of the vessel

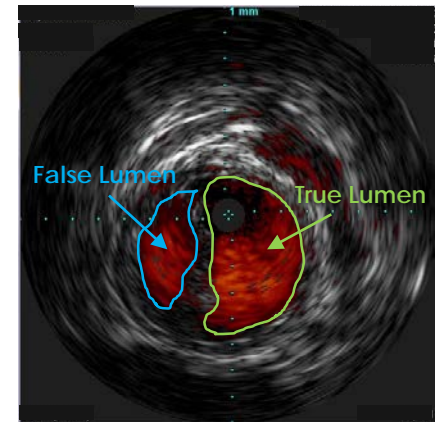
Post-Procedure Result

- Both sides showed a successful angiographic result post-stenting
- Post-intervention ABI values:
 - Left side = 1.26 at rest
 - Right side = 1.20 at rest
- Claudication improved considerably at 30-day follow up



Conclusions

- IVUS can assist in determining vessel diameter and length measurements to help ensure proper device selection and lesion coverage
- IVUS can also be used to help identify vessel segments that may not need to be stented, which is not always obvious with angiography alone
- IVUS can help identify the true lumen versus the false lumen in dissection cases¹
- IVUS may help identify plaque morphology to assist with selection of treatment strategies such as thrombolytic therapy, plaque excision and/or stent to treat the disease by an interventional approach²



1. Ohki, Takao. Pros and Cons of IVUS Imaging for Endovascular Procedures. Endovascular Today 2008; March: 1-3.
2. Arthurs, Zachary M. The evaluation of peripheral arterial disease with intravascular ultrasound. Vascular Disease Management 2011;8:E81-E86.

